



**PATIENT**

Tucker Puchyr

**SPECIES**

Canine

**BREED**

Goldendoodle

**SEX**

Neutered Male

**AGE**

10 Years 7 Months

**WEIGHT**

81.6 lbs

**INTERPRETED BY**

Beth Johnson, DVM  
 DACVIM

**IMAGING PERFORMED BY**

Kathleen Byrnes

**HOSPITAL NAME**

Animal Hospital of  
 Lake Brandt

**REFERRING VET**

Dr. Smith

**INVOICE**

73087

**DATE**

2/19/26

**PRESENTING CLINICAL SIGNS**

P presented for US due to rising Liver values

Abnormal PE/Chem/CBC/UA Results: ALT 167, ALKP 167 T bili 0.4, Chol 351 T4 0.8- Full thyroid panel sent out today

**ULTRASONOGRAPHIC EXAMINATION OF THE ABDOMEN**

**Urinary System**

The urinary bladder is adequately distended with anechoic contents. No masses, inflammatory changes, echogenic sediment or cystoliths are observed. The urinary bladder, trigone and visible pelvic urethra are normal in thickness with a smooth mucosal surface.

Prostate is normal in size, echotexture and echogenicity for a neutered male.

The right kidney is normal is size (6.53 cm), shape and echogenicity. It has smooth peripheral margination. There is a normal 1:3 cortex to medulla ratio with appropriate corticomedullary distinction. There is no evidence of pyelectasia, mineral or infarcts observed.

The left kidney is normal is size (6.87 cm), shape and echogenicity. It has smooth peripheral margination. There is a normal 1:3 cortex to medulla ratio with appropriate corticomedullary distinction. There is no evidence of pyelectasia, mineral or infarcts observed.

**Adrenal Glands**

The right adrenal gland is normal in size (0.96 cm at cranial pole and 0.72 cm at caudal pole), shape and overall architecture, echogenicity and echotexture. Visible surrounding vasculature appears normal.

The left adrenal gland is normal in size (0.77 cm at cranial pole and 0.95 cm at caudal pole), shape and overall architecture, echogenicity and echotexture. Visible surrounding vasculature appears normal.

**Spleen**

The spleen is subjectively normal in size with a normal smooth capsular contour. Parenchyma is appropriately finely textured and homogenous with normal echogenicity relative to surrounding tissue (hyperechoic to liver). No focal nodules or masses are observed. Splenic vasculature appears normal.

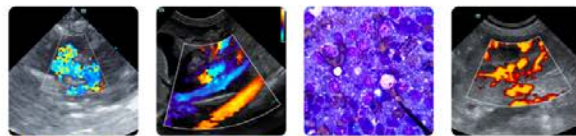
**Liver**

The liver is subjectively normal in size with normal smooth curvilinear peripheral contour. Parenchyma is appropriately hypoechoic to the spleen in echogenicity and appropriately mildly coarse and homogenous in echotexture. No focal lesions are observed. Visible vasculature and biliary tree appear normal without distension or congestion.

The gallbladder is non-distended in size. The wall is smooth without visible thickening. Luminal contents are primarily anechoic. There is no evidence of cystic or common bile duct dilation.

**Gastrointestinal**

The visible stomach wall is normal in thickness and layering. The lumen of the stomach is mildly distended with very echogenic reverberation artifact from intraluminal gas. There is no evidence of obstruction, foreign material, or infiltrative disease; however, visualization is partially inhibited by gas.



**PATIENT**

Tucker Puchyr

The visible small intestines are normal in wall thickness and layering. Small intestinal motility appears adequate (1-3 contractions per min). The lumen of the small intestine is empty with no evidence of obstruction, foreign material or infiltrative disease.

**SPECIES**

Canine

The visible colon is normal in wall thickness (< 0.2 cm) and layering. Contents are consistent with normal formed feces and gas.

***Pancreas***

**BREED**

Goldendoodle

The pancreas that is observed appears appropriately isoechoic to surrounding omental fat. Visible capsule is smooth and normal in contour. Visible pancreatic parenchyma is homogenous and unremarkable. There is no visible pancreatic duct dilation. There is no evidence of active peripancreatic inflammation.

**SEX**

Neutered Male

***Free Abdomen***

**AGE**

10 Years 7 Months

There is no visible free peritoneal effusion noted in these images.

Medial iliac lymph nodes are prominent in size with swollen capsular contour. Normal elongated shape (length to width ratio) is maintained. There is no loss of parenchymal detail.

**WEIGHT**

81.6 lbs

**ULTRASONOGRAPHIC FINDINGS**

- Very mild reactive medial iliac lymph nodes – infiltrative neoplastic disease cannot be ruled out but is considered less likely.
- Otherwise, an obvious cause for the reported increased liver enzymes is not identified in these images. Microscopic disease such as Leptospirosis, bacterial cholangiohepatitis, chronic active hepatitis, copper-associated hepatotoxicity, other hepatotoxicity, other reactive hepatopathy, infiltrative neoplasia, etc. cannot be definitively ruled out.

**INTERPRETED BY**

Beth Johnson, DVM  
 DACVIM

**INTERPRETATION OF THE FINDINGS & FURTHER RECOMMENDATIONS**

**IMAGING PERFORMED BY**

Kathleen Byrnes

Differentials for a primary hepatocellular injury liver enzyme pattern (increased ALT) depend partially on the level of increase. Mild increases (less than 2 times normal) are often a “reactive hepatopathy” or the liver’s response to an insult elsewhere in the body including, but not limited to, pancreatitis, gastroenteritis, parasitic disease, dental disease, vacuolar or endocrine hepatopathy from diabetes mellitus or hyperadrenocorticism (steroid-induced), hypoadrenocorticism, certain drugs (e.g. phenobarbital, corticosteroids, azathioprine, etc.), and muscle ALT (more likely if AST and CK concurrently increased).

**HOSPITAL NAME**

Animal Hospital of  
 Lake Brandt

**REFERRING VET**

Dr. Smith

It is a good indicator of active liver damage (cell membrane disruption, cellular necrosis), however, if the value is increased by at least 3-4 times normal. Differentials include infectious disease, including Leptospirosis, inflammatory disease (ie. active hepatitis, copper, other), toxic insult as well as infiltrative neoplasia.

**INVOICE**

73087

ALT levels vary in cases of vascular anomalies such as microvascular dysplasia and portosystemic shunts (PSS), but are often less significantly increased.

**DATE**

2/19/26

- Testing for Leptospirosis could be considered.
- Bile acids could be considered, if tbili is not increased.



**PATIENT**

Tucker Puchyr

**SPECIES**

Canine

**BREED**

Goldendoodle

**SEX**

Neutered Male

**AGE**

10 Years 7 Months

**WEIGHT**

81.6 lbs

**INTERPRETED BY**

Beth Johnson, DVM  
 DACVIM

**IMAGING PERFORMED BY**

Kathleen Byrnes

**HOSPITAL NAME**

Animal Hospital of  
 Lake Brandt

**REFERRING VET**

Dr. Smith

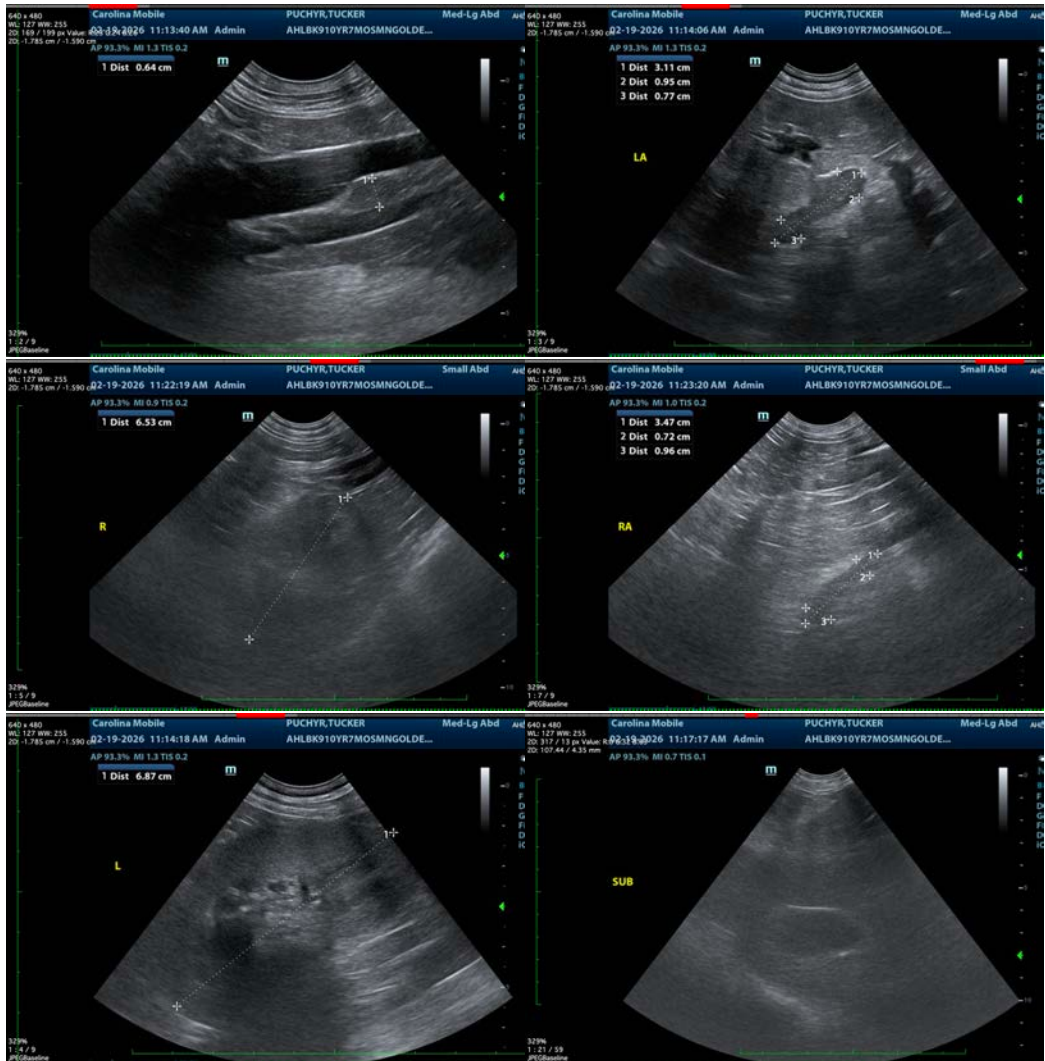
**INVOICE**

73087

**DATE**

2/19/26

- An empirical course of antibiotics and empirical hepatic nutraceuticals may be tried, with monitoring of ALT for improvement. If improvement is noted, antibiotics should be continued until liver enzymes either normalize or plateau (recheck every 2-3 weeks); however, if improvement is not noted and/or enzyme increase progresses, antibiotics should not be continued long term and liver tissue sampling is recommended.
- FNA of the liver can be performed to assess inflammatory cell type, rule in/out round cell neoplasia, etc. (if patient's coagulation status is appropriate).
- If round cell neoplasia is not diagnosed, a liver biopsy (including copper level assessment) may be required to definitively diagnose the underlying hepatopathy.





**PATIENT**

Tucker Puchyr

**SPECIES**

Canine

**BREED**

Goldendoodle

**SEX**

Neutered Male

**AGE**

10 Years 7 Months

**WEIGHT**

81.6 lbs

**INTERPRETED BY**

Beth Johnson, DVM  
DACVIM

**IMAGING  
PERFORMED BY**

Kathleen Byrnes

**HOSPITAL NAME**

Animal Hospital of  
Lake Brandt

**REFERRING VET**

Dr. Smith

**INVOICE**

73087

**DATE**

2/19/26

The information and recommendations provided are based on the images presented by the referring veterinarian/sonographer. No evaluation can be communicated regarding pathology that was not visible in the image/video clips provided.

Thank you for this referral. If the clinical or image interpretation does not parallel your findings or if I can be of any further assistance please contact me.

**Beth Johnson, DVM, DACVIM**  
[info@sonopath.com](mailto:info@sonopath.com)