

**DATE PRESENTING CLINICAL SIGNS**

2/19/26

Patient History: CC: episodes of anorexia and vomiting that last 1-3 days over the past year or so. Owner thinks it may be to daily oral fluoxetine (for IE: urine). PE: no obvious findings

PATIENT

Noodles Stark

Current Medications: Cerenia 16 mg PRN, Mirataz: 1 mg transdermally PRN

Labwork Results: Labwork attached, reported as: CBC: wnl. CHEM: WNL (low blood sugar is due to us not spinning the yellow top - our centrifuge was broken). T4: WNL

Date of Previous IntraPet Ultrasound: No previous.

SPECIES

Feline

Sedation: Not required to complete full diagnostic ultrasound.

Stat Report: Not requested.

Imaging Performed by: Stephanie Warga RDCS, RVT.

BREED

DSH

ULTRASONOGRAPHIC EXAMINATION OF THE ABDOMEN**SEX**

Neutered Male

Urinary System

Urinary bladder is adequately distended. It has a normal uniform wall thickness. Contents include primarily anechoic fluid with a large amount of echogenic non-shadowing debris, most consistent with exfoliated cells, crystals, mucous and/or small blood clots likely combined with incidental suspended lipid. Both sterile inflammation as well as urinary tract infection can present with echogenic debris. No masses or definitive cystoliths are observed. The trigone and visible pelvic urethra are normal in thickness with a smooth mucosal surface.

AGE

8/17/10

WEIGHT

11.25 lbs

The right kidney is normal is size (4.27 cm), shape and echogenicity. It has smooth peripheral margination. There is a normal 1:3 cortex to medulla ratio with appropriate corticomedullary distinction. There is no evidence of pyelectasia, mineral or infarcts observed.

INTERPRETED BYBeth Johnson, DVM
DACVIM

The left kidney is normal is size (4.07 cm), shape and echogenicity. It has smooth peripheral margination. There is a normal 1:3 cortex to medulla ratio with appropriate corticomedullary distinction. There is no evidence of pyelectasia, mineral or infarcts observed.

HOSPITAL NAMEHarborside Mobile
Veterinary Clinic**Adrenal Glands**

The right adrenal gland is normal in size (0.39 cm), shape and overall architecture, echogenicity and echotexture. Visible surrounding vasculature appears normal.

REFERRING VET

Dr. Hawkins

The left adrenal gland is normal in size (0.43 cm), shape and overall architecture, echogenicity and echotexture. Visible surrounding vasculature appears normal.

INVOICE

73114

Spleen

The spleen is subjectively normal in size with a normal smooth capsular contour. Parenchyma is appropriately finely textured and homogenous with normal echogenicity relative to surrounding tissue (hyperechoic to liver). No focal nodules or masses are observed. Splenic vasculature appears normal.

Liver

The liver is subjectively normal in size with normal smooth curvilinear peripheral contour. Parenchyma is appropriately hypoechoic to the spleen in echogenicity and appropriately mildly coarse and homogenous in

echotexture. No focal lesions are observed. Visible vasculature and biliary tree appear normal without distension or congestion.

The gallbladder is non-distended in size. The wall is smooth without visible thickening. Luminal contents are primarily anechoic. There is no evidence of cystic or common bile duct dilation.

Gastrointestinal

The visible stomach wall is normal in thickness and layering. The lumen of the stomach is empty with no evidence of obstruction, foreign material or infiltrative disease. Pyloric outflow tract appears patent.

The visible small intestine demonstrates areas of moderately thick muscularis layer relative to mucosa (disruption of the normal 1:3 muscularis:mucosa ratio). Small intestinal submucosa is slightly irregular, thick and hyperechoic, without evident loss of layering appreciated. The lumen of the small intestine is empty with no evidence of obstruction or foreign material.

The visible colon is normal in wall thickness (< 0.2 cm) and layering. Contents are consistent with normal formed feces and gas.

Pancreas

Pancreas is prominent (enlarged) in size, hypoechoic to surrounding tissue and has a mildly irregular undulating contour. Parenchyma is coarse with mixed echogenic remodeling noted. No pancreatic duct dilation is noted.

Free Abdomen

There is no visible free peritoneal effusion noted in these images.

There is no apparent pathologic lymphadenopathy noted in these images.

ULTRASONOGRAPHIC FINDINGS

- Moderate inflammatory bowel disease (IBD) pattern – Thick muscularis has been reported with infiltrative bowel disease including both benign inflammatory disease as well as infiltrative neoplasia such as lymphoma. No loss of layering or distinct characteristics of malignancy are present. Therefore, differentials cannot be further ranked without tissue sampling.
- Concurrent chronic low-grade smoldering pancreatitis can't be ruled out and should be suspected in the face of appropriate clinical signs.
- Moderate to large amount of echogenic urinary bladder debris.

INTERPRETATION OF THE FINDINGS & FURTHER RECOMMENDATIONS

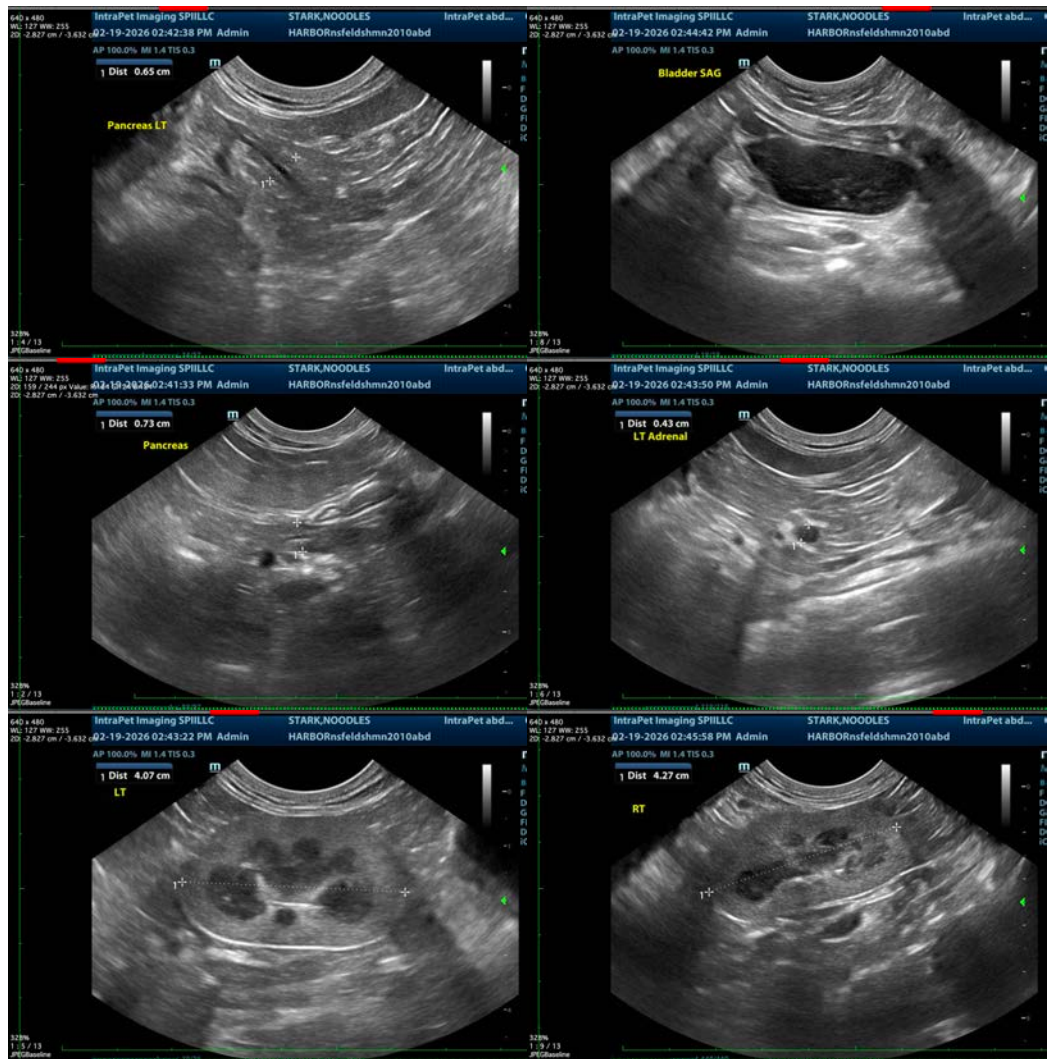
Urinalysis and, if indicated based on urinalysis results, urine culture is recommended. If protein is present in an otherwise quiet sediment, protein quantification with a urine protein to creatinine ratio is recommended.

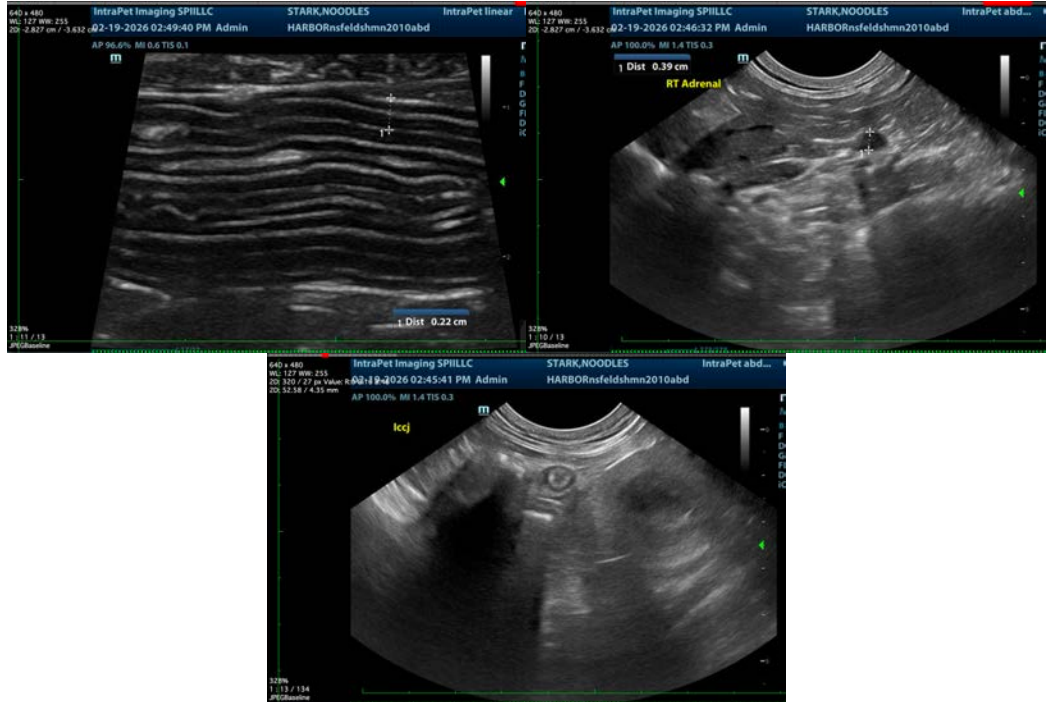
A gastrointestinal malabsorption panel (including cobalamin, folate, TLI and PLI) to Texas A&M GI Laboratory is recommended for further evaluation of GI and pancreatic function.

Ideally, biopsies of the GI tract, being sure to include ileum if possible, are recommended to definitively diagnose and therefore manage the infiltrative bowel disease.

If biopsies cannot be obtained, empirical therapies could include a probiotic (if diarrhea is present, such as visbiome or proviable), empirical deworming with a 5-day course of Panacur and, if tolerated, a transition in diet, based on trial-and-error response, beginning with a hydrolyzed protein diet. Some patients respond to one brand/version of a hydrolyzed protein diet better than another brand, so several trials may be required.

Additional considerations could include cobalamin supplementation (unless cobalamin level is evaluated and supplementation is not warranted) and prednisolone (if not contraindicated based on patient contraindications, co-morbidities, etc.).





The information and recommendations provided are based on the images presented by the referring veterinarian/sonographer. No evaluation can be communicated regarding pathology that was not visible in the image/video clips provided.

Thank you for this referral. If the clinical or image interpretation does not parallel your findings or if I can be of any further assistance please contact me.

Beth Johnson, DVM, DACVIM
info@sonopath.com