



PATIENT

Macy Harris

SPECIES

Canine

BREED

Terrier x

SEX

Spayed Female

AGE

12 Years

WEIGHT

15 lbs

INTERPRETED BY

Beth Johnson, DVM
 DACVIM

IMAGING PERFORMED BY

Kathleen Byrnes

HOSPITAL NAME

Wallburg Animal Hospital

REFERRING VET

Dr. Harris

INVOICE

73094

DATE

2/19/26

PRESENTING CLINICAL SIGNS

P presented for US due to elevation in ALT, ALKP, GGT. LDDST pending.

ULTRASONOGRAPHIC EXAMINATION OF THE ABDOMEN

Urinary System

The urinary bladder is adequately distended with anechoic contents. No masses, inflammatory changes, echogenic sediment or cystoliths are observed. The urinary bladder, trigone and visible pelvic urethra are normal in thickness with a smooth mucosal surface.

Kidneys are overall normal in size and shape with smooth peripheral margination. A normal 1:3 cortex to medulla ratio is maintained. The medulla and cortices are uniform in texture with some mild increased cortical echogenicity and mild loss of corticomedullary distinction, expected in this age patient. There is no evidence of pyelectasia, mineral or infarcts observed. Left kidney measured 4.74 cm. Right kidney measured 5.04 cm.

Adrenal Glands

The adrenal glands are mildly subjectively “plump” for a small dog. Normal shape and contour are maintained without evidence of capsular invasion. Corticomedullary structure is unremarkable. Visible surrounding vasculature appears normal. Left measures 0.76 cm at the cranial pole and 0.76 cm at the caudal pole. Right measures 0.86 cm at the cranial pole and 0.55 cm at the caudal pole.

Spleen

Spleen is subjectively normal in size with a normal smooth capsular contour. Parenchyma is appropriately finely textured and homogenous with normal echogenicity relative to surrounding tissue (hyperechoic to liver). Multifocal well-demarcated hyperechoic homogenous nodules are noted. Splenic vasculature appears normal.

Liver

Liver is subjectively enlarged (swollen contour) without disruption of architecture. It has a normal homogenous echotexture. Parenchyma is diffusely hyperechoic characterized by less prominent than normal portal vein walls and increased echogenicity relative to the spleen and falciform fat. No focal lesions are observed. Visible vasculature and biliary tree appear normal without distension or congestion.

Gallbladder is moderately distended with anechoic bile as well as suspended and gravity dependent echogenic debris. The wall is smooth without visible thickening. There is no evidence of cystic or CBD dilation. There is no evidence of effusion or inflammation.

Gastrointestinal

The visible stomach wall is normal in thickness and layering. The lumen of the stomach is empty with no evidence of obstruction, foreign material or infiltrative disease. Pyloric outflow tract appears patent.

The visible small intestines are normal in wall thickness and layering. Small intestinal motility appears adequate (1-3 contractions per min). The lumen of the small intestine is empty with no evidence of obstruction, foreign material or infiltrative disease.



PATIENT

The visible colon is normal in wall thickness (< 0.2 cm) and layering. Contents are consistent with normal formed feces and gas.

Macy Harris

Pancreas

SPECIES

Pancreas is prominent (enlarged) in size and mildly irregular in shape with a slightly undulating contour. Parenchyma is coarse in echotexture and heterogenous to hypoechoic in echogenicity.

Canine

BREED

Free Abdomen

Terrier x

There is no visible free peritoneal effusion noted in these images.

There is no apparent pathologic lymphadenopathy noted in these images.

SEX

PRIMARY FINDINGS

Spayed Female

- Subjectively mild bilateral adrenomegaly – In a patient diagnosed with hyperadrenocorticism, this finding is most consistent with adrenal hyperplasia secondary to pituitary dependent hyperadrenocorticism. This finding can also be seen with stress and/or normal patient variant. Interpret in combination with clinical signs of hyperadrenocorticism and/or other adrenal disease.

AGE

12 Years

WEIGHT

15 lbs

- Hyperechoic hepatomegaly – This appearance is non-specific and most consistent with a benign steroid (endocrine) or vacuolar hepatopathy or reactive or idiopathic hepatopathy. Inflammatory and/or infiltrative disease (such as round cell neoplasia) are also possible, but considered less likely.
- Moderate gallbladder debris - Cholecystic debris is of unknown clinical significance. It can be seen with biliary stasis from fasting or illness. Cholecystic debris is not necessarily related to hepatobiliary disease. Echogenic bile is most commonly an incidental finding in dogs and should be interpreted in combination with clinical signs such as nausea, inappetence, cranial abdominal discomfort and/or laboratory changes such as increased ALP and/or increased Tbili.
- Chronic low-grade smoldering pancreatitis can't be ruled out and should be suspected in the face of appropriate clinical signs.

INTERPRETED BY

Beth Johnson, DVM
 DACVIM

IMAGING PERFORMED BY

Kathleen Byrnes

HOSPITAL NAME

Wallburg Animal Hospital

REFERRING VET

Dr. Harris

SECONDARY FINDINGS

- Age related kidney changes.
- Hyperechoic splenic nodules – most consistent with benign myelolipomas. Other differentials such as fibrosis or calcification caused by old hematomas or infarcts, chronic inflammation, granulomatous disease or metastatic disease cannot be ruled out, but are considered less likely.

INVOICE

73094

DATE

2/19/26

INTERPRETATION OF THE FINDINGS & FURTHER RECOMMENDATIONS

Specific further recommendations are largely dependent on the degree and exact pattern of liver enzyme increase i.e., primarily hepatocellular injury versus cholestatic, as well as patient's clinical history. If the pattern is primarily ALP increase and patient has clinical signs consistent with hyperadrenocorticism, then testing may be appropriate in the form of a low-dose Dexamethasone suppression test as is reportedly already pending. Additionally, if not recently evaluated, a blood pressure is recommended.



PATIENT

Macy Harris

SPECIES

Canine

BREED

Terrier x

SEX

Spayed Female

AGE

12 Years

WEIGHT

15 lbs

INTERPRETED BY

Beth Johnson, DVM
 DACVIM

IMAGING PERFORMED BY

Kathleen Byrnes

HOSPITAL NAME

Wallburg Animal
 Hospital

REFERRING VET

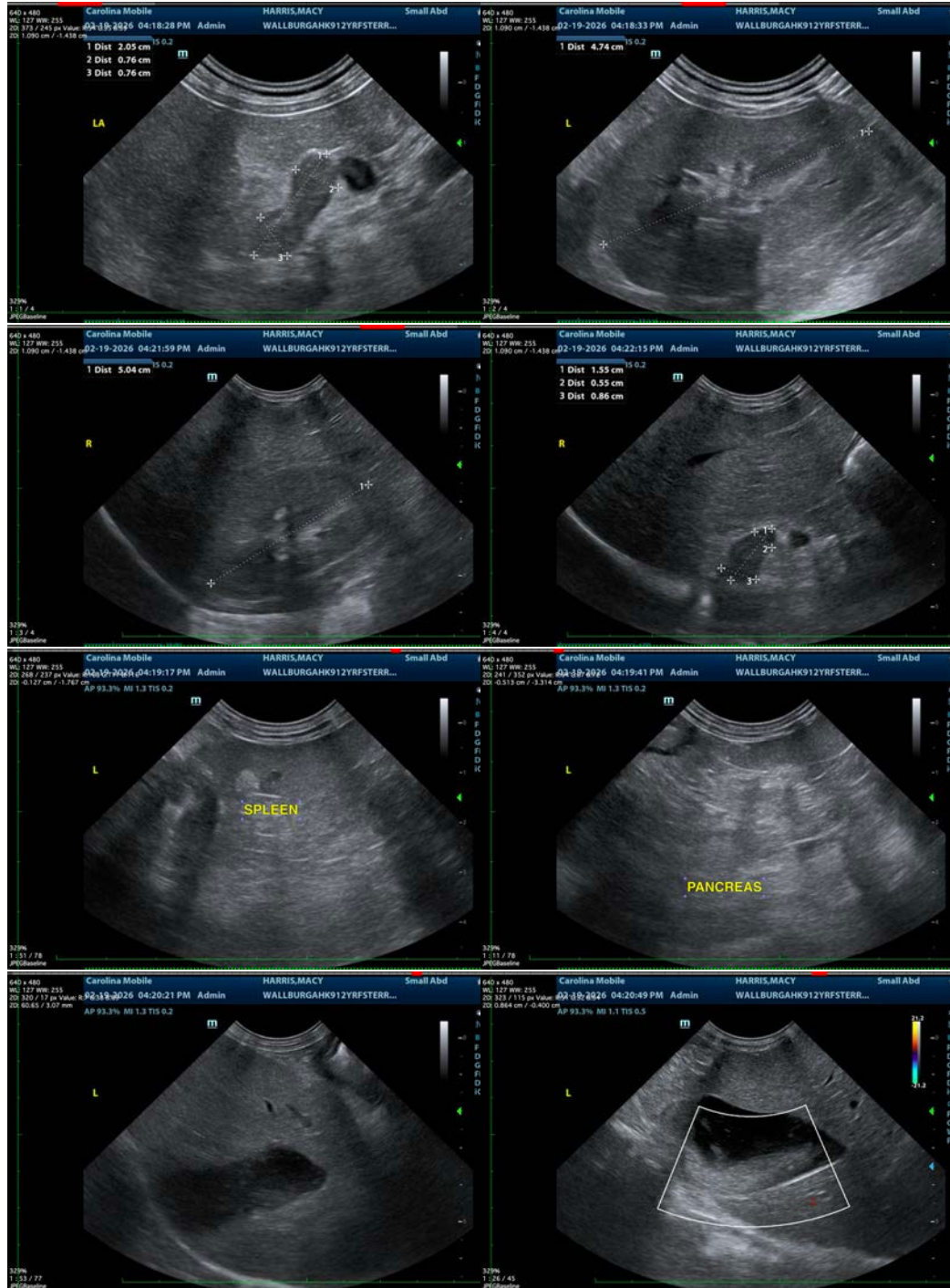
Dr. Harris

INVOICE

73094

DATE

2/19/26





PATIENT

Macy Harris

SPECIES

Canine

BREED

Terrier x

SEX

Spayed Female

AGE

12 Years

WEIGHT

15 lbs

INTERPRETED BY

Beth Johnson, DVM
DACVIM

**IMAGING
PERFORMED BY**

Kathleen Byrnes

HOSPITAL NAME

Wallburg Animal
Hospital

REFERRING VET

Dr. Harris

INVOICE

73094

DATE

2/19/26

The information and recommendations provided are based on the images presented by the referring veterinarian/sonographer. No evaluation can be communicated regarding pathology that was not visible in the image/video clips provided.

Thank you for this referral. If the clinical or image interpretation does not parallel your findings or if I can be of any further assistance please contact me.

Beth Johnson, DVM, DACVIM
info@sonopath.com