



**PATIENT**

Chilli Chrzanowski

**SPECIES**

Canine

**BREED**

Toy Poodle

**SEX**

Spayed Female

**AGE**

7.5 Years

**WEIGHT**

3.34 kg

**INTERPRETED BY**

Beth Johnson, DVM  
 DACVIM

**IMAGING PERFORMED BY**

Crystal Hill

**HOSPITAL NAME**

East Credit Veterinary  
 Hospital

**REFERRING VET**

Dr. Gardiner

**INVOICE**

73098

**DATE**

2/19/26

**PRESENTING CLINICAL SIGNS**

Feb 5, 26 presented for lethargy and decreased appetite. Bloodwork done. New Grade 2-3/6 systolic heart murmur was heard PMI left apex, regular rhythm and pulses strong. History of chronic cough, suspected collapsing trachea. Improved after appt but owner reports symptoms returned, lip smacking and appetite still off. Feeds home cooked meals and owner reports gassiness, stomach noisy. Has been on Metronidazole and Provable and Pepcid.

Abnormal PE/Chem/CBC/UA Results: Please see attached lab results.

**ULTRASONOGRAPHIC EXAMINATION OF THE ABDOMEN**

**Urinary System**

The urinary bladder is adequately distended with anechoic contents. No masses, inflammatory changes, echogenic sediment or cystoliths are observed. The urinary bladder, trigone and visible pelvic urethra are normal in thickness with a smooth mucosal surface.

The right kidney is normal is size (3.64 cm), shape and echogenicity. It has smooth peripheral margination. There is a normal 1:3 cortex to medulla ratio with appropriate corticomedullary distinction. There is no evidence of pyelectasia, mineral or infarcts observed. A hyperechoic band parallel to the corticomedullary border is present.

The left kidney is normal is size (3.28 cm), shape and echogenicity. It has smooth peripheral margination. There is a normal 1:3 cortex to medulla ratio with appropriate corticomedullary distinction. There is no evidence of pyelectasia, mineral or infarcts observed. A hyperechoic band parallel to the corticomedullary border is present.

**Adrenal Glands**

The right adrenal gland is normal in size (1.0 cm at cranial pole and 0.27 cm at caudal pole), shape and overall architecture, echogenicity and echotexture. Visible surrounding vasculature appears normal.

The left adrenal gland is normal in size (0.43 cm at cranial pole and 0.40 cm at caudal pole), shape and overall architecture, echogenicity and echotexture. Visible surrounding vasculature appears normal.

**Spleen**

The spleen is subjectively normal in size with a normal smooth capsular contour. Parenchyma is appropriately finely textured and homogenous with normal echogenicity relative to surrounding tissue (hyperechoic to liver). No focal nodules or masses are observed. Splenic vasculature appears normal.

**Liver**

The liver is subjectively normal in size with normal smooth curvilinear peripheral contour. Parenchyma is appropriately hypoechoic to the spleen in echogenicity and appropriately mildly coarse and homogenous in echotexture. No focal lesions are observed. Visible vasculature and biliary tree appear normal without distension or congestion.

The gallbladder is non-distended in size. The wall is smooth without visible thickening. Luminal contents are primarily anechoic. There is no evidence of cystic or common bile duct dilation.



**PATIENT**

Chilli Chrzanowski

**SPECIES**

Canine

**BREED**

Toy Poodle

**SEX**

Spayed Female

**AGE**

7.5 Years

**WEIGHT**

3.34 kg

**INTERPRETED BY**

Beth Johnson, DVM  
 DACVIM

**IMAGING PERFORMED BY**

Crystal Hill

**HOSPITAL NAME**

East Credit Veterinary  
 Hospital

**REFERRING VET**

Dr. Gardiner

**INVOICE**

73098

**DATE**

2/19/26

**Gastrointestinal**

The visible stomach wall is normal in thickness and layering. The lumen of the stomach is mildly distended with very echogenic reverberation artifact from intraluminal gas. There is no evidence of obstruction, foreign material, or infiltrative disease; however, visualization is partially inhibited by gas.

The visible small intestines are normal in wall thickness and layering. Mild/subtle hyperechoic mucosal fogging or speckling is noted. Small intestinal motility appears adequate (1-3 contractions per min). The lumen of the small intestine is mildly distended with very echogenic reverberation artifact from intraluminal gas. There is no evidence of obstruction, foreign material, or infiltrative disease; however, visualization is partially inhibited by gas.

The visible colon is normal in wall thickness (< 0.2 cm) and layering. Contents are consistent with normal formed feces and gas.

**Pancreas**

The pancreas that is observed appears appropriately isoechoic to surrounding omental fat. Visible capsule is smooth and normal in contour. Visible pancreatic parenchyma is homogenous and unremarkable. There is no visible pancreatic duct dilation. There is no evidence of active peripancreatic inflammation.

**Free Abdomen**

There is no visible free peritoneal effusion noted in these images.

There is no apparent pathologic lymphadenopathy noted in these images.

**ULTRASONOGRAPHIC FINDINGS**

- Mild/subtle mucosal speckling – Mucosal speckling is often present with inflammatory bowel disease (IBD). It is not specific for type or severity of disease. Mild speckling change can occur as a normal patient variant in the post-prandial state.
- Bilateral medullary rim sign - This finding is of unknown clinical significance and can be a normal variant, often idiopathic. Medullary rim sign can be present with renal disease including lymphoma, hypercalcemic nephropathy, Leptospirosis, tubular disease, other and should be interpreted in combination with other more specific indications of kidney disease such as isosthenuria, proteinuria, azotemia, etc. This is a common incidental finding in patients with diabetes mellitus.

**INTERPRETATION OF THE FINDINGS & FURTHER RECOMMENDATIONS**

A gastrointestinal malabsorption panel (including cobalamin, folate, TLI and PLI) to Texas A&M GI Laboratory is recommended for further evaluation of GI and pancreatic function.

A fecal enteropathogen PCR panel to Texas A&M GI Laboratory could be considered for further evaluation of possible infectious disease. Contact lab for recommendations on how long to discontinue antibiotics (if indicated) prior to obtaining a stool sample for submission.

A baseline cortisol is recommended. If baseline cortisol is less than 2, a full ACTH stimulation test is recommended to rule out hypoadrenocorticism.



**PATIENT**

Chilli Chrzanowski

In the meantime, supportive/symptomatic medical management of clinical signs is recommended, including anti-emetics, gastroprotectants (+/- sucralfate, especially with any history of hematemesis), an appetite stimulant and fluid therapy if indicated, etc.

**SPECIES**

Canine

Additionally, empirical deworming with a 5-day course of Panacur is recommended as is a full course of empirical Helicobacter triple therapy.

**BREED**

Toy Poodle

Finally, if tolerated, a transition in diet could be considered, based on trial-and-error response with some options to consider including a gastrointestinal biome diet vs a hydrolyzed protein diet (sometimes several trials with different brands are necessary) vs an easy to digest, bland or low-fat diet vs other.

**SEX**

Spayed Female

**AGE**

7.5 Years

**WEIGHT**

3.34 kg

**INTERPRETED BY**

Beth Johnson, DVM  
 DACVIM

**IMAGING PERFORMED BY**

Crystal Hill

**HOSPITAL NAME**

East Credit Veterinary  
 Hospital

**REFERRING VET**

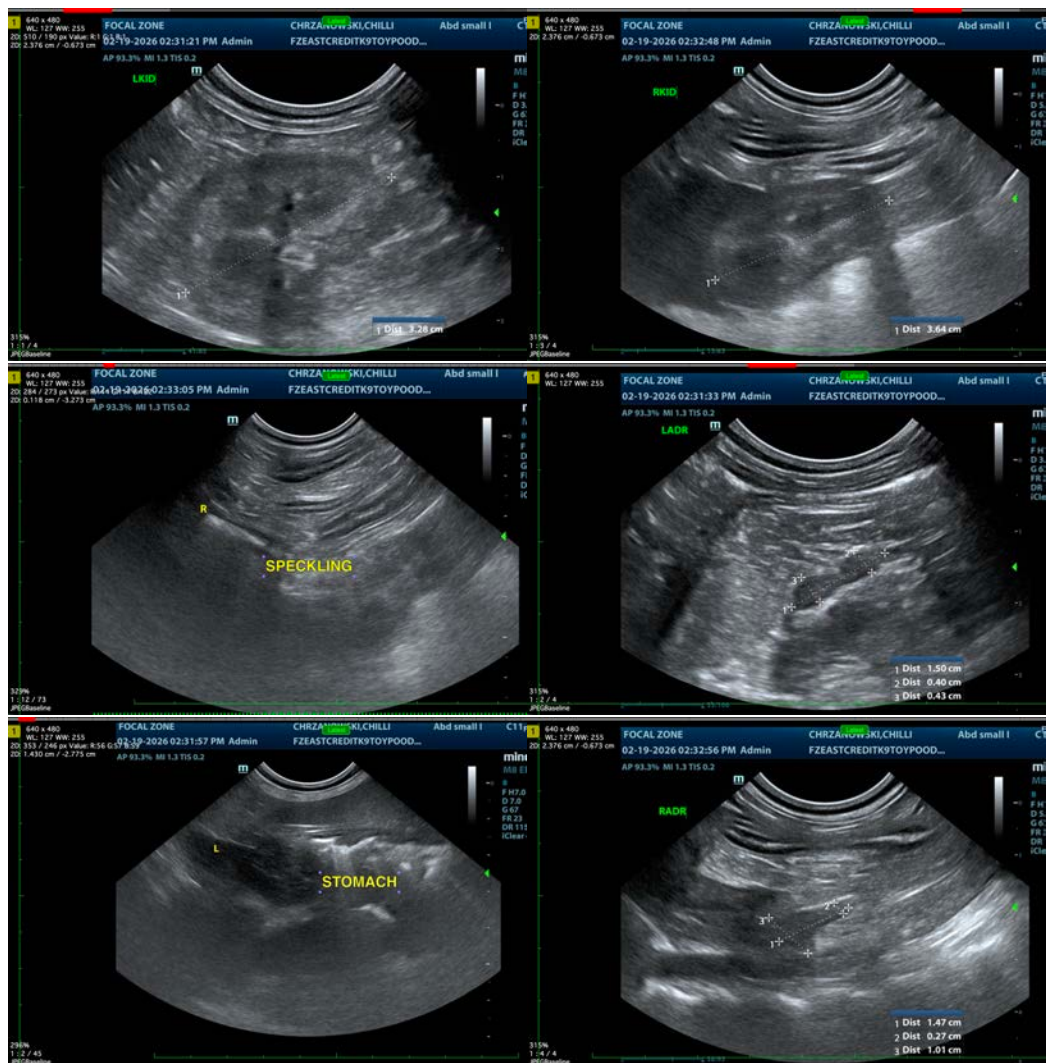
Dr. Gardiner

**INVOICE**

73098

**DATE**

2/19/26





**PATIENT**

Chilli Chrzanowski

**SPECIES**

Canine

**BREED**

Toy Poodle

**SEX**

Spayed Female

**AGE**

7.5 Years

**WEIGHT**

3.34 kg

**INTERPRETED BY**

Beth Johnson, DVM  
DACVIM

**IMAGING  
PERFORMED BY**

Crystal Hill

**HOSPITAL NAME**

East Credit Veterinary  
Hospital

**REFERRING VET**

Dr. Gardiner

**INVOICE**

73098

**DATE**

2/19/26

The information and recommendations provided are based on the images presented by the referring veterinarian/sonographer. No evaluation can be communicated regarding pathology that was not visible in the image/video clips provided.

Thank you for this referral. If the clinical or image interpretation does not parallel your findings or if I can be of any further assistance please contact me.

**Beth Johnson, DVM, DACVIM**  
[info@sonopath.com](mailto:info@sonopath.com)