

**PATIENT**

Charlie Saskowitz

SPECIES

Canine

BREED

Coonhound x

SEX

Spayed Female

AGE

11

WEIGHT

106

INTERPRETED BYBeth Johnson, DVM
DACVIM**IMAGING
PERFORMED BY**

Jenn

HOSPITAL NAMERockaway Animal
Hospital**REFERRING VET**

Dr. Dubos

INVOICE

73072

DATE

2/19/26

PRESENTING CLINICAL SIGNS

Diabetic - recently , well controlled elevated LE'S Current meds Vetsulin 24 u SQ BID

Abnormal PE/Chem/CBC/UA Results: ALT 157 ALP 664 USG 1.014

ULTRASONOGRAPHIC EXAMINATION OF THE ABDOMEN**Urinary System**

The urinary bladder is adequately distended with anechoic contents. No masses, inflammatory changes, echogenic sediment or cystoliths are observed. The urinary bladder, trigone and visible pelvic urethra are normal in thickness with a smooth mucosal surface.

The right kidney is normal is size (6.3 cm), shape and echogenicity. It has smooth peripheral margination. There is a normal 1:3 cortex to medulla ratio with appropriate corticomedullary distinction. There is no evidence of pyelectasia, mineral or infarcts observed. A hyperechoic band parallel to the corticomedullary border is present.

The left kidney is normal is size (6.4 cm), shape and echogenicity. It has smooth peripheral margination. There is a normal 1:3 cortex to medulla ratio with appropriate corticomedullary distinction. There is no evidence of pyelectasia, mineral or infarcts observed. A hyperechoic band parallel to the corticomedullary border is present.

Adrenal Glands

Adrenal glands are small (flattened contour). Corticomedullary structure is unremarkable. Visible surrounding vasculature appears normal. Left measures 0.41 cm at the cranial pole and 0.35 cm.

The right adrenal gland is unable to be well visualized.

Spleen

The spleen is subjectively normal in size with a normal smooth capsular contour. Parenchyma is appropriately finely textured and homogenous with normal echogenicity relative to surrounding tissue (hyperechoic to liver). No focal nodules or masses are observed. Splenic vasculature appears normal.

Liver

The liver is subjectively normal in size with normal smooth curvilinear peripheral contour. Parenchyma is appropriately hypoechoic to the spleen in echogenicity and appropriately mildly coarse and homogenous in echotexture. No focal lesions are observed. Visible vasculature and biliary tree appear normal without distension or congestion.

Gallbladder is moderately distended with anechoic bile as well as suspended and gravity dependent echogenic debris. The wall is smooth without visible thickening. There is no evidence of cystic or CBD dilation. There is no evidence of effusion or inflammation.

Gastrointestinal

The visible stomach wall is normal in thickness and layering. The lumen of the stomach is mildly distended with a small to moderate amount of echogenic non-shadowing luminal contents and gas consistent with normal ingesta. There is no evidence of obstruction, foreign material or infiltrative disease. Pyloric outflow tract appears patent.



PATIENT

Charlie Saskowitz

SPECIES

Canine

BREED

Coonhound x

SEX

Spayed Female

AGE

11

WEIGHT

106

INTERPRETED BY

Beth Johnson, DVM
DACVIM

IMAGING PERFORMED BY

Jenn

HOSPITAL NAME

Rockaway Animal
Hospital

REFERRING VET

Dr. Dubos

INVOICE

73072

DATE

2/19/26

The visible small intestines are normal in wall thickness and layering. Small intestinal motility appears adequate (1-3 contractions per min). The lumen is mildly distended with echogenic non-shadowing luminal contents and gas consistent with normal ingesta/chyme. There is no evidence of obstruction, foreign material or infiltrative disease.

The visible colon is normal in wall thickness (< 0.2 cm) and layering. Contents are consistent with normal formed feces and gas.

Pancreas

The pancreas that is observed appears appropriately isoechoic to surrounding omental fat. Visible capsule is smooth and normal in contour. Visible pancreatic parenchyma is homogenous and unremarkable. There is no visible pancreatic duct dilation. There is no evidence of active peripancreatic inflammation.

Free Abdomen

There is no visible free peritoneal effusion noted in these images.

There is no apparent pathologic lymphadenopathy noted in these images.

ULTRASONOGRAPHIC FINDINGS

- Flat left adrenal gland – This can be a normal patient variant and/or a sign of exogenous cortisol administration. If exogenous steroids are not being administered, hypoadrenocorticism (either relative or absolute) should be considered. The area of the right adrenal gland is examined but it is difficult to fully visualize/isolate for measurement, which could indicate a concurrently flat right adrenal gland.
- Mild gallbladder debris - Cholecystic debris is of unknown clinical significance. It can be seen with biliary stasis from fasting or illness. Cholecystic debris is not necessarily related to hepatobiliary disease. Echogenic bile is most commonly an incidental finding in dogs and should be interpreted in combination with clinical signs such as nausea, inappetence, cranial abdominal discomfort and/or laboratory changes such as increased ALP and/or increased Tbili.
- Bilateral medullary rim sign - This finding is of unknown clinical significance and can be a normal variant, often idiopathic. Medullary rim sign can be present with renal disease including lymphoma, hypercalcemic nephropathy, Leptospirosis, tubular disease, other and should be interpreted in combination with other more specific indications of kidney disease such as isosthenuria, proteinuria, azotemia, etc. This is a common incidental finding in patients with diabetes mellitus.
- Otherwise, an obvious cause for the reported increased liver enzymes is not identified in these images. Microscopic disease such as Leptospirosis, bacterial cholangiohepatitis, chronic active hepatitis, copper-associated hepatotoxicity, other hepatotoxicity, other reactive hepatopathy, infiltrative neoplasia (considered unlikely), etc. cannot be definitively ruled out.

INTERPRETATION OF THE FINDINGS & FURTHER RECOMMENDATIONS

A baseline cortisol is recommended. If baseline cortisol is less than 2, a full ACTH stimulation test is recommended to rule out hypoadrenocorticism.



PATIENT

Charlie Saskowitz

SPECIES

Canine

BREED

Coonhound x

SEX

Spayed Female

AGE

11

WEIGHT

106

INTERPRETED BY

Beth Johnson, DVM
DACVIM

IMAGING PERFORMED BY

Jenn

HOSPITAL NAME

Rockaway Animal Hospital

REFERRING VET

Dr. Dubos

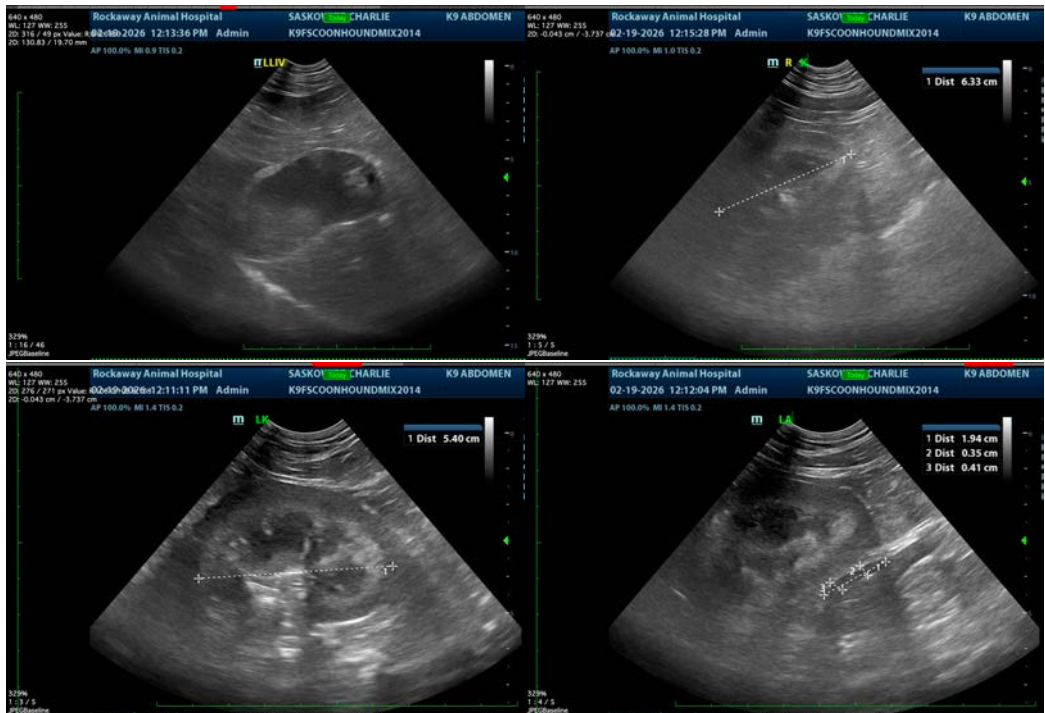
INVOICE

73072

DATE

2/19/26

Otherwise, the changes described historically may all be secondary to patient's reported recently diagnosed diabetes mellitus, and if patient is otherwise well and well regulated, continued monitoring may be appropriate. Having said that, further diagnostics and/or treatment interventions may be indicated if liver enzymes don't improve and/or worsen.



The information and recommendations provided are based on the images presented by the referring veterinarian/sonographer. No evaluation can be communicated regarding pathology that was not visible in the image/video clips provided.

Thank you for this referral. If the clinical or image interpretation does not parallel your findings or if I can be of any further assistance please contact me.

Beth Johnson, DVM, DACVIM
info@sonopath.com