



PATIENT

Pax Bagaason

SPECIES

Canine

BREED

Bull Mastiff

SEX

Female

AGE

16 weeks

WEIGHT

33 lbs

INTERPRETED BY

Beth Johnson, DVM
DACVIM

IMAGING PERFORMED BY

Dr. Julia Bakker

HOSPITAL NAME

Orange Blossom
Veterinary Imaging

REFERRING VET

Dr. Jonathan Shivers

INVOICE

11331

DATE

2/18/2026

PRESENTING CLINICAL SIGNS

- Screening urinary tract for history of incontinence, leaking urine, and UTIs.

ULTRASONOGRAPHIC EXAMINATION OF THE ABDOMEN

Urinary System

The urinary bladder is adequately distended with anechoic contents. No masses, inflammatory changes, echogenic sediment or cystoliths are observed. The urinary bladder, trigone and visible pelvic urethra are normal in thickness with a smooth mucosal surface. Dorsal to the urinary bladder, labeled left side is a tortuous tubular structure without blood flow consistent with a dilated left ureter that appears to enter in the proximal urethra, consistent with an ectopic ureter. The right ureter is less definitively visualized but appears to produce a ureteral jet within the trigone possibly normal position. Although bilateral ectopic ureters can't be ruled out.

The right kidney is normal is size (6.96 cm), shape and echogenicity. It has smooth peripheral margination. There is a normal 1:3 cortex to medulla ratio with appropriate corticomedullary distinction. There is no evidence of pyelectasia, mineral or infarcts observed.

The left kidney is normal is size (6.53 cm), shape and echogenicity. It has smooth peripheral margination. There is a normal 1:3 cortex to medulla ratio with appropriate corticomedullary distinction. There is no evidence of pyelectasia, mineral or infarcts observed.

Adrenal Glands

The right adrenal gland is normal in size (0.67 cm at cranial pole and 0.58 cm at caudal pole), shape and overall architecture, echogenicity and echotexture. Visible surrounding vasculature appears normal.

The left adrenal gland is normal in size (0.3 cm at cranial pole and 0.25 cm at caudal pole), shape and overall architecture, echogenicity and echotexture. Visible surrounding vasculature appears normal.

Spleen

The spleen is subjectively normal in size with a normal smooth capsular contour. Parenchyma is appropriately finely textured and homogenous with normal echogenicity relative to surrounding tissue (hyperechoic to liver). No focal nodules or masses are observed. Splenic vasculature appears normal.

Liver

The liver is subjectively normal in size with normal smooth curvilinear peripheral contour. Parenchyma is appropriately hypoechoic to the spleen in echogenicity and appropriately mildly coarse and homogenous in echotexture. No focal lesions are observed. Visible vasculature and biliary tree appear normal without distension or congestion.

The gallbladder is non-distended in size. The wall is smooth without visible thickening. Luminal contents are primarily anechoic. There is no evidence of cystic or common bile duct dilation.

Gastrointestinal

The visible stomach wall is normal in thickness and layering. The stomach is moderately distended with echogenic non-shadowing luminal contents and gas consistent with normal ingesta. There is no evidence of obstruction, foreign material or infiltrative disease. If patient was appropriately fasted,



PATIENT

Pax Bagaason

SPECIES

Canine

BREED

Bull Mastiff

SEX

Female

AGE

16 weeks

WEIGHT

33 lbs

INTERPRETED BY

Beth Johnson, DVM
DACVIM

IMAGING PERFORMED BY

Dr. Julia Bakker

HOSPITAL NAME

Orange Blossom
Veterinary Imaging

REFERRING VET

Dr. Jonathan Shivers

INVOICE

11331

DATE

2/18/2026

delayed gastric emptying could be considered. Non-shadowing foreign material is considered less likely but cannot be definitively ruled out.

If clinical signs are consistent (vomiting, etc.), recommendations include supportive medical care, 24 hours fasting and re-image.

The visible small intestines are normal in wall thickness and layering. Small intestinal motility appears adequate (1-3 contractions per min). The lumen of the small intestine is mildly distended with echogenic non-shadowing luminal contents and gas consistent with normal ingesta. There is no evidence of obstruction or foreign material noted.

The visible colon is normal in wall thickness (< 0.2 cm) and layering. Contents are consistent with normal formed feces and gas.

Pancreas

The pancreas that is observed appears appropriately isoechoic to surrounding omental fat. Visible capsule is smooth and normal in contour. Visible pancreatic parenchyma is homogenous and unremarkable. There is no visible pancreatic duct dilation. There is no evidence of active peripancreatic inflammation.

Free Abdomen

There is no visible free peritoneal effusion noted in these images.

Medial iliac lymph nodes are prominent in size with swollen capsular contour. Normal elongated shape (length to width ratio) is maintained. There is no loss of parenchymal detail.

ULTRASONOGRAPHIC FINDINGS

- Suspect, at least left if not bilateral, ectopic ureters.
- Mildly reactive medial iliac lymph nodes – infiltrative neoplastic disease cannot be ruled out but is considered less likely. This finding, however, may be in part normal patient variant/juvenile lymphadenopathy given patient's young age.

INTERPRETATION OF THE FINDINGS & FURTHER RECOMMENDATIONS

If not recently evaluated, a general metabolic health screen (CBC, chemistry panel with electrolytes and urinalysis) is recommended.

Full consultation with, and/or transfer to, a veterinary internist is recommended for further investigation and potentially treatment of the ectopic ureters via cystoscopy if possible. If unavailable, or if not possible due to the type of ectopic ureters, ultimately, surgical intervention may be indicated.



PATIENT

Pax Bagaason

SPECIES

Canine

BREED

Bull Mastiff

SEX

Female

AGE

16 weeks

WEIGHT

33 lbs

INTERPRETED BY

Beth Johnson, DVM
DACVIM

IMAGING PERFORMED BY

Dr. Julia Bakker

HOSPITAL NAME

Orange Blossom
Veterinary Imaging

REFERRING VET

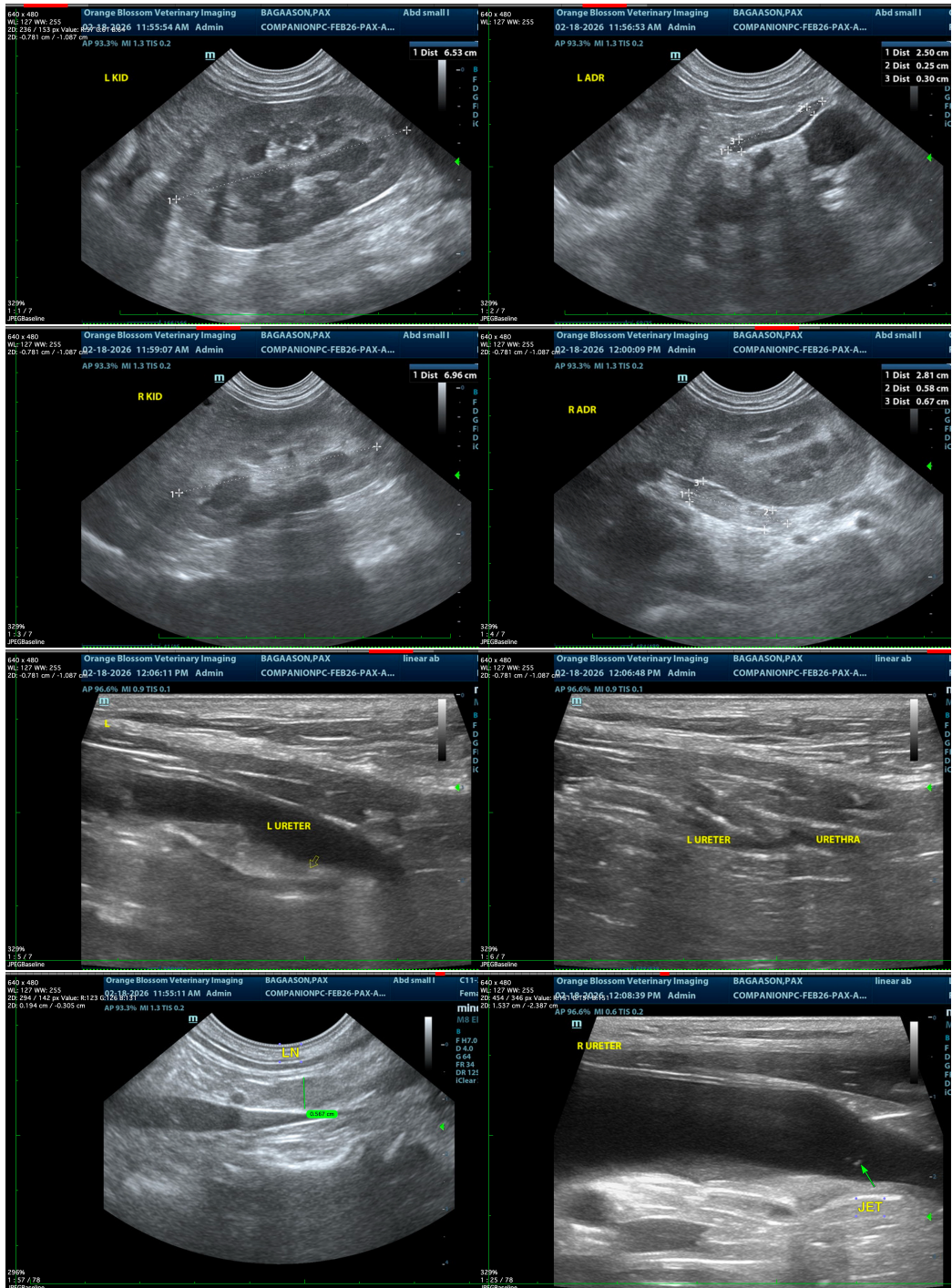
Dr. Jonathan Shivers

INVOICE

11331

DATE

2/18/2026



The information and recommendations provided are based on the images presented by the referring veterinarian/sonographer. No evaluation can be communicated regarding pathology that was not visible in the image/video clips provided.

Thank you for this referral. If the clinical or image interpretation does not parallel your findings or if I



PATIENT

can be of any further assistance please contact me.

Pax Bagaason

Beth Johnson, DVM, DACVIM

info@sonopath.com

SPECIES

Canine

BREED

Bull Mastiff

SEX

Female

AGE

16 weeks

WEIGHT

33 lbs

INTERPRETED BY

Beth Johnson, DVM

DACVIM

IMAGING PERFORMED BY

Dr. Julia Bakker

HOSPITAL NAME

Orange Blossom
Veterinary Imaging

REFERRING VET

Dr. Jonathan Shivers

INVOICE

11331

DATE

2/18/2026