

SonoPath
www.carolinavetmobile.com
info@carolinavetmobile.com
800.808.5948

PATIENT

Parker Germini

SPECIES

Canine

BREED

Golden Retriever

SEX

Spayed Female

AGE

6 Years 9 Months

WEIGHT

75.8 lbs

INTERPRETED BY

Beth Johnson, DVM DACVIM

IMAGING PERFORMED BY

Kathleen Byrnes

HOSPITAL NAME

Pet Care Clinic of the High Country

REFERRING VET

Dr. Sturgill

INVOICE

73042

DATE

2/18/26

PRESENTING CLINICAL SIGNS

P presented for an acute swelling over left shoulder. rDVM drained 50 ml non clorrinf blood consistent with hematoma. P started on Prednisone Doxycycline and Yunnan Baiyao. Appears BAR.

Abnormal PE/Chem/CBC/UA Results: Thrombocytopenia 84, Smear 63 HCT 51.7. 4dx neg

ULTRASONOGRAPHIC EXAMINATION OF THE ABDOMEN

Urinary System

The urinary bladder is adequately distended with anechoic contents. No masses, inflammatory changes, echogenic sediment or cystoliths are observed. The urinary bladder, trigone and visible pelvic urethra are normal in thickness with a smooth mucosal surface.

The right kidney is normal is size (6.88 cm), shape and echogenicity. It has smooth peripheral margination. There is a normal 1:3 cortex to medulla ratio with appropriate corticomedullary distinction. There is no evidence of pyelectasia, mineral or infarcts observed.

The left kidney is normal is size (6.33 cm), shape and echogenicity. It has smooth peripheral margination. There is a normal 1:3 cortex to medulla ratio with appropriate corticomedullary distinction. There is no evidence of pyelectasia, mineral or infarcts observed.

Adrenal Glands

The right adrenal gland is normal in size (1.2 cm at cranial pole and 0.77 cm at caudal pole), shape and overall architecture, echogenicity and echotexture. Visible surrounding vasculature appears normal.

The left adrenal gland is normal in size (0.37 cm at cranial pole and 0.51 cm at caudal pole), shape and overall architecture, echogenicity and echotexture. Visible surrounding vasculature appears normal.

Spleen

The spleen is subjectively normal in size with a normal smooth capsular contour. Parenchyma is appropriately finely textured and homogenous with normal echogenicity relative to surrounding tissue (hyperechoic to liver). No focal nodules or masses are observed. Splenic vasculature appears normal.

Liver

The liver is subjectively normal in size with normal smooth curvilinear peripheral contour. Parenchyma is appropriately hypoechoic to the spleen in echogenicity and appropriately mildly coarse and homogenous in echotexture. No focal lesions are observed. Visible vasculature and biliary tree appear normal without distension or congestion.

The gallbladder is non-distended in size. The wall is smooth without visible thickening. Luminal contents are primarily anechoic. There is no evidence of cystic or common bile duct dilation.

Gastrointestinal

The visible stomach wall is normal in thickness and layering. The stomach is moderately distended with echogenic non-shadowing luminal contents and gas consistent with normal ingesta. There is no evidence of obstruction, foreign material or infiltrative disease. If patient was appropriately fasted, delayed gastric emptying could be considered. Non-shadowing foreign material is considered less likely but cannot be definitively ruled out.

PATIENT
Parker Germini

SPECIES
Canine

BREED
Golden Retriever

SEX
Spayed Female

AGE
6 Years 9 Months

WEIGHT
75.8 lbs

INTERPRETED BY
Beth Johnson, DVM DACVIM

IMAGING PERFORMED BY
Kathleen Byrnes

HOSPITAL NAME
Pet Care Clinic of the High Country

REFERRING VET
Dr. Sturgill

INVOICE
73042

DATE
2/18/26

If clinical signs are consistent (vomiting, etc.), recommendations include supportive medical care, 24 hours fasting and re-image.

The visible small intestines are normal in wall thickness and layering. Small intestinal motility appears adequate (1-3 contractions per min). The lumen is mildly distended with echogenic non-shadowing luminal contents and gas consistent with normal ingesta/chyme. There is no evidence of obstruction, foreign material or infiltrative disease.

The visible colon is normal in wall thickness (< 0.2 cm) and layering. Contents are consistent with normal formed feces and gas.

Pancreas

The pancreas that is observed appears appropriately isoechoic to surrounding omental fat. Visible capsule is smooth and normal in contour. Visible pancreatic parenchyma is homogenous and unremarkable. There is no visible pancreatic duct dilation. There is no evidence of active peripancreatic inflammation.

Free Abdomen

There is no visible free peritoneal effusion noted in these images.

There is no apparent pathologic lymphadenopathy noted in these images.

ULTRASONOGRAPHIC FINDINGS

- This is a largely unremarkable/normal structural abdomen without a definitive ultrasonographically visible intraabdominal explanation for patient's reported thrombocytopenia or subcutaneous swelling.

INTERPRETATION OF THE FINDINGS & FURTHER RECOMMENDATIONS

Further recommendations regarding the thrombocytopenia are dependent on whether full clinical assessment of the patient leans towards the thrombocytopenia being the cause of the subcutaneous hemorrhage or hematoma versus the result of bleeding into that area. If the thrombocytopenia is believed to be the primary problem, then further diagnostic recommendations include:

- Comprehensive infectious disease evaluation.
- Further evaluation of possible infiltrative neoplasia outside the abdomen beginning with three view thoracic radiographs for further assessment of cardio-pulmonary status as well as to further evaluate for any evidence of metastatic disease, if not recently evaluated.
- And/or potentially ultimately bone marrow sampling.

If, however, the thrombocytopenia is believed to be secondary to hemorrhage, further diagnostics of the swollen shoulder could include submission of the sampled material for analysis and cytology and/or potentially advanced imaging such as a contrast CT scan versus other.

Other than supportive/symptomatic medical management of clinical signs, further treatment recommendations are largely dependent on results of the above.

Carolina Veterinary Mobile
FUELED BY SONOPATH VETERINARY ULTRASOUND

SonoPath
www.carolinavetmobile.com
info@carolinavetmobile.com
800.808.5948



Clinical Sonography & Telecytology
Educational Teleconsultation Services™

PATIENT

Parker Germini

SPECIES

Canine

BREED

Golden Retriever

SEX

Spayed Female

AGE

6 Years 9 Months

WEIGHT

75.8 lbs

INTERPRETED BY

Beth Johnson, DVM DACVIM

IMAGING PERFORMED BY

Kathleen Byrnes

HOSPITAL NAME

Pet Care Clinic of the High Country

REFERRING VET

Dr. Sturgill

INVOICE

73042

DATE

2/18/26

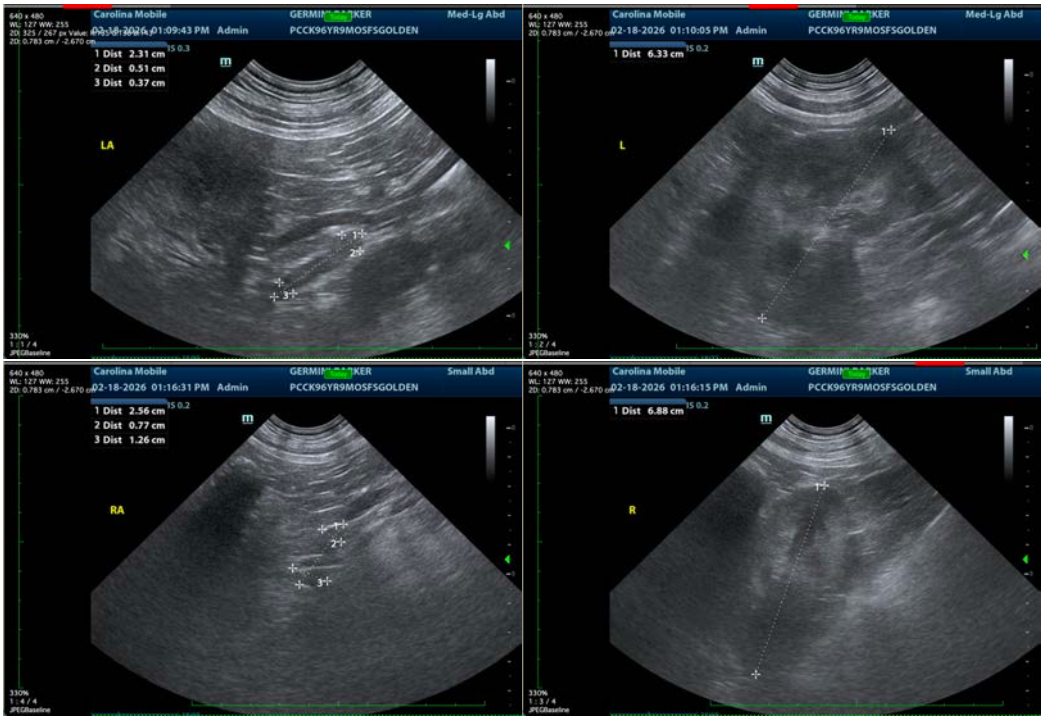

The information and recommendations provided are based on the images presented by the referring veterinarian/sonographer. No evaluation can be communicated regarding pathology that was not visible in the image/video clips provided.

Thank you for this referral. If the clinical or image interpretation does not parallel your findings or if I can be of any further assistance please contact me.

Beth Johnson, DVM, DACVIM
info@sonopath.com