



PATIENT

Lilly Castro-Herrera

SPECIES

Feline

BREED

DSH

SEX

FS

AGE

19 years

WEIGHT

5.2 lbs

INTERPRETED BY

Beth Johnson, DVM
DACVIM

IMAGING PERFORMED BY

Dr. Julia Bakker

HOSPITAL NAME

Orange Blossom
Veterinary Imaging

REFERRING VET

Dr. John Lanier

INVOICE

11332

DATE

2/18/2026

PRESENTING CLINICAL SIGNS

- Senior screening, concern for evidence of GI neoplasia.

ULTRASONOGRAPHIC EXAMINATION OF THE ABDOMEN

Urinary System

The urinary bladder is adequately distended with anechoic contents. No masses, inflammatory changes, echogenic sediment or cystoliths are observed. The urinary bladder, trigone and visible pelvic urethra are normal in thickness with a smooth mucosal surface.

Kidneys are bilaterally small in size, irregular and diffusely echogenic with decreased corticomedullary distinction and poor visualization of internal architecture. There is no pyelectasia noted and no mineral is observed. Left kidney measures 2.63 cm, and the right kidney measures 2.75 cm.

Adrenal Glands

The right adrenal gland is normal in size (0.45 cm at cranial pole and 0.33 cm at caudal pole), shape and overall architecture, echogenicity and echotexture. Visible surrounding vasculature appears normal.

The left adrenal gland is normal in size (0.23 cm at cranial pole and 0.29 cm at caudal pole), shape and overall architecture, echogenicity and echotexture. Visible surrounding vasculature appears normal.

Spleen

The spleen is subjectively normal in size with a normal smooth capsular contour. Parenchyma is appropriately finely textured and homogenous with normal echogenicity relative to surrounding tissue (hyperechoic to liver). No focal nodules or masses are observed. Splenic vasculature appears normal.

Liver

Liver is subjectively enlarged (swollen contour) without disruption of architecture. It has a normal homogenous echotexture. Parenchyma is diffusely hyperechoic characterized by less prominent than normal portal vein walls and increased echogenicity relative to the spleen and falciform fat. No focal lesions are observed. Visible vasculature and biliary tree appear normal without distension or congestion.

The gallbladder is non-distended in size. The wall is smooth without visible thickening. Luminal contents are primarily anechoic. The cystic and common bile duct are diffusely tortuous in appearance without visible pathologic distension noted in these images at this time. This is often a normal patient variant in senior cats, although it should be interpreted in combination with any clinical signs and/or laboratory changes that indicate chronic low grade smoldering cholangitis.

Gastrointestinal

The visible stomach wall is normal in thickness and layering. The lumen of the stomach is empty with no evidence of obstruction, foreign material or infiltrative disease. Pyloric outflow tract appears patent.

The visible small intestine demonstrates areas of moderately thick muscularis layer relative to mucosa (disruption of the normal 1:3 muscularis:mucosa ratio). Small intestinal submucosa is slightly irregular, thick and hyperechoic, without evident loss of layering appreciated. The lumen of the small intestine is



PATIENT

Lilly Castro-Herrera

SPECIES

Feline

BREED

DSH

SEX

FS

AGE

19 years

WEIGHT

5.2 lbs

INTERPRETED BY

Beth Johnson, DVM
DACVIM

IMAGING PERFORMED BY

Dr. Julia Bakker

HOSPITAL NAME

Orange Blossom
Veterinary Imaging

REFERRING VET

Dr. John Lanier

INVOICE

11332

DATE

2/18/2026

mildly distended with echogenic non-shadowing luminal contents and gas consistent with normal ingesta. There is no evidence of obstruction or foreign material noted.

The visible colon is normal in wall thickness (< 0.2 cm) and layering. Contents are consistent with normal formed feces and gas.

Pancreas

Pancreas is prominent (enlarged) in size, hypoechoic to surrounding tissue and has a mildly irregular undulating contour. Parenchyma is coarse with mixed echogenic remodeling noted. Mild duct dilation is noted measuring 0.32 cm.

Free Abdomen

There is a very scant/trace amount of free fluid noted in these images.

There is no apparent pathologic lymphadenopathy noted in these images.

ULTRASONOGRAPHIC FINDINGS

- Moderate inflammatory bowel disease (IBD) pattern – Thick muscularis has been reported with infiltrative bowel disease including both benign inflammatory disease as well as infiltrative neoplasia such as lymphoma. No loss of layering or distinct characteristics of malignancy are present. Therefore, differentials cannot be further ranked without tissue sampling.
- Concurrent chronic low grade smoldering pancreatitis is suspected.
- Hyperechoic hepatomegaly – This appearance is most consistent with benign hepatic lipidosis or endocrine/DM hepatopathy. Infiltrative disease such as amyloidosis or round cell neoplasia, such as mast cell tumor or less likely, lymphoma, is also possible.
- Trace Free fluid is of unknown origin. Differentials (unless already ruled out) could include increased hydrostatic pressure (cardiac disease and/or vascular or lymph blockage), decreased oncotic pressure (low albumin), vasculitis, paraneoplastic fluid, rupture/leakage of/from an organ (GI, GB, UB, other), blood (hemoabdomen), other.
- Moderate bilateral chronic kidney disease changes.

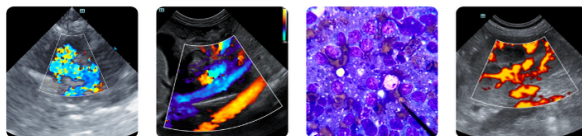
INTERPRETATION OF THE FINDINGS & FURTHER RECOMMENDATIONS

Recommendations depend in part on patient's clinical history, lab work changes, etc. Having said that, based on ultrasound findings alone, if not recently evaluated, a general metabolic health screen (CBC, chemistry panel with electrolytes and urinalysis) is recommended.

Fine needle aspirates of the liver could be considered if patient's coagulation status is appropriate.

A gastrointestinal malabsorption panel (including cobalamin, folate, TLI and PLI) to Texas A&M GI Laboratory is recommended for further evaluation of GI and pancreatic function.

Ideally, biopsies of the GI tract, being sure to include ileum if possible, are recommended to definitively diagnose and therefore manage the infiltrative bowel disease.



PATIENT

Lilly Castro-Herrera

SPECIES

Feline

BREED

DSH

SEX

FS

AGE

19 years

WEIGHT

5.2 lbs

INTERPRETED BY

Beth Johnson, DVM
DACVIM

IMAGING PERFORMED BY

Dr. Julia Bakker

HOSPITAL NAME

Orange Blossom
Veterinary Imaging

REFERRING VET

Dr. John Lanier

INVOICE

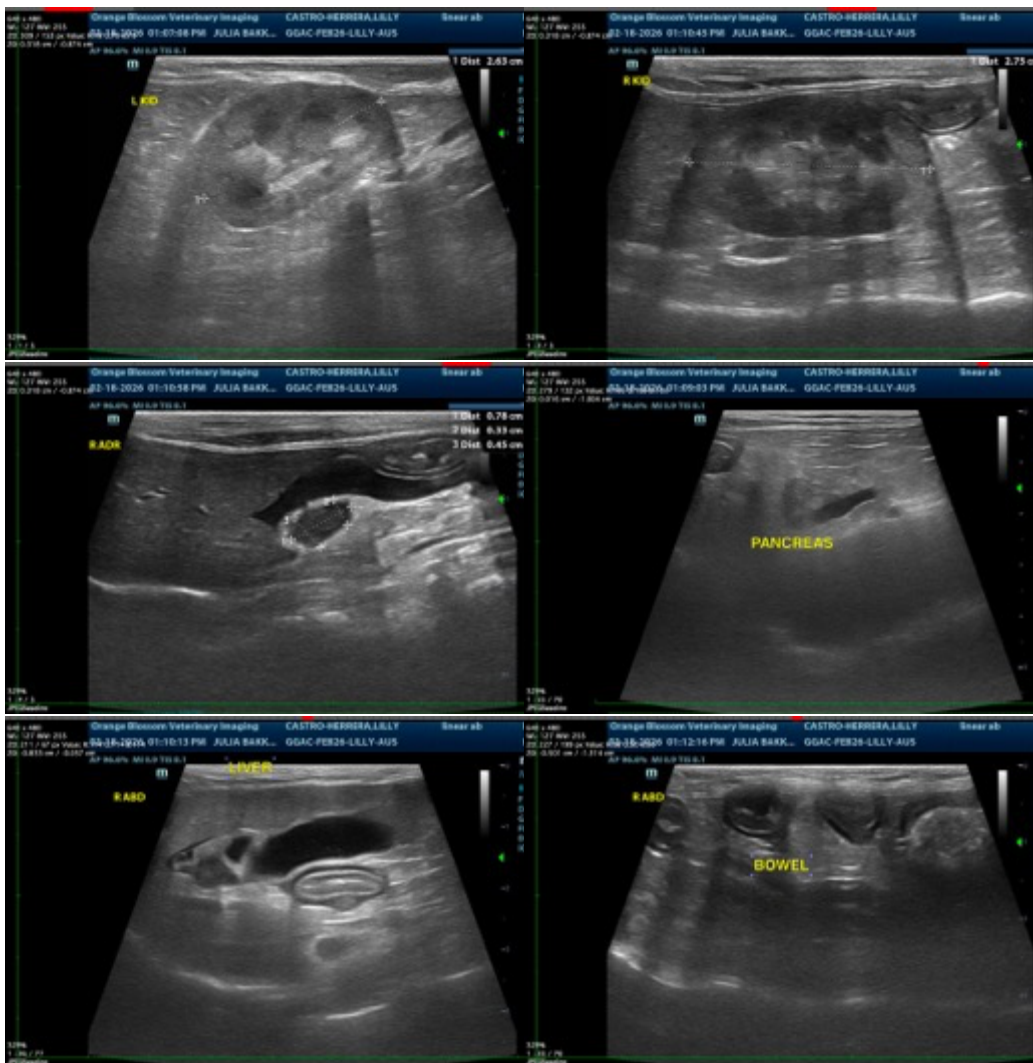11332

DATE

2/18/2026

If biopsies cannot be obtained, empirical therapies could include a probiotic (if diarrhea is present, such as visbiome or proviable), empirical deworming with a 5-day course of Panacur and, if tolerated, a transition in diet, based on trial-and-error response, beginning with a hydrolyzed protein diet. Some patients respond to one brand/version of a hydrolyzed protein diet better than another brand, so several trials may be required.

Additional considerations could include cobalamin supplementation (unless cobalamin level is evaluated and supplementation is not warranted) and prednisolone (if not contraindicated based on patient contraindications, co-morbidities, etc.).





PATIENT

Lilly Castro-Herrera

SPECIES

Feline

BREED

DSH

SEX

FS

AGE

19 years

WEIGHT

5.2 lbs

INTERPRETED BY

Beth Johnson, DVM
DACVIM

IMAGING PERFORMED BY

Dr. Julia Bakker

HOSPITAL NAME

Orange Blossom
Veterinary Imaging

REFERRING VET

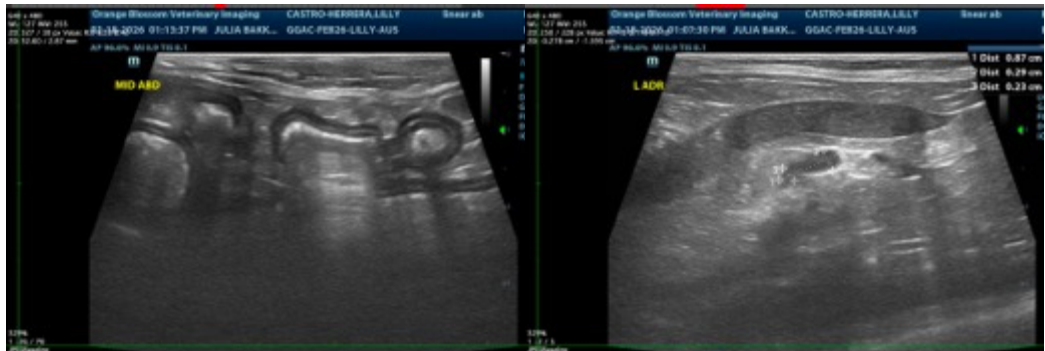Dr. John Lanier

INVOICE

11332

DATE

2/18/2026



The information and recommendations provided are based on the images presented by the referring veterinarian/sonographer. No evaluation can be communicated regarding pathology that was not visible in the image/video clips provided.

Thank you for this referral. If the clinical or image interpretation does not parallel your findings or if I can be of any further assistance please contact me.

Beth Johnson, DVM, DACVIM
info@sonopath.com