

**DATE PRESENTING CLINICAL SIGNS**

2/17/22

History: HISTORY: Harley has a swollen paw pad on his left hind paw. Owner is unsure of how this occurred. She first noticed it about 1 ½ week ago. She attempted to bathe in warm water, use epsom salt, and oatmeal but to no avail. No lameness noted on the swollen Padonia Veterinary Hospital, eating and drinking normally, energy level is normal, no sneezing, coughing, vomiting or diarrhea, no known reactions to any meds or vaccines. Mrs rub coconut oil on his feet and has never noticed this mass before, she thinks it may have grown quickly. Proheart and Bravecto. PE: OS upper eye lid margin by the medial canthus there is an approximately 2 mm mass, heart auscults with a normal rhythm and no murmurs, lungs auscult with normal bronchovesicular sounds, BCS 3/5, pink mm, CRT<2 seconds, moderate dental tartar, left rear digit 1 there is a 2 by 2 cm firm skin mass attached to the carpal pad laterally, encompassing part of digit 1

PATIENT

Harley Grimm

SPECIES

Canine

BREED

Pomeranian

SEX

Neutered Male

AGE

1/1/11

WEIGHT

25 Pounds

INTERPRETED BYBeth Johnson, DVM
DACVIM**IMAGING PERFORMED BY**

Rachel Brilhart RDMS

HOSPITAL NAME

Fullerton AH

REFERRING VET

Dr. Baker

INVOICE

35727

Current Medications: Cefpodoxime 100 mg #14 1 PO QD.

Radiographs: 3 view whole body rads: VHS 10.5, bronchial pattern, cranial mediastinum mildly thick, mass effect in the cranial abdomen, long grey scale due to a large amount of intra-abdominal fat, radiolucency on the right lateral over the caudal lumbar spine (artifact vs other-no repeatable on other radiograph views). Lateral and CC Pes: left rear digit 1 is disarticulated and displaced laterally, there is a large soft tissue mass present, no obvious boney involvement, Date of Previous IntraPet Ultrasound: No previous IntraPet scans. Sedation: Not required to complete full diagnostic ultrasound. Stat Report: Not requested.

ULTRASONOGRAPHIC EXAMINATION OF THE ABDOMEN**Urinary System**

The urinary bladder is moderately distended with anechoic contents. No masses, inflammatory changes, echogenic sediment or cystoliths are observed. The urinary bladder, trigone and visible pelvic urethra are normal in thickness with a smooth mucosal surface.

Prostate (neutered) is normal in size, echotexture and echogenicity for a neutered male.

The right kidney is normal in size (6.02 cm) and shape with smooth peripheral margination. A normal 1:3 cortex to medulla ratio is maintained. The medulla and cortices are uniform in texture with some mild increased echogenicity and mild loss of corticomedullary distinction. There is no evidence of pyelectasia, mineral or infarcts observed.

The left kidney is normal in size (5.74 cm) and shape with smooth peripheral margination. A normal 1:3 cortex to medulla ratio is maintained. The medulla and cortices are uniform in texture with some mild increased echogenicity and mild loss of corticomedullary distinction. There is no evidence of pyelectasia, mineral or infarcts observed.

Adrenal Glands

The right adrenal gland is normal in size (2.5 cm long x 0.77 cm at the cranial pole and 0.80 cm at the caudal pole), shape and contour. Corticomedullary structure is unremarkable. Visible surrounding vasculature appears normal.

The left adrenal gland is normal in size (2.6 cm long x 0.69 cm at the cranial pole and 0.92 cm at the caudal pole), shape and contour. Corticomedullary structure is unremarkable. Visible surrounding vasculature appears normal.

Spleen

The spleen is subjectively normal in size with a normal smooth capsular contour. Parenchyma is appropriately finely textured and homogenous with normal echogenicity relative to surrounding tissue (hyperechoic to liver). The tail of the spleen is rounded, and appears to have a homogeneous, isoechoic 2.0 cm mass off of the tail of the spleen. Splenic vasculature appears normal.

Liver

Liver is subjectively enlarged. Margins are smooth but round. It has a normal homogenous echotexture. Parenchyma is diffusely hyperechoic characterized by less prominent than normal portal vein walls and increased echogenicity relative to the spleen. A 4.5 cm round, homogeneous, iso- to hypoechoic mass is noted in the deep right liver. Visible vasculature and biliary tree appear normal without distension or congestion.

GB contains a moderate amount of non-dependent, mildly aggregated/inspissated sludge. Hypo to anechoic cystic areas are noted between the gallbladder sludge and luminal wall. The wall is otherwise smooth without visible thickening. There is no evidence of cystic or CBD dilation. There is no evidence of effusion.

Gastrointestinal

The stomach wall is normal in thickness (canine < 0.5 cm and feline < 0.4 cm) and layering. The lumen of the stomach is empty with no evidence of obstruction, foreign material or infiltrative disease. Pyloric outflow tract appears patent.

The visible small intestines are normal in wall thickness and layering (canine duodenum < 0.5 cm and feline duodenum < 0.4 cm; other < 0.3 cm). Small intestinal motility appears adequate (1-3 contractions per min). The lumen of the small intestine is empty with no evidence of obstruction, foreign material or infiltrative disease.

The visible colon is normal in wall thickness (< 0.2 cm) and layering. Contents are consistent with normal formed feces and gas.

Pancreas

The pancreas is markedly enlarged in size with a heterogeneous parenchyma made up of well-defined hypo- to isoechoic nodules throughout the parenchyma. The shape of the pancreas is irregular as a result of the nodules. Mild pancreatic duct dilation is noted, measuring 0.28 cm. There is no evidence of active peripancreatic inflammation.

Free Abdomen

There is no evidence of peritoneal effusion. There is no apparent lymphadenopathy.

There is no pericardial effusion noted in these images.

PRIMARY FINDINGS

- Large, nodular, irregular shaped pancreas – Primary differential is nodular hyperplasia. However, infiltrative neoplasia can have a similar appearance and can't be ruled out by ultrasound alone.
- Hyperechoic hepatomegaly – most consistent with benign steroid (endocrine) hepatopathy or reactive or idiopathic hepatopathy. Infiltrative neoplasia such as round cell neoplasia is also possible, but considered less likely.
- Discrete homogeneous mass in the right liver – Differentials include both benign nodular hyperplasia as well as primary hepatic neoplasia or round cell neoplasia with neoplasia considered higher on the list due to the multifocal changes.

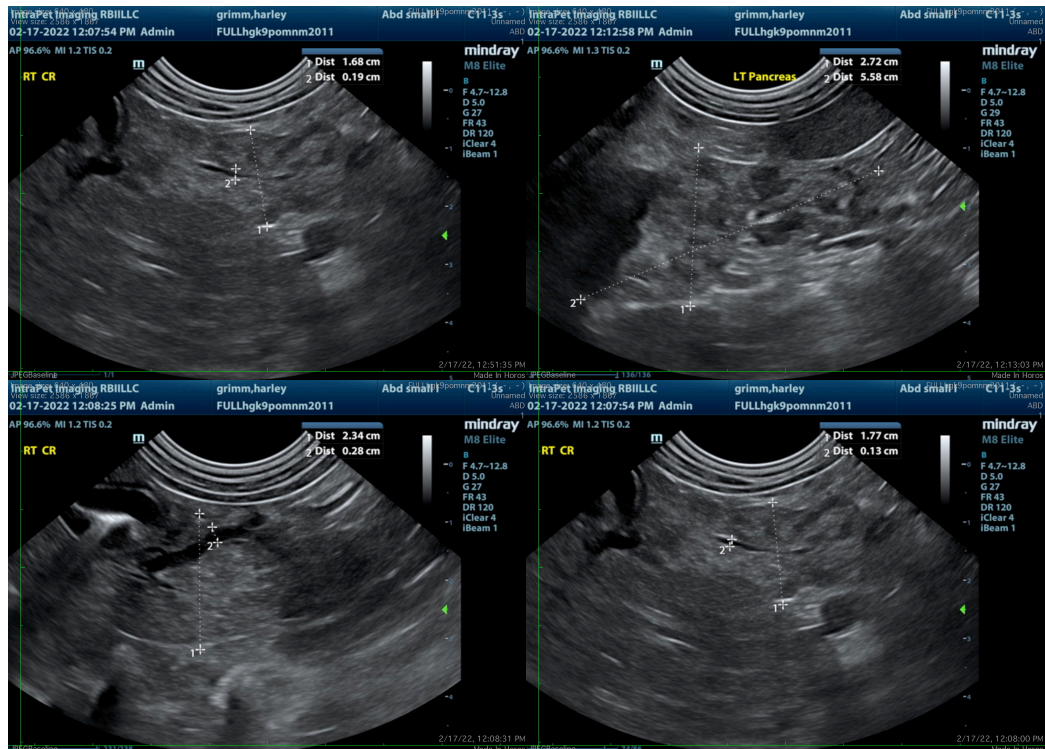
- Homogeneous mass on the tail of the spleen – Differentials include benign extramedullary hematopoiesis or nodular regeneration as well as infiltrative neoplasia such as round cell neoplasia, given the multifocal disease noted.

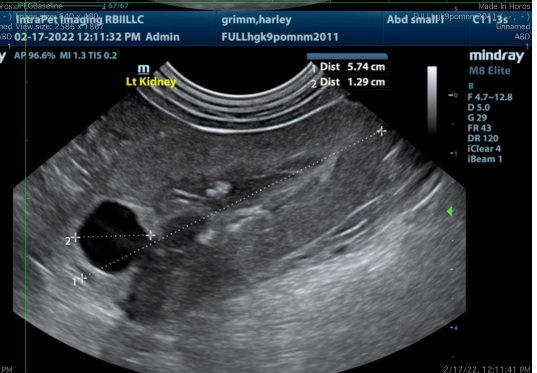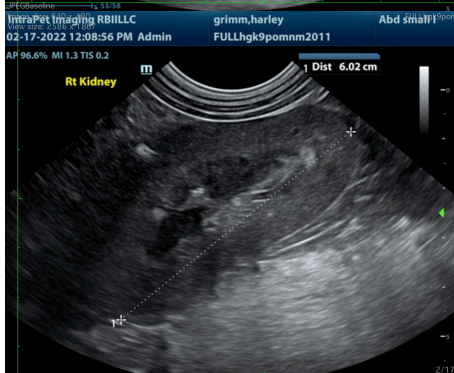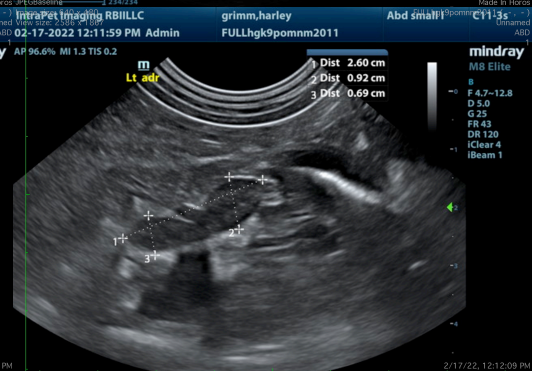
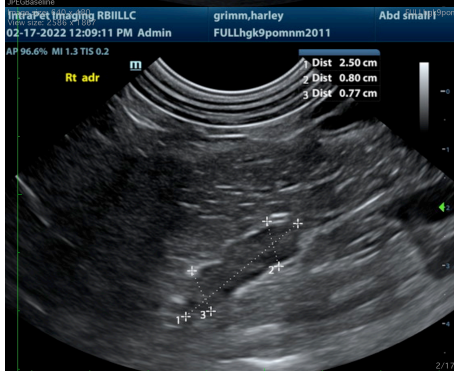
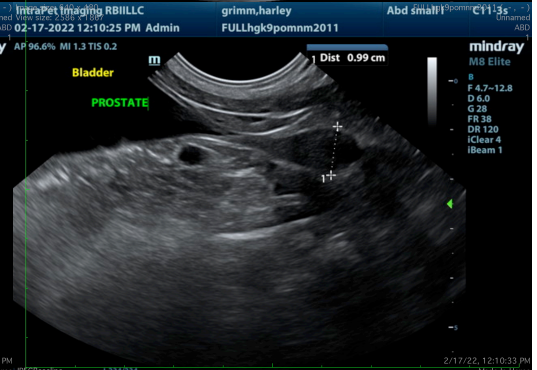
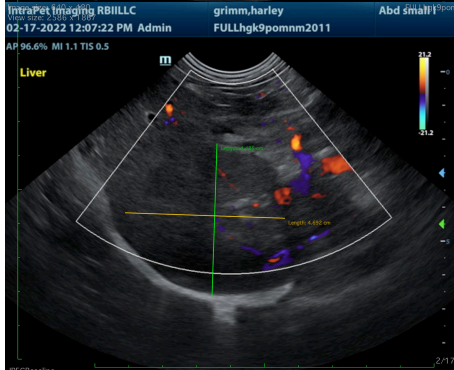
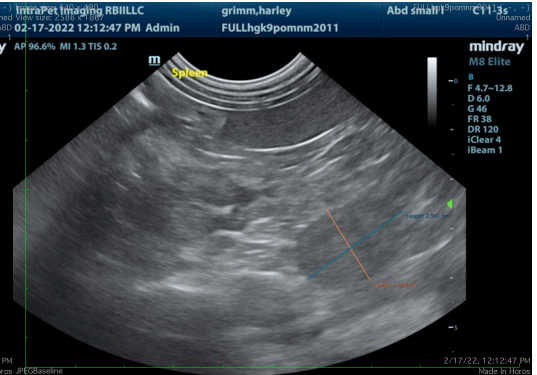
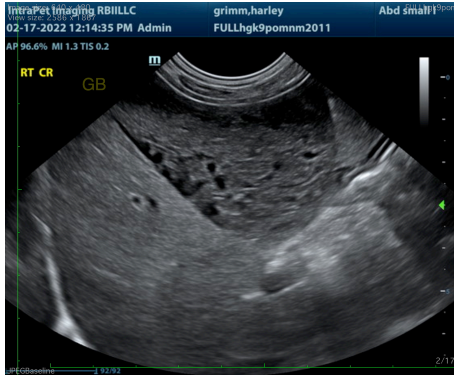SECONDARY FINDINGS

- Early mucocele – Cholecystic debris is of unknown clinical significance. It can be seen with biliary stasis from fasting or illness. Cholecystic debris is not necessarily related to hepatobiliary disease. The non-dependent nature of this sludge combined with the cystic areas are suggestive, however, of possible emerging cystic mucosal hyperplasia or early gallbladder mucocele.
- Age related kidney change with an incidental renal cortical cyst in the left cranial pole – This finding is expected/consistent with age-related mild degenerative disease and should be interpreted clinically in combination with laboratory changes.

INTERPRETATION OF THE FINDINGS & FURTHER RECOMMENDATIONS

Recommendations include a fine needle aspirate of the liver mass, the tail of the spleen, as well as the pancreas if the patient's coagulation status is appropriate. 3-view thoracic radiographs are also recommended for further assessment of metastatic disease if not recently evaluated.





The information and recommendations provided are based on the images presented by the referring veterinarian/sonographer. No evaluation can be communicated regarding pathology that was not visible in the image/video clips provided.

Thank you for this referral. If the clinical or image interpretation does not parallel your findings or if I can be of any further assistance please contact me.

Beth Johnson, DVM, DACVIM
Beth.Johnson@sonopath.com