



PATIENT

Oscar Izzi

SPECIES

Canine

BREED

Shih Tzu

SEX

Neutered Male

AGE

9 Years

WEIGHT

12 lbs

INTERPRETED BY

Beth Johnson, DVM
DACVIM

IMAGING PERFORMED BY

Julia Bakker, DVM

HOSPITAL NAME

Orange Blossom
Veterinary Imaging

REFERRING VET

Kristina Ramer, DVM

INVOICE

73023

DATE

2/17/26

PRESENTING CLINICAL SIGNS

History of taking palladia for anal gland adenocarcinoma (surgically resected and no current evidence of recurrence) and intestinal malignancy (suspected carcinoid or adenocarcinoma from biopsies). Patient doing very well on palladia. Oncologist requests AUS repeat.

Abnormal PE/Chem/CBC/UA Results: Previous AUS in 2024 attached for comparison

ULTRASONOGRAPHIC EXAMINATION OF THE ABDOMEN

Urinary System

The urinary bladder is adequately distended with anechoic contents. No masses, inflammatory changes, echogenic sediment or cystoliths are observed. The urinary bladder, trigone and visible pelvic urethra are normal in thickness with a smooth mucosal surface.

Prostate is normal in size, echotexture and echogenicity for a neutered male.

The right kidney is normal in size (3.0 cm), shape and echogenicity. It has smooth peripheral margination. There is a normal 1:3 cortex to medulla ratio with appropriate corticomedullary distinction. There is no evidence of pyelectasia, mineral or infarcts observed.

The left kidney is normal in size (3.8 cm), shape and echogenicity. It has smooth peripheral margination. There is a normal 1:3 cortex to medulla ratio with appropriate corticomedullary distinction. There is no evidence of pyelectasia, mineral or infarcts observed.

Adrenal Glands

The right adrenal gland is normal in size (0.50 cm at cranial pole and 0.43 cm at caudal pole), shape and overall architecture, echogenicity and echotexture. Visible surrounding vasculature appears normal.

The left adrenal gland is normal in size (0.32 cm at cranial pole and 0.60 cm at caudal pole), shape and overall architecture, echogenicity and echotexture. Visible surrounding vasculature appears normal.

Spleen

The spleen is subjectively normal in size with a normal smooth capsular contour. Parenchyma is appropriately finely textured and homogenous with normal echogenicity relative to surrounding tissue (hyperechoic to liver). No focal nodules or masses are observed. Splenic vasculature appears normal.

Liver

The liver is subjectively normal in size with normal smooth curvilinear peripheral contour. Parenchyma is appropriately hypoechoic to the spleen in echogenicity and appropriately mildly coarse and homogenous in echotexture. No focal lesions are observed. Visible vasculature and biliary tree appear normal without distension or congestion.

The gallbladder is non-distended in size. The wall of the gallbladder appears as a thin hyperechoic/calcified rim casting a distinct distal acoustic shadow. Luminal contents are primarily anechoic. There is no evidence of cystic or common bile duct dilation.

Gastrointestinal

The visible stomach wall is normal in thickness and layering. The lumen of the stomach is empty with no evidence of obstruction, foreign material or infiltrative disease. Pyloric outflow tract appears patent.



PATIENT

Oscar Izzi

SPECIES

Canine

BREED

Shih Tzu

SEX

Neutered Male

AGE

9 Years

WEIGHT

12 lbs

INTERPRETED BY

Beth Johnson, DVM
DACVIM

IMAGING PERFORMED BY

Julia Bakker, DVM

HOSPITAL NAME

Orange Blossom
Veterinary Imaging

REFERRING VET

Kristina Ramer, DVM

INVOICE

73023

DATE

2/17/26

The visible small intestines are normal in wall thickness and layering. Small intestinal motility appears adequate (1-3 contractions per min). The lumen of the small intestine is empty with no evidence of obstruction, foreign material or infiltrative disease.

The visible colon is normal in wall thickness (< 0.2 cm) and layering. Contents are consistent with normal formed feces and gas.

Pancreas

The pancreas that is observed appears appropriately isoechoic to surrounding omental fat. Visible capsule is smooth and normal in contour. Visible pancreatic parenchyma is homogenous and unremarkable. There is no visible pancreatic duct dilation. There is no evidence of active peripancreatic inflammation.

Free Abdomen

There is no visible free peritoneal effusion noted in these images.

A prominent medial iliac lymph node is noted with an ovoid iso- to hypoechoic appearance, measuring 0.81 cm thick x 2.4 cm long.

PRIMARY FINDINGS

- Moderate medial iliac lymphadenopathy – This is a new finding compared to the attached previous ultrasound report and could represent a benign inflammatory process, but infiltrative/metastatic neoplasia can't be ruled out without tissue sampling.

SECONDARY FINDINGS

- Porcelain gallbladder – Porcelain (calcified) gallbladder is an uncommon finding in companion animals and has been observed as both an incidental finding and associated with biliary neoplasia. In humans, porcelain gallbladder can be a manifestation of chronic gallbladder disease, chronic cholecystitis, intramural hemorrhage with subsequent calcification, imbalances in calcium metabolism, and even giardiasis. This finding should be interpreted in combination with any clinical signs and/or laboratory changes suggestive of biliary disease and/or calcium dysregulation, etc.

INTERPRETATION OF THE FINDINGS & FURTHER RECOMMENDATIONS

Three view thoracic radiographs are recommended for further assessment of cardio-pulmonary status as well as to further evaluate for any evidence of metastatic disease, if not recently evaluated.

If it can safely be reached, fine needle aspirates of the enlarged medial iliac lymph node could be considered if patient's coagulation status is appropriate.



PATIENT

Oscar Izzi

SPECIES

Canine

BREED

Shih Tzu

SEX

Neutered Male

AGE

9 Years

WEIGHT

12 lbs

INTERPRETED BY

Beth Johnson, DVM
DACVIM

IMAGING PERFORMED BY

Julia Bakker, DVM

HOSPITAL NAME

Orange Blossom
Veterinary Imaging

REFERRING VET

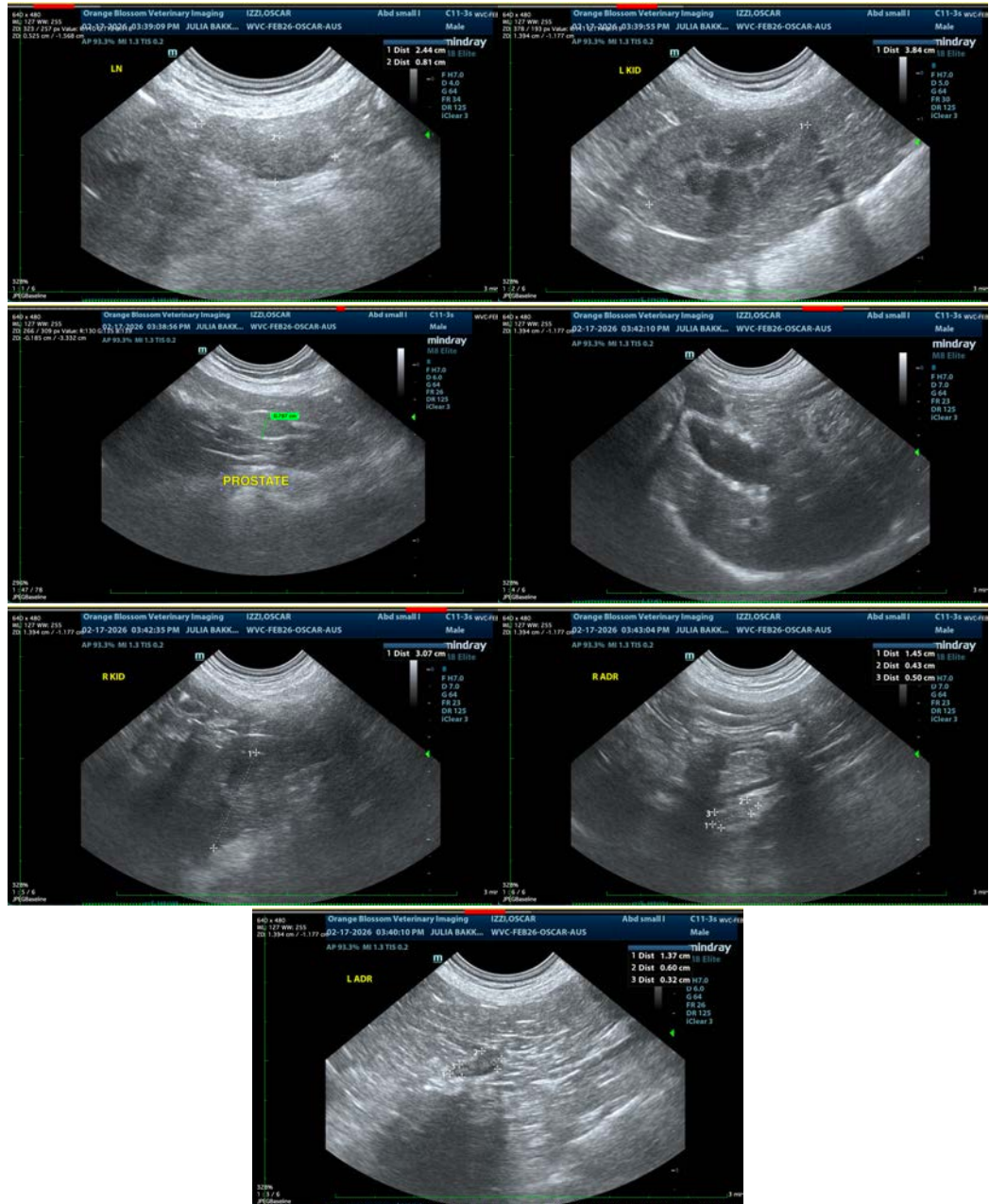
Kristina Ramer, DVM

INVOICE

73023

DATE

2/17/26



The information and recommendations provided are based on the images presented by the referring veterinarian/sonographer. No evaluation can be communicated regarding pathology that was not visible in the image/video clips provided.

Thank you for this referral. If the clinical or image interpretation does not parallel your findings or if I can be of any further assistance please contact me.

Beth Johnson, DVM, DACVIM
info@sonopath.com