



PATIENT PRESENTING CLINICAL SIGNS

PATIENT
 Mimi Agg

SPECIES

Feline

BREED

DSH

SEX

Neutered Male

AGE

1.5 Years

WEIGHT

4.5 kg

INTERPRETED BY

Beth Johnson, DVM
 DACVIM

IMAGING PERFORMED BY

Kelly Reschny

HOSPITAL NAME

Novel Vet Clinic

REFERRING VET

Dr. Knap

INVOICE

13845

DATE

02/17/26

- presented Saturday for ongoing vomiting and lethargy. Was seen one week previous for similar signs and was sent home following an injection of maropitant.
- Owner reports patient improved for 2-3 days after previous visit - started eating a little, no vomiting observed. After the third day, condition deteriorated again with loss of appetite, lethargy, and return of vomiting.
- Friday night, patient vomited approximately 6 large piles.
- Patient is not his normal self - no energy, not purring.
- decreased frequency of BMs, but normal size and consistency when passed
- history of dietary indiscretions, owner suspects GI foreign body
- abdominal radiographs showed no evidence of foreign material or obstructive pattern
- bloodwork was unremarkable other than mild hypokalemia
- Current Medications: maropitant 4 mg/kg PO q24

Abnormal PE/Chem/CBC/UA Results: K+ = 3.2 mmol/L, basophils 0.27 x10⁹/L

ULTRASONOGRAPHIC EXAMINATION OF THE ABDOMEN

Urinary System

The urinary bladder is not fully distended, almost empty. It contains adequate contents as well as what appears to be a large amount of mineral/sand debris, possibly small cystoliths. No masses or evidence of obstruction are observed. The urinary bladder, trigone, and invisible pelvic urethra are normal in thickness with a smooth mucosal surface.

Left kidney is normal in size (4.09 cm), shape and echogenicity. It has smooth peripheral margination. There is a normal 1:3 cortex to medulla ratio with appropriate corticomedullary distinction. There is no evidence of pyelectasia, mineral or infarcts observed.

Right kidney is normal in size (3.93 cm), shape and echogenicity. It has smooth peripheral margination. There is a normal 1:3 cortex to medulla ratio with appropriate corticomedullary distinction. There is no evidence of pyelectasia, mineral or infarcts observed.

Adrenal Glands

Left adrenal gland is normal in size (0.55 cm), shape and overall architecture, echogenicity and echotexture. Visible surrounding vasculature appears normal.

Right adrenal gland is normal in size (0.28 cm), shape and overall architecture, echogenicity and echotexture. Visible surrounding vasculature appears normal.

Spleen

Spleen is subjectively large in size with a mildly swollen but smooth capsule. Parenchyma is normal and homogenous in echogenicity and echotexture. No focal nodules or masses are observed. Splenic vasculature appears normal. The spleen measured 1.1 cm thick at the hilus.

Liver



PATIENT

Mimi Agg

Liver is subjectively normal in size with normal smooth curvilinear peripheral contour. Parenchyma is appropriately hypoechoic to the spleen in echogenicity and appropriately mildly coarse and homogenous in echotexture. No focal lesions are observed. Visible vasculature and biliary tree appear normal without distension or congestion.

SPECIES

Feline

Gallbladder is non-distended in size. The wall is smooth without visible thickening. Luminal contents are primarily anechoic. There is no evidence of cystic or common bile duct dilation.

BREED

DSH

Gastrointestinal

SEX

Neutered Male

The visible stomach wall is normal in thickness and layering. The stomach is mildly distended and contains an echogenic interface with distal progressively shadowing material consistent with hairball density (or similar fluid absorbing material) noted. Normal ingesta and gas cannot be definitively ruled out and should be considered especially without adequate fasting prior to the ultrasound.

AGE

1.5 Years

The visible small intestine demonstrates areas of mildly thick muscularis layer relative to mucosa (disruption of the normal 1:3 muscularis:mucosa ratio). Small intestinal submucosa is slightly irregular, thick and hyperechoic, without evident loss of layering appreciated. The lumen of the small intestine is mildly distended with echogenic non-shadowing luminal contents and gas consistent with normal ingesta. There is no evidence of obstruction or foreign material noted. In the right cranial abdomen medial to the right kidney, there is some small bowel/suspect duodenal contents that have some subtle shadowing similar to the stomach.

WEIGHT

4.5 kg

The visible colon is normal in wall thickness (< 0.2 cm) and layering. Contents are consistent with normal formed feces and gas.

INTERPRETED BY

Beth Johnson, DVM
 DACVIM

Pancreas

The pancreas that is observed appears appropriately isoechoic to surrounding omental fat. Visible capsule is smooth and normal in contour. Visible pancreatic parenchyma is homogenous and unremarkable. There is no visible pancreatic duct dilation. There is no evidence of active peripancreatic inflammation.

IMAGING PERFORMED BY

Kelly Reschny

Free Abdomen

HOSPITAL NAME

Novel Vet Clinic

There is no visible free peritoneal effusion noted in these images.

There is no apparent pathologic lymphadenopathy noted in these images.

REFERRING VET

Dr. Knap

ULTRASONOGRAPHIC FINDINGS

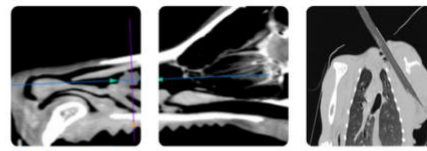
INVOICE

13845

DATE

02/17/26

- Mild/emerging inflammatory bowel disease pattern- Thick muscularis has been reported with infiltrative bowel disease including both benign inflammatory disease as well as infiltrative neoplasia such as lymphoma. No loss of layering or distinct characteristics of malignancy are present. Therefore, differentials cannot be further ranked without tissue sampling. Luminal contents could represent normal ingesta and gas. However, given the shadowing pattern combined with patient's history, foreign material within the stomach +/- proximal small such as a hairball versus other can't be ruled out. This finding should be interpreted in combination with when patient last ate and/or potentially recheck imaging following an additional 12 to 24 hours of fasting.
- Splenomegaly- can be associated with congestion caused by sedation (if sedated) but can also be associated with diffuse infiltrative disease. Both benign conditions such as extramedullary



PATIENT

Mimi Agg

SPECIES

Feline

BREED

DSH

SEX

Neutered Male

AGE

1.5 Years

WEIGHT

4.5 kg

INTERPRETED BY

Beth Johnson, DVM
 DACVIM

IMAGING PERFORMED BY

Kelly Reschny

HOSPITAL NAME

Novel Vet Clinic

REFERRING VET

Dr. Knap

INVOICE

13845

DATE

02/17/26

hematopoiesis, lymphoid hyperplasia, amyloidosis as well as infiltrative neoplastic diseases such as round cell neoplasia should be considered.

- A moderate amount of suspended mineral debris within the urinary bladder. Small cystoliths cannot be ruled out.

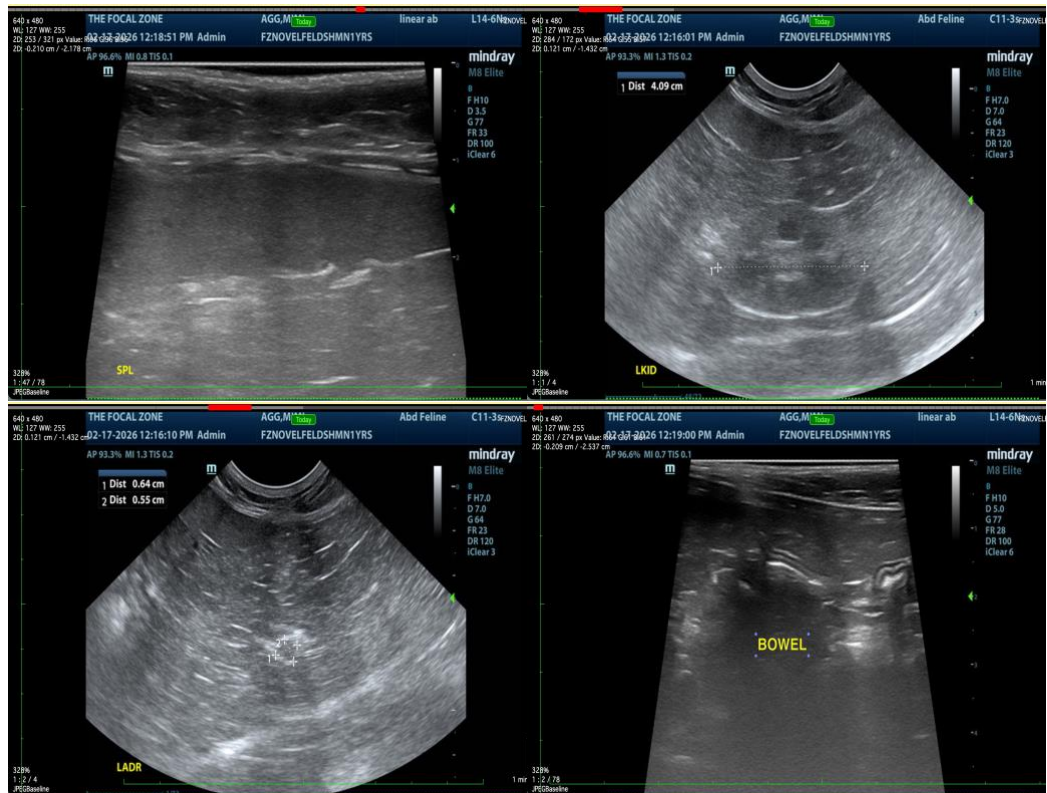
INTERPRETATION OF THE FINDINGS & FURTHER RECOMMENDATIONS

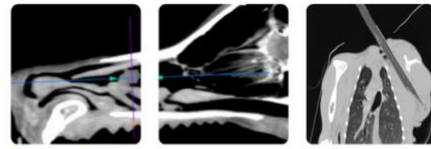
If not recently evaluated, a routine fecal/Giardia exam is recommended.

A gastrointestinal malabsorption panel (including cobalamin, folate, TLI and PLI) to Texas A&M GI Laboratory is recommended for further evaluation of GI and pancreatic function.

Fine needle aspirates of the spleen could be considered if patient's coagulation status is appropriate, especially if patient was not sedated for the ultrasound. If not recently evaluated, urinalysis and, if indicated based on urinalysis results, urine culture is recommended. If protein is present in an otherwise quiet sediment, protein quantification with a urine protein to creatinine ration is recommended.

Ultimately, however, pending results of above combined with pending results of ruling out ingesta and gas, an exploratory laparotomy for further investigation of possible foreign material and removal if discovered may be indicated. If an exploratory laparotomy is pursued, biopsies of the GI tract could be considered during that time, especially if foreign material is not present at the time of the explore. Other pre-surgical options, if foreign material is still in question, could include alternative imaging such as contrast radiography and or even upper GI gastroscopy.





PATIENT

Mimi Agg

SPECIES

Feline

BREED

DSH

SEX

Neutered Male

AGE

1.5 Years

WEIGHT

4.5 kg

INTERPRETED BY

Beth Johnson, DVM
 DACVIM

IMAGING PERFORMED BY

Kelly Reschny

HOSPITAL NAME

Novel Vet Clinic

REFERRING VET

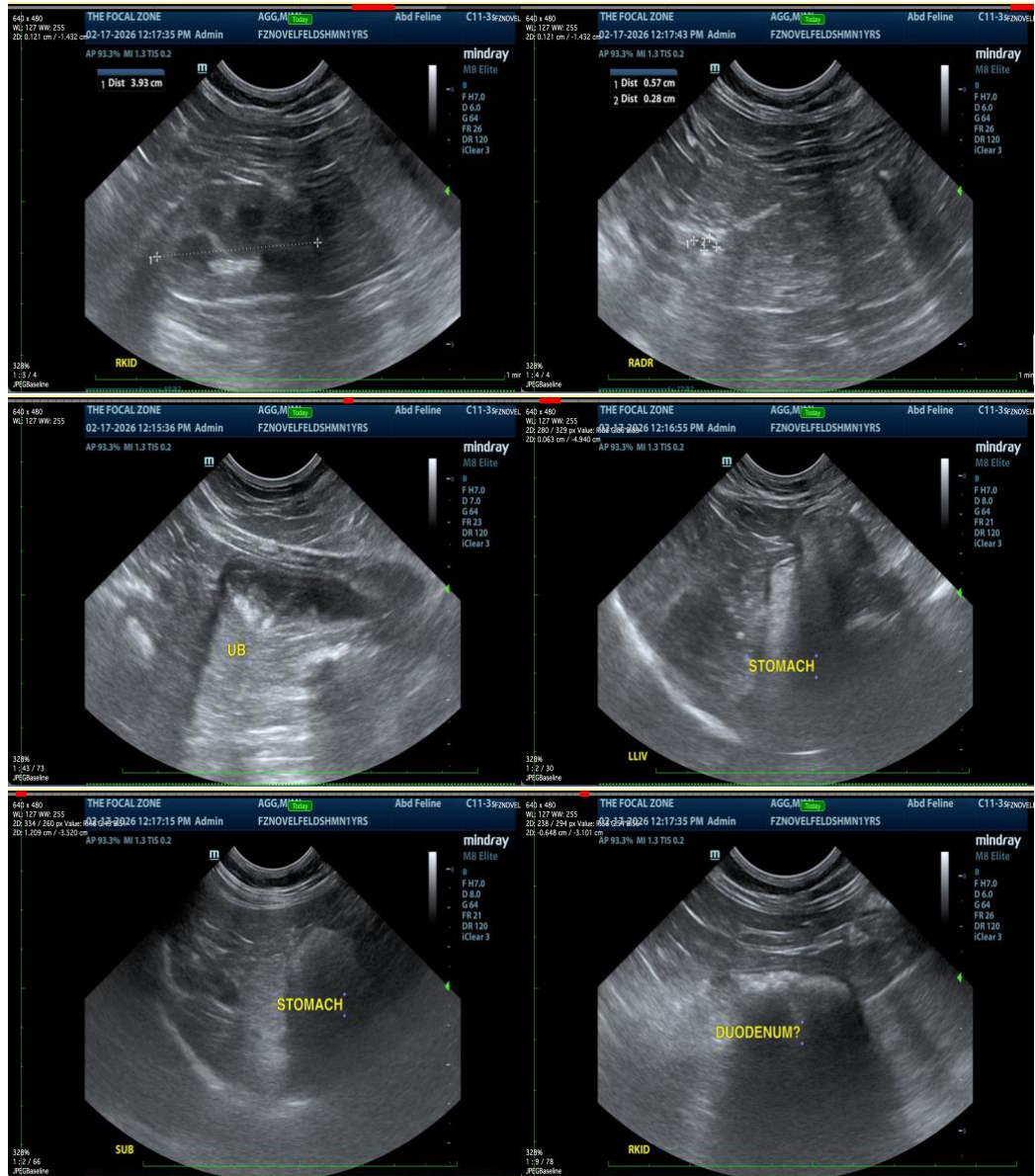
Dr. Knap

INVOICE

13845

DATE

02/17/26



The information and recommendations provided are based on the images presented by the referring veterinarian/sonographer. No evaluation can be communicated regarding pathology that was not visible in the image/video clips provided.

Thank you for this referral. If the clinical or image interpretation does not parallel your findings or if I can be of any further assistance please contact me.

Beth Johnson, DVM DACVIM

info@sonopath.com