



PATIENT

Isabela Ruiz

SPECIES

Canine

BREED

Cavalier King Charles
Spaniel

SEX

Spayed Female

AGE

7 Years

WEIGHT

26.6 pounds

INTERPRETED BY

Beth Johnson, DVM
DACVIM

IMAGING PERFORMED BY

Dr. Gabriel Ferrer
DVM

HOSPITAL NAME

Pulse Pet Ultrasound
Services

REFERRING VET

Dr. Jose Barrera

INVOICE

13841

DATE

02/17/26

PRESENTING CLINICAL SIGNS

- Px presented as a referral for an abdominal ultrasound and a echocardiogram
- Owner reports that rDVM noticed Cardiomegaly and dorsal deviation of the trachea after taking thoracic radiographs
- Dx with Pancreatitis, owner indicates that Px has never been Dx with Pancreatitis previously
- Owner reports no vomiting, no diarrhea
- Small amount of blood seen in Px's stool

Abnormal PE/Chem/CBC/UA Results: Radiographs attached below for your reference

ULTRASONOGRAPHIC EXAMINATION OF THE ABDOMEN

Urinary System

Urinary bladder is adequately distended with anechoic contents. No masses, inflammatory changes, echogenic sediment or cystoliths are observed. The urinary bladder, trigone and visible pelvic urethra are normal in thickness with a smooth mucosal surface.

Left kidney is normal in size (4.64 cm), shape and echogenicity. It has smooth peripheral margination. There is a normal 1:3 cortex to medulla ratio with appropriate corticomedullary distinction. There is no evidence of pyelectasia, mineral or infarcts observed.

Right kidney is normal in size (5.55 cm), shape and echogenicity. It has smooth peripheral margination. There is a normal 1:3 cortex to medulla ratio with appropriate corticomedullary distinction. There is no evidence of pyelectasia, mineral or infarcts observed.

Adrenal Glands

Left adrenal gland is normal in size (0.41 cm at cranial pole and 0.51 cm at caudal pole), shape and overall architecture, echogenicity and echotexture. Visible surrounding vasculature appears normal.

Right adrenal gland is normal in size (0.68 cm at cranial pole and 0.44 cm at caudal pole), shape and overall architecture, echogenicity and echotexture. Visible surrounding vasculature appears normal.

Spleen

Spleen is subjectively normal in size with a normal smooth capsular contour. Parenchyma is appropriately finely textured and homogenous with normal echogenicity relative to surrounding tissue (hyperechoic to liver). No focal nodules or masses are observed. Splenic vasculature appears normal. The spleen measured 1.5 cm thick at the hilus.

Liver

Liver is subjectively normal in size with normal smooth curvilinear peripheral contour. Parenchyma is appropriately hypoechoic to the spleen in echogenicity and appropriately mildly coarse and homogenous in echotexture. No focal lesions are observed. Visible vasculature and biliary tree appear normal without distension or congestion.

Gallbladder is moderately distended with anechoic bile as well as suspended and gravity dependent echogenic debris. The wall is smooth without visible thickening. There is no evidence of cystic or CBD dilation. There is no evidence of effusion or inflammation.



PATIENT

Isabela Ruiz

SPECIES

Canine

BREED

Cavalier King Charles
Spaniel

SEX

Spayed Female

AGE

7 Years

WEIGHT

26.6 pounds

INTERPRETED BY

Beth Johnson, DVM
DACVIM

IMAGING PERFORMED BY

Dr. Gabriel Ferrer
DVM

HOSPITAL NAME

Pulse Pet Ultrasound
Services

REFERRING VET

Dr. Jose Barrera

INVOICE

13841

DATE

02/17/26

Gastrointestinal

The visible stomach wall is normal in thickness and layering. The lumen of the stomach is mildly distended with very echogenic reverberation artifact from intraluminal gas. There is no evidence of obstruction, foreign material or infiltrative disease; however, complete visualization of far wall is partially inhibited by gas. Pyloric outflow tract appears patent.

The visible small intestine demonstrates areas of moderately thick muscularis layer relative to mucosa (disruption of the normal 1:3 muscularis:mucosa ratio). Small intestinal submucosa is slightly irregular, thick and hyperechoic, without evident loss of layering appreciated. The lumen of the small intestine is empty with no evidence of obstruction or foreign material.

The visible colon is normal in wall thickness (< 0.2 cm) and layering. Contents are consistent with normal formed feces and gas.

Pancreas

The pancreas that is observed appears appropriately isoechoic to surrounding omental fat. Visible capsule is smooth and normal in contour. Visible pancreatic parenchyma is homogenous and unremarkable. There is no visible pancreatic duct dilation. There is no evidence of active peripancreatic inflammation.

Free Abdomen

Mesenteric and medial iliac lymph nodes are prominent in size with swollen capsular contour. Normal elongated shape (length to width ratio) is maintained. There is no loss of parenchymal detail. No free fluid was present.

ULTRASONOGRAPHIC FINDINGS

Primary Findings

- Moderate inflammatory bowel disease pattern- Thick muscularis has been reported with infiltrative bowel disease including both benign inflammatory disease as well as infiltrative neoplasia such as lymphoma. No loss of layering or distinct characteristics of malignancy are present. Therefore, differentials cannot be further ranked without tissue sampling.
- Mildly mesenteric and moderately medial iliac lymphadenopathy- infiltrative neoplastic disease cannot be ruled out but is considered less likely.

Secondary Findings

- Moderate gallbladder debris- Cholecystic debris is of unknown clinical significance. It can be seen with biliary stasis from fasting or illness. Cholecystic debris is not necessarily related to hepatobiliary disease. Echogenic bile is most commonly an incidental finding in dogs and should be interpreted in combination with clinical signs such as nausea, inappetence, cranial abdominal discomfort and/or laboratory changes such as increased ALP and/or increased Tbili.

INTERPRETATION OF THE FINDINGS & FURTHER RECOMMENDATIONS

- If not recently evaluated, a general metabolic health screen (CBC, chemistry panel with electrolytes and urinalysis) is recommended.



PATIENT

Isabela Ruiz

SPECIES

Canine

BREED

Cavalier King Charles
Spaniel

SEX

Spayed Female

AGE

7 Years

WEIGHT

26.6 pounds

INTERPRETED BY

Beth Johnson, DVM
DACVIM

IMAGING PERFORMED BY

Dr. Gabriel Ferrer
DVM

HOSPITAL NAME

Pulse Pet Ultrasound
Services

REFERRING VET

Dr. Jose Barrera

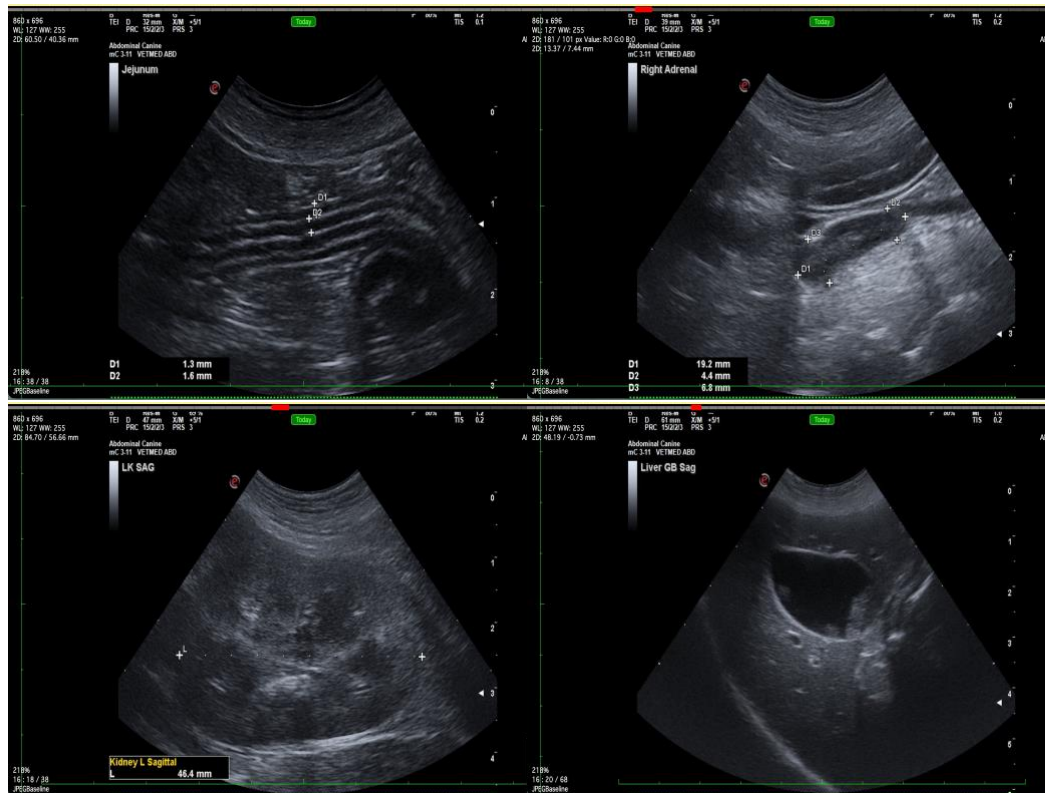
INVOICE

13841

DATE

02/17/26

- A routine fecal/Giardia exam is recommended if not recently evaluated.
- A gastrointestinal malabsorption panel (including cobalamin, folate, TLI and PLI) to Texas A&M GI Laboratory is recommended for further evaluation of GI and pancreatic function.
- A fecal enteropathogen PCR panel to Texas A&M GI Laboratory could be considered for further evaluation of possible infectious disease. Contact lab for recommendations on how long to discontinue antibiotics (if indicated) prior to obtaining a stool sample for submission.
- If a diagnosis is not obtained, ultimately tissue sampling may be warranted, in which case both an upper and lower GI gastroscopy/endoscopy/colonoscopy could be considered for biopsies of small and large bowel.
- In the meantime, supportive/symptomatic medical management of clinical signs is recommended, including a probiotic (such as visbiome or proviable), empirical deworming with a 5-day course of Panacur and, if tolerated, a transition in diet, based on trial-and-error response, beginning possibly with a gastrointestinal biome diet vs a hydrolyzed protein diet vs other. Some patients respond to one brand/version of a hydrolyzed protein diet better than another brand, so several brand attempts may be required.





PATIENT

Isabela Ruiz

SPECIES

Canine

BREED

Cavalier King Charles
Spaniel

SEX

Spayed Female

AGE

7 Years

WEIGHT

26.6 pounds

INTERPRETED BY

Beth Johnson, DVM
DACVIM

IMAGING PERFORMED BY

Dr. Gabriel Ferrer
DVM

HOSPITAL NAME

Pulse Pet Ultrasound
Services

REFERRING VET

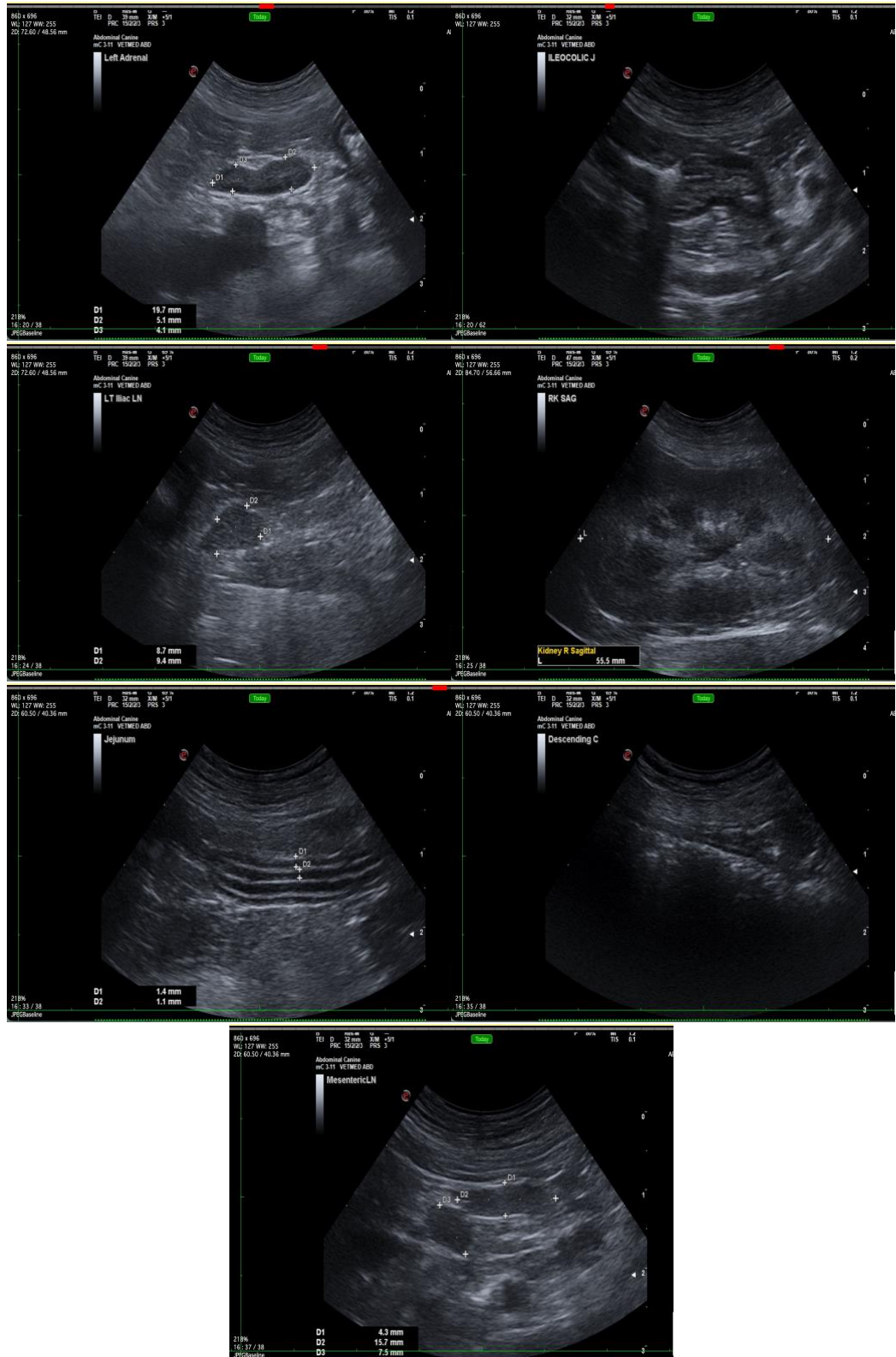
Dr. Jose Barrera

INVOICE

13841

DATE

02/17/26





PATIENT

Isabela Ruiz

SPECIES

Canine

BREED

Cavalier King Charles
Spaniel

SEX

Spayed Female

AGE

7 Years

WEIGHT

26.6 pounds

INTERPRETED BY

Beth Johnson, DVM
DACVIM

IMAGING PERFORMED BY

Dr. Gabriel Ferrer
DVM

HOSPITAL NAME

Pulse Pet Ultrasound
Services

REFERRING VET

Dr. jose Barrera

INVOICE

13841

DATE

02/17/26

The information and recommendations provided are based on the images presented by the referring veterinarian/sonographer. No evaluation can be communicated regarding pathology that was not visible in the image/video clips provided.

Thank you for this referral. If the clinical or image interpretation does not parallel your findings or if I can be of any further assistance, please contact me.

Beth Johnson, DVM DACVIM

info@sonopath.com