



DATE	PRESENTING CLINICAL SIGNS
2/17/23	1/15/2023: Decreased appetite, PU/PD, straining while having BM (BM's come out long & thin) unable to hold urine- will have accidents in the house, +/- lethargic, Right hip tense- decreased range of motion.
<b>PATIENT</b>	Left elbow, mild crepitus (+/- Right carpus). Large amount of flea dirt present on patient. Patient will react adversely to rectal exam (increased prostate?), attempted Anal Gland Expression (both large/full).
Sherman Keithley	2/13/2023: Urinating sometimes in large amounts/ sometimes a little bit here & there- straining
<b>SPECIES</b>	Current Medications: Carprofen 100 mg BID started 1/27/2023 (started SID per owner?)- Helped Instantly, Enrofloxacin 136 mg, 1 po SID in PM started 1/26/2023- Did NOT see to help, Gabapentin 900 mg & Trazodone 200 mg, rx'd 2/13/2-23 for use prior to ultrasound (Fractious patient)
Canine	Lab Results: 1/26/23: Amylase- 1169, PPSL- 526, Eosinophils- 1370
<b>BREED</b>	UA, USG- 1/020, Protein 1+, Accuplex- Negative
Labrador X	Radiographs: NSF.
<b>SEX</b>	Date of Previous IntraPet Ultrasound: No previous.
Neutered Male	Sedation: Not required to complete full diagnostic ultrasound.
	Stat Report: Not requested.
	Imaging Performed By: Rachel Brillhart, RDMS.
	<b>ULTRASONOGRAPHIC EXAMINATION OF THE ABDOMEN</b>
<b>AGE</b>	<b>Urinary System</b>
11/12/14	The urinary bladder is moderately subjectively over distended with anechoic contents. No masses, inflammatory changes, echogenic sediment or cystoliths are observed. The urinary bladder, trigone and visible pelvic urethra are normal in thickness with a smooth mucosal surface.
<b>WEIGHT</b>	The prostate is symmetrically enlarged for a neutered dog, measuring 3.83 cm wide, with smooth margins that remain well differentiated from surrounding tissue. A normal bilobed shape is also maintained. However, parenchyma is diffusely heterogeneous with a 2.5 cm hypoechoic mineralized area appreciated. The surrounding area is markedly enhanced with hyperechoic mesenteric fat.
103 Pounds	The right kidney is normal in size (8.09 cm), shape and echogenicity. It has smooth peripheral margination. There is a normal 1:3 cortex to medulla ratio with appropriate corticomedullary distinction. There is no evidence of pyelectasia, mineral or infarcts observed.
<b>INTERPRETED BY</b>	The left kidney is normal in size (7.63 cm), shape and echogenicity. Pyelectasia present measuring 0.50 cm in the sagittal view. It has smooth peripheral margination. There is a normal 1:3 cortex to medulla ratio with appropriate corticomedullary distinction. There is no evidence of mineral or infarcts observed.
Beth Johnson, DVM DACVIM	
<b>HOSPITAL NAME</b>	
Bel Air Vet Hospital	
<b>REFERRING VET</b>	
Dr. Stevenson	
<b>INVOICE</b>	<b>Adrenal Glands</b>
45360	The right adrenal gland is normal in size (3.52 cm long x 0.98 cm at the cranial pole and 1.1 cm at the caudal pole), shape and contour. Corticomedullary structure is unremarkable. Visible surrounding vasculature appears normal.
	The left adrenal gland is normal in size (3.27 cm long x 0.66 cm at the cranial pole and 0.70 cm at the caudal pole), shape and contour. Corticomedullary structure is unremarkable. Visible surrounding vasculature appears normal.
	<b>Spleen</b>
	The spleen is subjectively normal in size with a normal smooth capsular contour. Parenchyma is appropriately finely textured and homogenous with normal echogenicity relative to surrounding tissue (hyperechoic to liver). No focal nodules or masses are observed. Splenic vasculature appears normal.

### ***Liver***

The liver is subjectively normal in size with normal smooth curvilinear peripheral contour. Parenchyma is appropriately hypoechoic to the spleen in echogenicity and appropriately mildly coarse and homogenous in echotexture. No focal lesions are observed. Visible vasculature and biliary tree appear normal without distension or congestion.

The gallbladder is non-distended in size. The wall is smooth without visible thickening. Luminal contents are primarily anechoic. There is no evidence of cystic or common bile duct dilation.

### ***Gastrointestinal***

The stomach wall is normal in thickness (canine < 0.5 cm and feline < 0.4 cm) and layering. The lumen of the stomach is empty with no evidence of obstruction, foreign material or infiltrative disease. Pyloric outflow tract appears patent.

The visible small intestines are normal in wall thickness and layering (canine duodenum < 0.5 cm and feline duodenum < 0.4 cm; other < 0.3 cm). Small intestinal motility appears adequate (1-3 contractions per min). The lumen of the small intestine is empty with no evidence of obstruction, foreign material or infiltrative disease.

The visible colon is normal in wall thickness (< 0.2 cm) and layering. Contents are consistent with normal formed feces and gas.

### ***Pancreas***

The pancreatic parenchyma is appropriately isoechoic to surrounding tissue. Visible capsule is smooth and normal in contour. There is no visible pancreatic duct dilation. There is no evidence of active peripancreatic inflammation.

### ***Free Abdomen***

There is no evidence of free peritoneal effusion noted in these images.

The lymph nodes are prominent in size with swollen capsular contour. Normal elongated shape (length to width ratio) is maintained. There is no loss of parenchymal detail. Example of lymph node measures 0.99 cm thick.

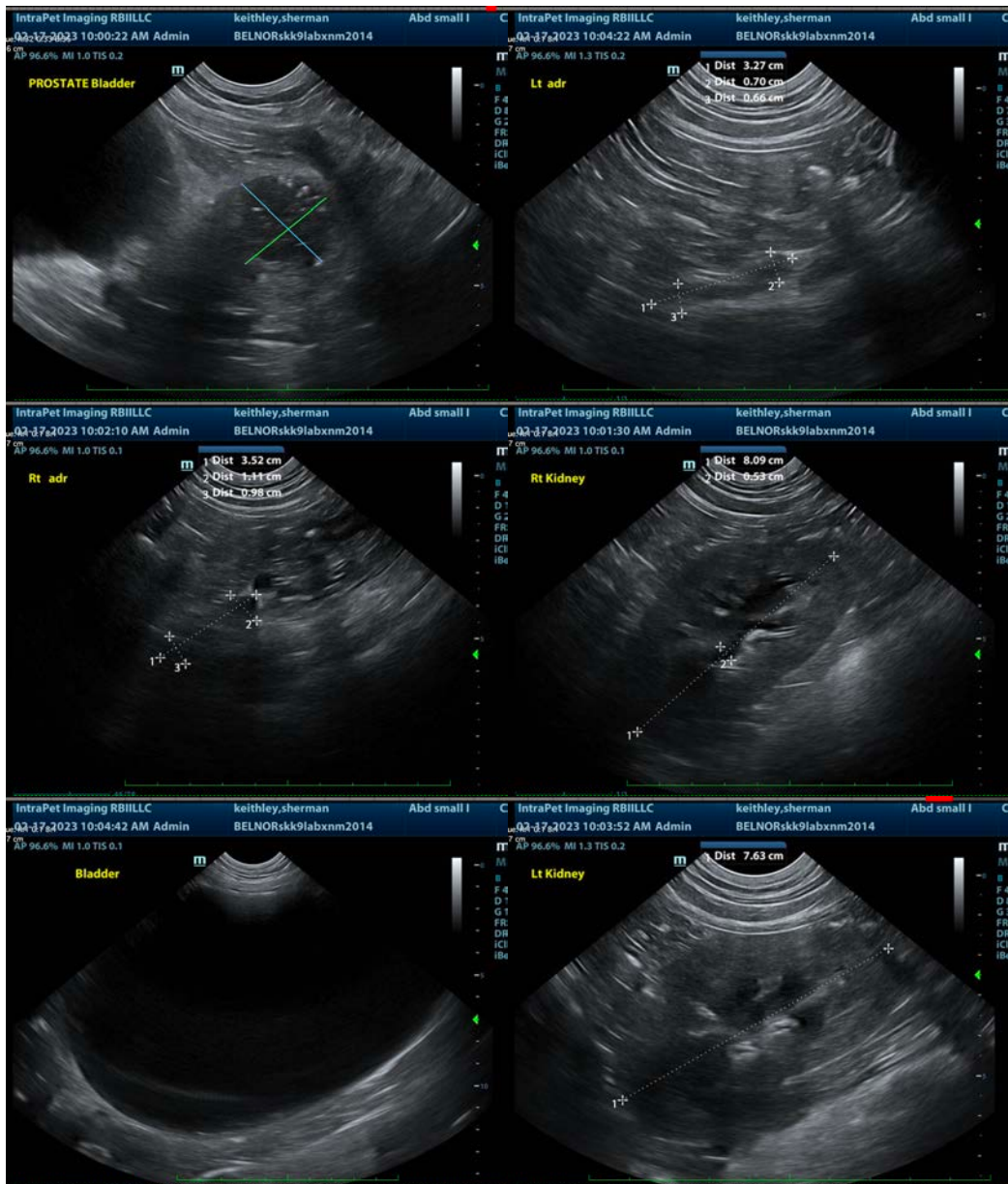
## **ULTRASONOGRAPHIC FINDINGS**

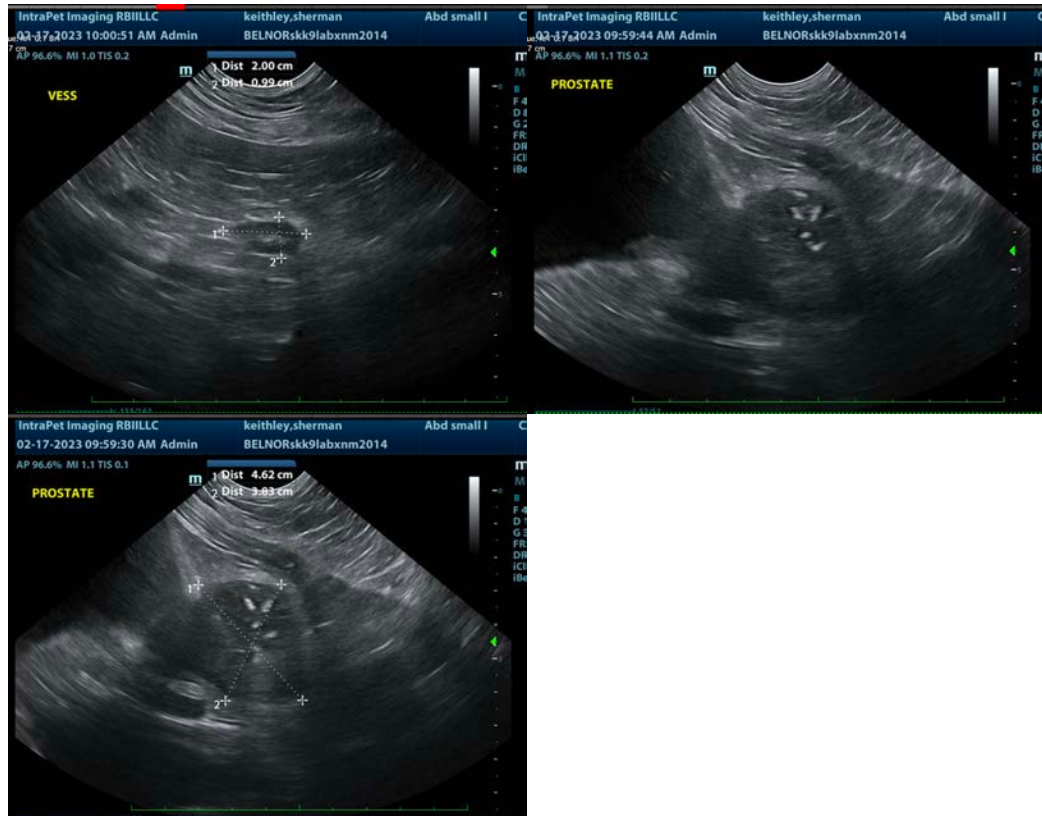
- **Heterogeneous mineralized prostatomegaly with evidence of periprostatic inflammation** – This can be seen with active prostatitis, bacterial prostatitis, and even an emerging prostatic abscess, as well as potentially infiltrative neoplasia cannot be ruled out.
- **Right kidney pyelectasia** – Differentials for pyelectasia include pyelonephritis, diuresis, congenital malformation or ureteral or lower urinary tract obstruction. The over distended urinary bladder and mild pyelectasia are likely the result of partial lower urinary outflow obstruction caused by the prostatomegaly.
- **Reactive medial iliac lymph nodes** – infiltrative neoplastic disease cannot be ruled out but is considered less likely.

## INTERPRETATION OF THE FINDINGS & FURTHER RECOMMENDATIONS

Urinalysis and urine culture, if indicated based on urinalysis results, are recommended. Submission of urine to look for BRAF gene mutation, which is associated with urinary bladder/prostate cancer, could be considered. Other diagnostic options include traumatic catheterization or fine needle aspirate of the prostate (with small risk of tumor seeding/trailing) for further sampling.

In the meantime, broad-spectrum antibiotics with good prostate penetration and an anti-inflammatory (as are reportedly already in place) are recommended to help alleviate clinical signs if possible while awaiting results.





The information and recommendations provided are based on the images presented by the referring veterinarian/sonographer. No evaluation can be communicated regarding pathology that was not visible in the image/video clips provided.

Thank you for this referral. If the clinical or image interpretation does not parallel your findings or if I can be of any further assistance please contact me.

**Beth Johnson, DVM, DACVIM**  
Beth.Johnson@sonopath.com