



PATIENT	PRESENTING CLINICAL SIGNS
Taymee Gomez	Abdominal ultrasound to assess liver and prostate; considering FNA. Abnormal PE/Chem/CBC/UA Results: CBC: WNL. Chem: ALT 162, ALP 173.
SPECIES	ULTRASONOGRAPHIC EXAMINATION OF THE ABDOMEN
Canine	Urinary System
BREED	The urinary bladder is moderately distended with anechoic contents. No masses, inflammatory changes, or cystoliths are observed. A small, echogenic, non-shadowing density is noted along the dependent wall. The urinary bladder, trigone and visible pelvic urethra are normal in thickness with a smooth mucosal surface.
Pomeranian	
SEX	The prostate is mildly symmetrically enlarged with smooth margins that are well differentiated from shadowing tissue, and a normal bilobed shape is maintained. However, parenchyma is heterogeneous with scattered, hyperechoic foci present. Mineral is appreciated within the parenchyma. No cysts are noted.
Neutered Male	
AGE	The right kidney is normal in size (3.47 cm), shape and echogenicity. It has smooth peripheral margination. There is a normal 1:3 cortex to medulla ratio with appropriate corticomedullary distinction. There is no evidence of pyelectasia or infarcts observed. Non-obstructive linear multifocal hyperechoic diverticular foci with acoustic shadowing are noted.
15 Years	
WEIGHT	The left kidney is normal in size (3.67 cm), shape and echogenicity. It has smooth peripheral margination. There is a normal 1:3 cortex to medulla ratio with appropriate corticomedullary distinction. There is no evidence of pyelectasia or infarcts observed. Non-obstructive linear multifocal hyperechoic diverticular foci with acoustic shadowing are noted.
N/A	
INTERPRETED BY	Adrenal Glands
Beth Johnson, DVM DACVIM	The right adrenal gland is normal in size (1.52 cm long x 0.83 cm at the cranial pole and 0.51 cm at the caudal pole), shape and contour. Corticomedullary structure is unremarkable. Visible surrounding vasculature appears normal.
IMAGING PERFORMED BY	The left adrenal gland is normal in size (1.33 cm long x 0.42 cm at the cranial pole and 0.56 cm at the caudal pole), shape and contour. Corticomedullary structure is unremarkable. Visible surrounding vasculature appears normal.
Kelly Vazquez	
HOSPITAL NAME	Spleen
Animal Paradise Hospital	The spleen is subjectively normal in size with a normal smooth capsular contour. Parenchyma is appropriately finely textured and homogenous with normal echogenicity relative to surrounding tissue (hyperechoic to liver). No focal nodules or masses are observed. Splenic vasculature appears normal.
REFERRING VET	Liver
Dr. ElShafie	The liver is subjectively normal in size with normal smooth curvilinear peripheral contour. Parenchyma is appropriately hypoechoic to the spleen in echogenicity and appropriately mildly coarse and homogenous in echotexture. No focal lesions are observed. Visible vasculature and biliary tree appear normal without distension or congestion.
INVOICE	GB is moderately distended with anechoic bile and gravity dependent echogenic sediment, some of which contains mineral/sand. The wall is smooth without visible thickening. There is no evidence of cystic or CBD dilation. There is no evidence of effusion or inflammation.
35722	
DATE	
2/17/22	



PATIENT

Gastrointestinal

Taymee Gomez

The stomach wall is normal in thickness (canine < 0.5 cm and feline < 0.4 cm) and layering. The lumen of the stomach is empty with no evidence of obstruction, foreign material or infiltrative disease. Pyloric outflow tract appears patent.

SPECIES

Canine

The visible small intestines are normal in wall thickness and layering (canine duodenum < 0.5 cm and feline duodenum < 0.4 cm; other < 0.3 cm). Small intestinal motility appears adequate (1-3 contractions per min). The lumen of the small intestine is empty with no evidence of obstruction, foreign material or infiltrative disease.

BREED

Pomeranian

The visible colon is normal in wall thickness (< 0.2 cm) and layering. Contents are consistent with normal formed feces and gas.

SEX

Pancreas

Neutered Male

The pancreatic parenchyma is appropriately isoechoic to surrounding tissue. Visible capsule is smooth and normal in contour. There is no visible pancreatic duct dilation. There is no evidence of active peripancreatic inflammation.

AGE

Free Abdomen

15 Years

There is no evidence of peritoneal effusion. There is no apparent lymphadenopathy.

WEIGHT

ULTRASONOGRAPHIC FINDINGS

N/A

- Heterogeneous, mineralized prostatomegaly – Given the symmetrical enlargement and well differentiation from surrounding tissue, benign process such as seen with prostatitis, bacterial, fungal or other is considered likely. However, infiltrative neoplasia can mimic those changes and can't be ruled out.
- Gallbladder debris - Cholecystic debris is of unknown clinical significance. It can be seen with biliary stasis from fasting or illness. Cholecystic debris is not necessarily related to hepatobiliary disease. Echogenic bile is most commonly an incidental finding in dogs and should be interpreted in combination with clinical signs such as nausea, inappetence, cranial abdominal discomfort and/or laboratory changes such as increased ALP and/or increased Tbili.
- Non-obstructive dystrophic mineralization bilaterally in the kidneys
- Non-shadowing echogenic density within the urinary bladder – Rule outs include mucus, blood clot, non-shadowing small cystoliths versus other.

INTERPRETED BY

Beth Johnson, DVM
DACVIM

IMAGING PERFORMED BY

Kelly Vazquez

HOSPITAL NAME

Animal Paradise
Hospital

REFERRING VET

Dr. ElShafie

INTERPRETATION OF THE FINDINGS & FURTHER RECOMMENDATIONS

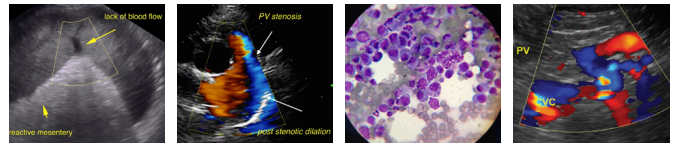
Given the prostate changes, recommendations include a urinalysis and urine culture as well as submission of urine to look for BRAF gene mutation, which is associated with urinary bladder/prostatic cancers. Other diagnostic options include a fine needle aspirate of the prostate for cytology and culture (with small risk of tumor seeding/trailing). Given the mildly increased liver enzymes and the gallbladder debris, an empirical course of broad-spectrum antibiotics combined with Ursodiol +/- Denamarin could be considered with monitoring of the liver enzymes for improvement.

INVOICE

35722

DATE

2/17/22



PATIENT

Taymee Gomez

SPECIES

Canine

BREED

Pomeranian

SEX

Neutered Male

AGE

15 Years

WEIGHT

N/A

INTERPRETED BY

Beth Johnson, DVM
DACVIM

IMAGING PERFORMED BY

Kelly Vazquez

HOSPITAL NAME

Animal Paradise
Hospital

REFERRING VET

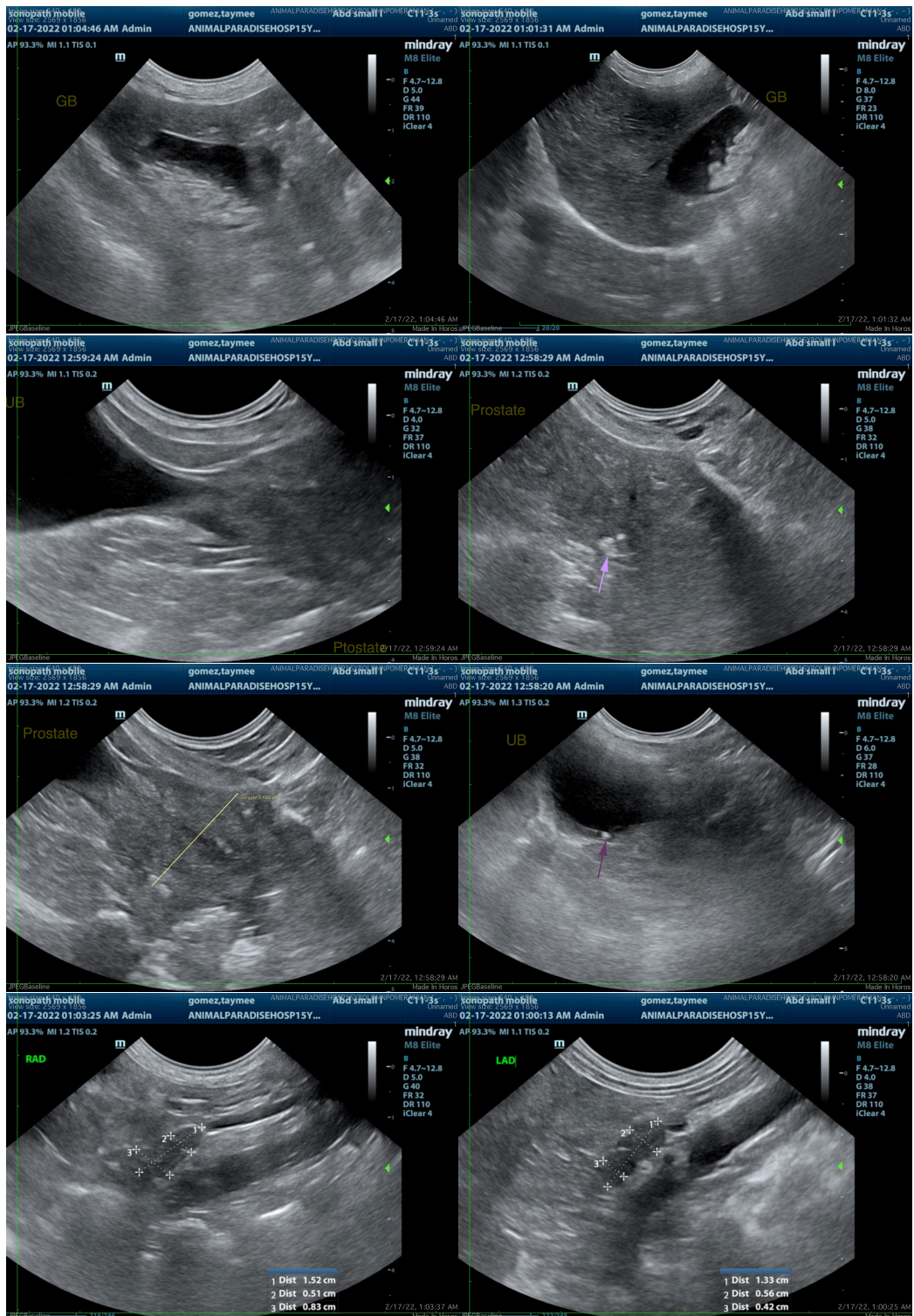
Dr. ElShafie

INVOICE

35722

DATE

2/17/22





PATIENT

Taymee Gomez

SPECIES

Canine

BREED

Pomeranian

SEX

Neutered Male

AGE

15 Years

WEIGHT

N/A

INTERPRETED BY

Beth Johnson, DVM
DACVIM

IMAGING PERFORMED BY

Kelly Vazquez

HOSPITAL NAME

Animal Paradise
Hospital

REFERRING VET

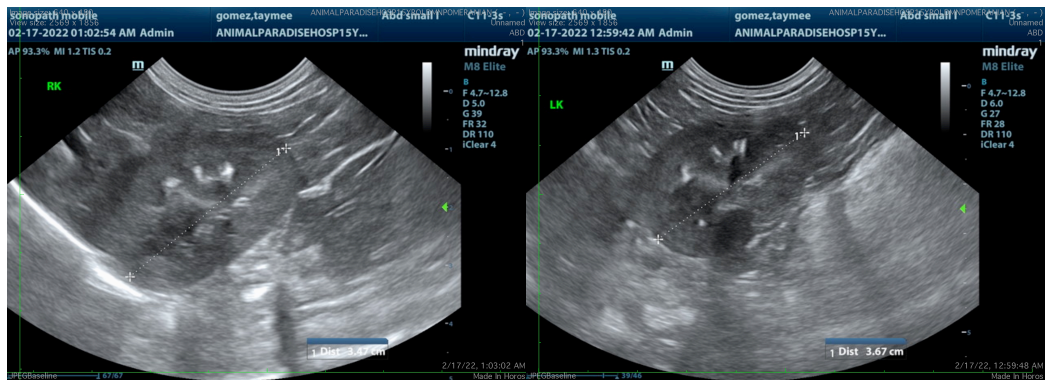
Dr. ElShafie

INVOICE

35722

DATE

2/17/22



The information and recommendations provided are based on the images presented by the referring veterinarian/sonographer. No evaluation can be communicated regarding pathology that was not visible in the image/video clips provided.

Thank you for this referral. If the clinical or image interpretation does not parallel your findings or if I can be of any further assistance please contact me.

Beth Johnson, DVM, DACVIM
Beth.Johnson@sonopath.com