



PATIENT	PRESENTING CLINICAL SIGNS
Mercy Bradley	inconsistent / intermittent incontinence while napping; does not happen overnight. not on any meds Abnormal PE/Chem/CBC/UA Results: USPG >1.040
SPECIES	ULTRASONOGRAPHIC EXAMINATION OF THE ABDOMEN
Canine	<i>Urinary System</i>
BREED	The urinary bladder is only mildly distended with anechoic contents. The apical urinary bladder wall is diffusely thick, measuring 0.56 cm thick. The mucosa is hyperechoic and irregular. No masses or cystoliths are observed. The trigone and visible pelvic urethra are normal in thickness with a smooth mucosal surface. There is no evidence around the urinary bladder of dilated ureters to indicate ectopic ureters. However, the bladder is subjectively pelvically positioned.
Beauceron	
SEX	The right kidney is normal in size (7.31 cm), shape and echogenicity. It has smooth peripheral margination. There is a normal 1:3 cortex to medulla ratio with appropriate corticomedullary distinction. There is no evidence of pyelectasia, mineral or infarcts observed.
Spayed Female	
AGE	The left kidney is normal in size (7.37 cm), shape and echogenicity. It has smooth peripheral margination. There is a normal 1:3 cortex to medulla ratio with appropriate corticomedullary distinction. There is no evidence of pyelectasia, mineral or infarcts observed.
2.5 Years	
WEIGHT	<i>Adrenal Glands</i>
74 Pounds	The right adrenal gland is normal in size (2.72 cm long x 1.52 cm at the cranial pole and 0.83 cm at the caudal pole), and subjectively flat in appearance. Corticomedullary structure is unremarkable. Visible surrounding vasculature appears normal.
INTERPRETED BY	The left adrenal gland is normal in size (3.09 cm long x 0.59 cm at the cranial pole and 0.47 cm at the caudal pole), and subjectively flat in appearance. Corticomedullary structure is unremarkable. Visible surrounding vasculature appears normal.
Beth Johnson, DVM DACVIM	
IMAGING PERFORMED BY	<i>Spleen</i>
Diane McFadden	The spleen is subjectively normal in size with a normal smooth capsular contour. Parenchyma is appropriately finely textured and homogenous with normal echogenicity relative to surrounding tissue (hyperechoic to liver). No focal nodules or masses are observed. Splenic vasculature appears normal.
HOSPITAL NAME	<i>Liver</i>
AH of Roxbury	The liver is subjectively normal in size with normal smooth curvilinear peripheral contour. Parenchyma is appropriately hypoechoic to the spleen in echogenicity and appropriately mildly coarse and homogenous in echotexture. No focal lesions are observed. Visible vasculature and biliary tree appear normal without distension or congestion.
REFERRING VET	The gallbladder is non-distended in size. The wall is smooth without visible thickening. Luminal contents are primarily anechoic. There is no evidence of cystic or common bile duct dilation.
Dr. Elia	
INVOICE	<i>Gastrointestinal</i>
35719	The stomach wall is normal in thickness (canine < 0.5 cm and feline < 0.4 cm) and layering. The lumen of the stomach is empty with no evidence of obstruction, foreign material or infiltrative disease. Pyloric outflow tract appears patent.
DATE	The visible small intestines are normal in wall thickness and layering (canine duodenum < 0.5 cm and feline duodenum < 0.4 cm; other < 0.3 cm). Small intestinal motility appears adequate (1-3 contractions
2/17/22	



PATIENT

Mercy Bradley

per min). The lumen of the small intestine is empty with no evidence of obstruction, foreign material or infiltrative disease.

The visible colon is normal in wall thickness (< 0.2 cm) and layering. Contents are consistent with normal formed feces and gas.

SPECIES

Canine

Pancreas

The pancreatic parenchyma is appropriately isoechoic to surrounding tissue. Visible capsule is smooth and normal in contour. There is no visible pancreatic duct dilation. There is no evidence of active peripancreatic inflammation.

BREED

Beauceron

Free Abdomen

There is no evidence of peritoneal effusion. There is no apparent lymphadenopathy.

SEX

Spayed Female

ULTRASONOGRAPHIC FINDINGS

- Apical bladder wall thickening – consistent with either a not completely distended bladder, or cystitis can't be ruled out. There is no visible evidence in these images of ectopic ureters. However, the bladder is subjectively pelvically positioned.
- Subjectively flat adrenal glands – most likely a normal anatomic variant. However, hypoadrenocorticism can cause subjectively flat appearing adrenals.

AGE

2.5 Years

INTERPRETATION OF THE FINDINGS & FURTHER RECOMMENDATIONS

Recommendations include a full urinalysis (if not recently evaluated) followed by a urine culture to rule out an occult urinary tract infection. Also, if not recently evaluated, a full CBC, serum chemistry panel and electrolytes are recommended. Baseline cortisol could be considered to definitively rule out unlikely but possible hypoadrenocorticism. If the baseline cortisol is <2.0, a full ACTH stimulation test is recommended. Following that, recommendations include recheck of the urinary bladder when it is fully distended for more thorough evaluation of the urinary bladder wall.

IMAGING PERFORMED BY

Diane McFadden

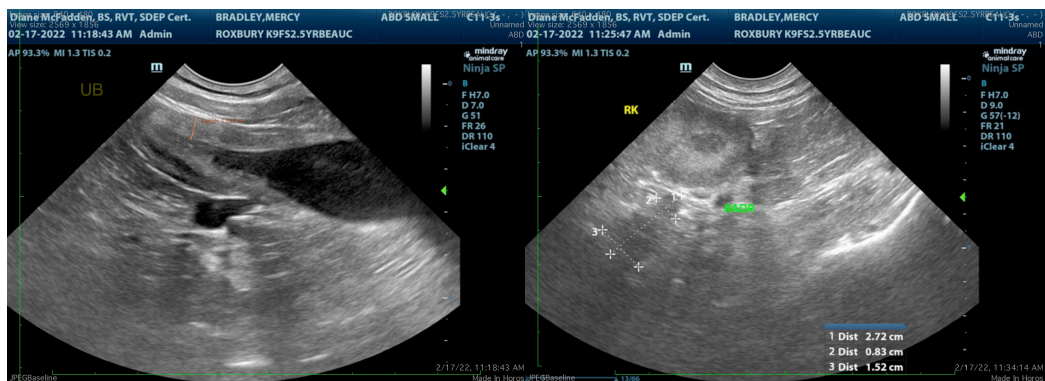
Therapeutic recommendations include beginning therapy for likely spay incontinence. If medical management does not improve clinical signs and/or clinical signs persist, a contrast abdominal CT scan could be considered to more definitively rule out ectopic ureters, no evidence of which is present in these images.

INTERPRETED BY

Beth Johnson, DVM
DACVIM

HOSPITAL NAME

AH of Roxbury



REFERRING VET

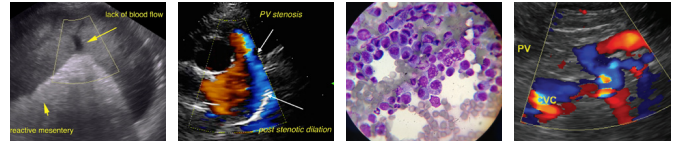
Dr. Elia

INVOICE

35719

DATE

2/17/22



PATIENT

Mercy Bradley

SPECIES

Canine

BREED

Beauceron

SEX

Spayed Female

AGE

2.5 Years

WEIGHT

74 Pounds

INTERPRETED BY

Beth Johnson, DVM
DACVIM

IMAGING PERFORMED BY

Diane McFadden

HOSPITAL NAME

AH of Roxbury

REFERRING VET

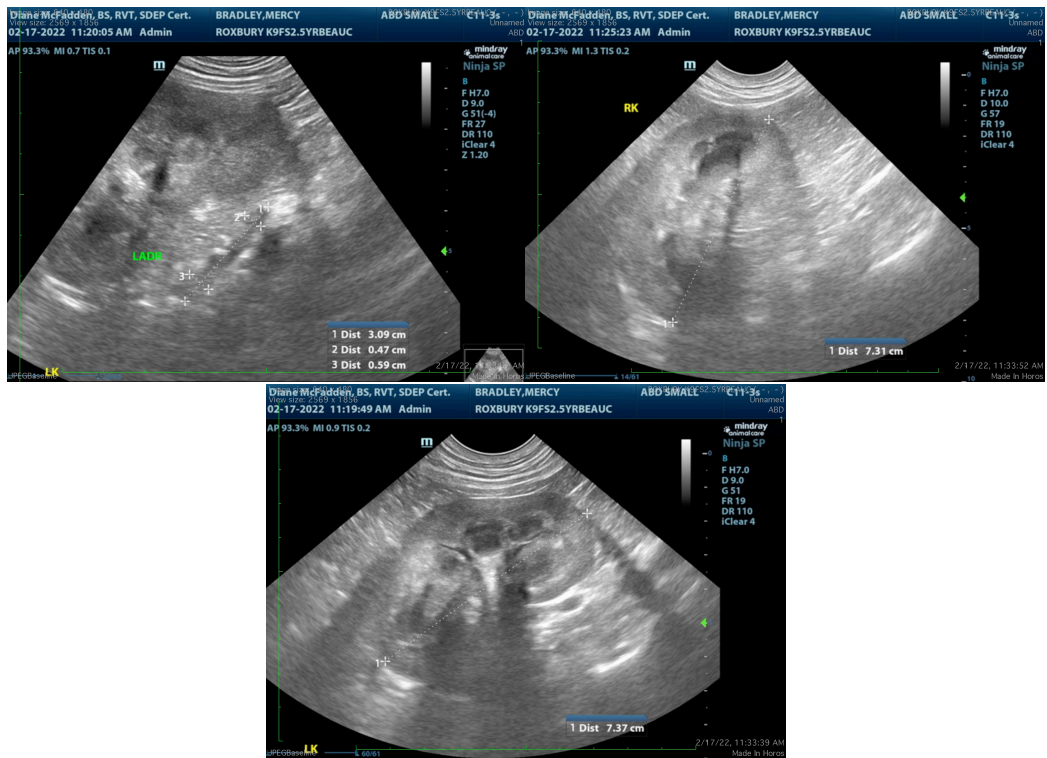
Dr. Elia

INVOICE

35719

DATE

2/17/22



The information and recommendations provided are based on the images presented by the referring veterinarian/sonographer. No evaluation can be communicated regarding pathology that was not visible in the image/video clips provided.

Thank you for this referral. If the clinical or image interpretation does not parallel your findings or if I can be of any further assistance please contact me.

Beth Johnson, DVM, DACVIM
Beth.Johnson@sonopath.com