

**DATE PRESENTING CLINICAL SIGNS**

2/16/23

PATIENT

June Schuster

June is usually very active, but for past 1-2 days has gotten more and more lethargic. Appetite also decreasing and only ate a few bites for dinner. Vomited once each day the past 2 days. Stool was soft earlier today. Does like to follow smaller dog around and often eats his feces. Owners haven't noticed excessive urination, but she does drink a very large volume whenever she drinks, but doesn't seem increased from normal. Has not had heartworm medication in about 6 months (owner didn't realize the flea/tick meds didn't also have HW.)

SPECIES

Canine

BREED

Labrador Retriever

Current Medications: None listed.
 Lab Results: Azotemia, Isosthenuria.
 Radiographs: Suspected mass in cranial abdomen; SI pushed to right side of abdominal cavity.
 Date of Previous IntraPet Ultrasound: No previous.
 Sedation: Not required to complete full diagnostic ultrasound.
 Stat Report: Not requested.
 Imaging Performed By: Andi Parkinson, BS, RDMS.

SEX

Spayed Female

ULTRASONOGRAPHIC EXAMINATION OF THE ABDOMEN**AGE**

3/18/15

WEIGHT

83.1 Pounds

INTERPRETED BYBeth Johnson, DVM
DACVIM**Urinary System**

Urinary bladder is adequately distended. It has a normal uniform wall thickness. Contents include primarily anechoic fluid with occasional echogenic non-shadowing debris, most consistent with exfoliated cells, mucous and/or small blood clots. Both sterile inflammation as well as urinary tract infection can also present with echogenic debris. No masses or cystoliths are observed. The trigone and visible pelvic urethra are normal in thickness with a smooth mucosal surface.

Kidneys are bilaterally uniformly enlarged/swollen with an overall hyperechoic echogenicity and slight loss of corticomedullary definition. Normal smooth peripheral margination and shape are maintained. The renal pelvises are dilated with anechoic fluid and hyperechoic thickened pelvic fat. No overt evidence of neoplasia or mineral is observed. The perinephric area is enhanced by hyperechoic fat and mesentery. The left kidney measured 7.37 cm. The right kidney measures 8.76 cm.

HOSPITAL NAMEAnimal Emergency
Hospital**Adrenal Glands**

The right adrenal gland is normal in size (3.31 cm long x 0.88 cm at the cranial pole and 0.87 cm at the caudal pole), shape and contour. Corticomedullary structure is unremarkable. Visible surrounding vasculature appears normal.

REFERRING VET

Dr. Martinoli

The left adrenal gland is normal in size (4.93 cm long x 1.15 cm at the cranial pole and 0.81 cm at the caudal pole), shape and contour. Corticomedullary structure is unremarkable. Visible surrounding vasculature appears normal.

INVOICE

45308

Spleen

The spleen is subjectively normal in size with a normal smooth capsular contour. Parenchyma is appropriately finely textured and homogenous with normal echogenicity relative to surrounding tissue (hyperechoic to liver). No focal nodules or masses are observed. Splenic vasculature appears normal.

Liver

The liver is subjectively normal in size with normal smooth curvilinear peripheral contour. Parenchyma is appropriately hypoechoic to the spleen in echogenicity and appropriately mildly coarse and homogenous in echotexture. No focal lesions are observed. Visible vasculature and biliary tree appear normal without distension or congestion.

Gallbladder is moderately distended with anechoic bile as well as mild suspended and gravity dependent echogenic debris. The wall is smooth without visible thickening. There is no evidence of cystic or CBD dilation. There is no evidence of effusion or inflammation.

Gastrointestinal

The stomach wall is normal in thickness (canine < 0.5 cm and feline < 0.4 cm) and layering. The lumen of the stomach is moderately fluid distended with no evidence of obstruction, foreign material or infiltrative disease. Pyloric outflow tract appears patent.

The visible small intestine demonstrates areas of mildly thick muscularis layer relative to mucosa (disruption of the normal 1:3 muscularis:mucosa ratio). Small intestinal submucosa is slightly irregular, thick and hyperechoic, without evident loss of layering appreciated. The lumen is empty with no evidence of obstruction or foreign material.

The visible colon is normal in wall thickness (< 0.2 cm) and layering. Contents are consistent with normal formed feces and gas.

Pancreas

Pancreas is prominent (enlarged) in size and mildly irregular in shape with a slightly undulating contour. Parenchyma is coarse in echotexture and heterogenous to hypoechoic in echogenicity.

Free Abdomen

There is a scant amount of anechoic free fluid noted, primarily around the left kidney.

Prominent cystic sublumbar lymphadenopathy is noted.

PRIMARY FINDINGS

- **Pyelonephritis** – These changes are most consistent with chronic pyelonephritis. Chronic scarring and fibrosis and/or chronic nephrolith passage can also result in these pelvic dilation changes. Early infiltrative disease cannot be ruled out but is considered less likely.
- **Mild inflammatory bowel disease (IBD) pattern** – Thick muscularis has been reported with infiltrative bowel disease including both benign inflammatory disease as well as infiltrative neoplasia such as lymphoma. No aggressive lymphadenopathy, loss of layering, etc. is noted to make lymphoma more probable, but lymphoma cannot be definitively ruled out without tissue sampling.
- Chronic active pancreatitis
- Prominent cystic sublumbar lymphadenopathy – likely a reactive change secondary to chronic infections, possibly of the urinary tract. However, other reactive source and/or even infiltrative neoplasia cannot be ruled out.

SECONDARY FINDINGS

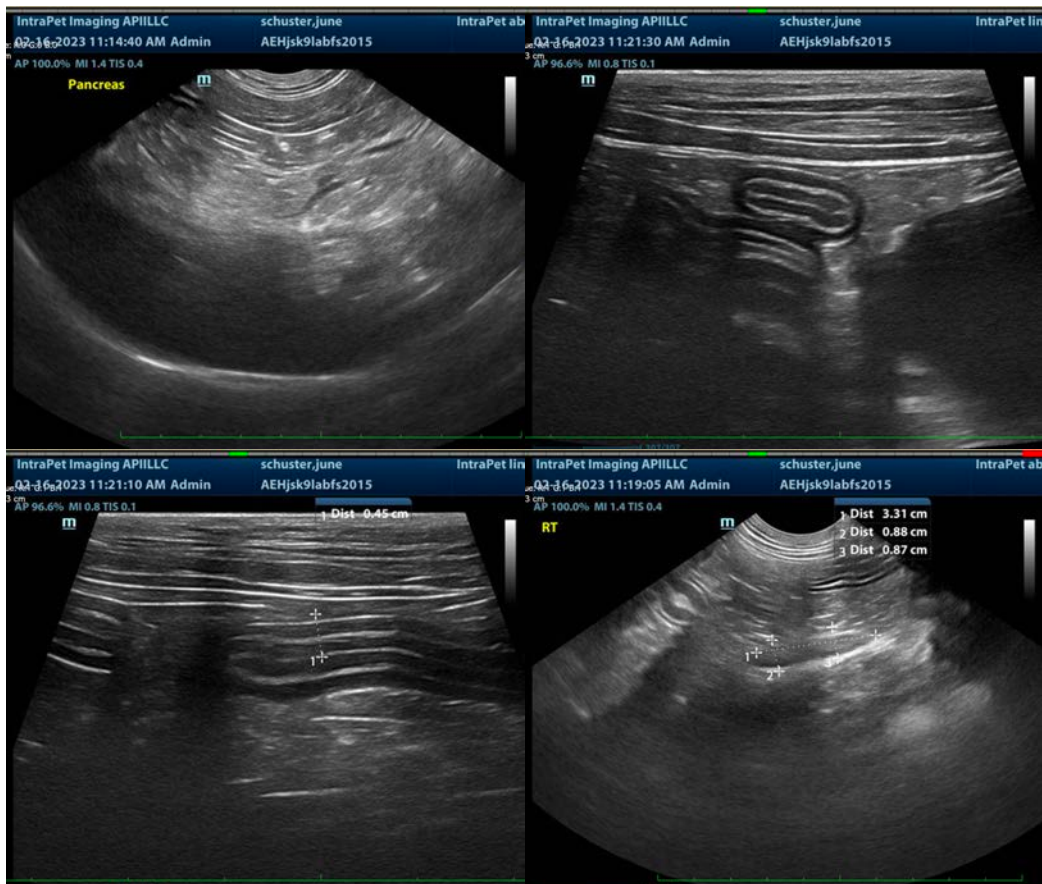
- **Mild gallbladder debris** - Cholecystic debris is of unknown clinical significance. It can be seen with biliary stasis from fasting or illness. Cholecystic debris is not necessarily related to hepatobiliary disease. Echogenic bile is most commonly an incidental finding in dogs and should be interpreted in combination with clinical signs such as nausea, inappetence, cranial abdominal discomfort and/or laboratory changes such as increased ALP and/or increased Tbili.
- Urinary bladder debris

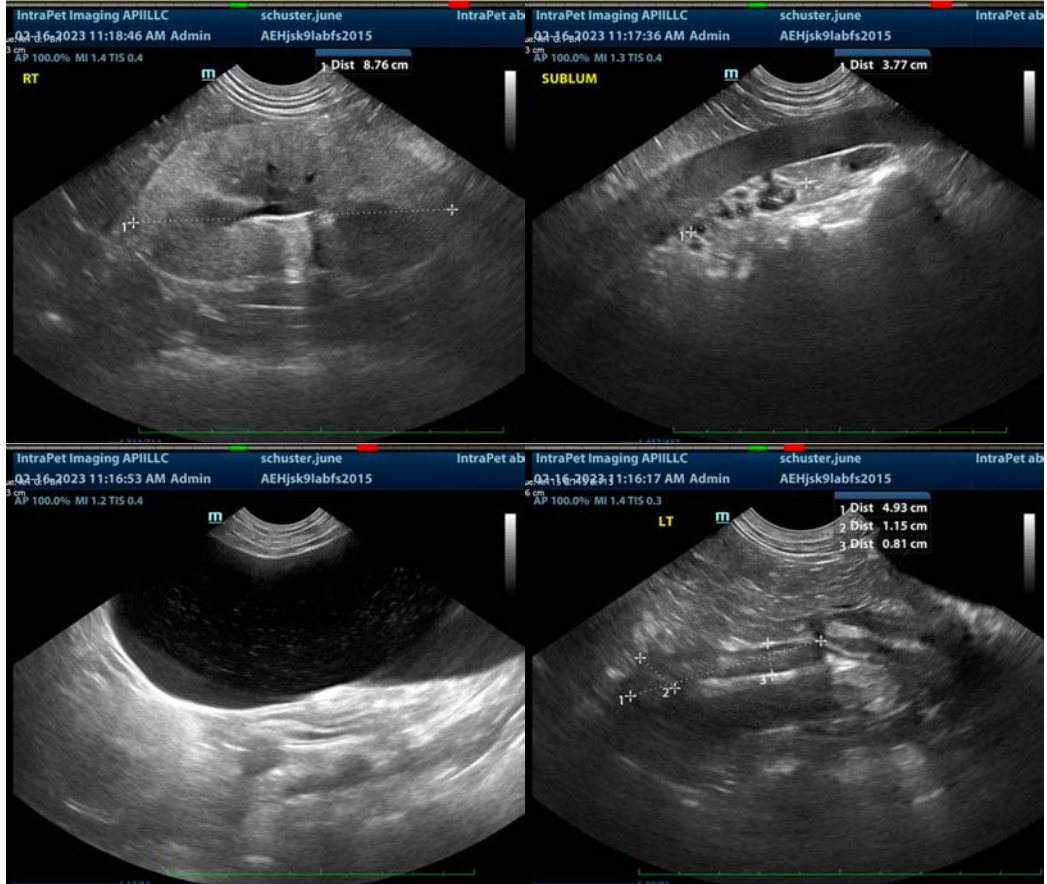
INTERPRETATION OF THE FINDINGS & FURTHER RECOMMENDATIONS

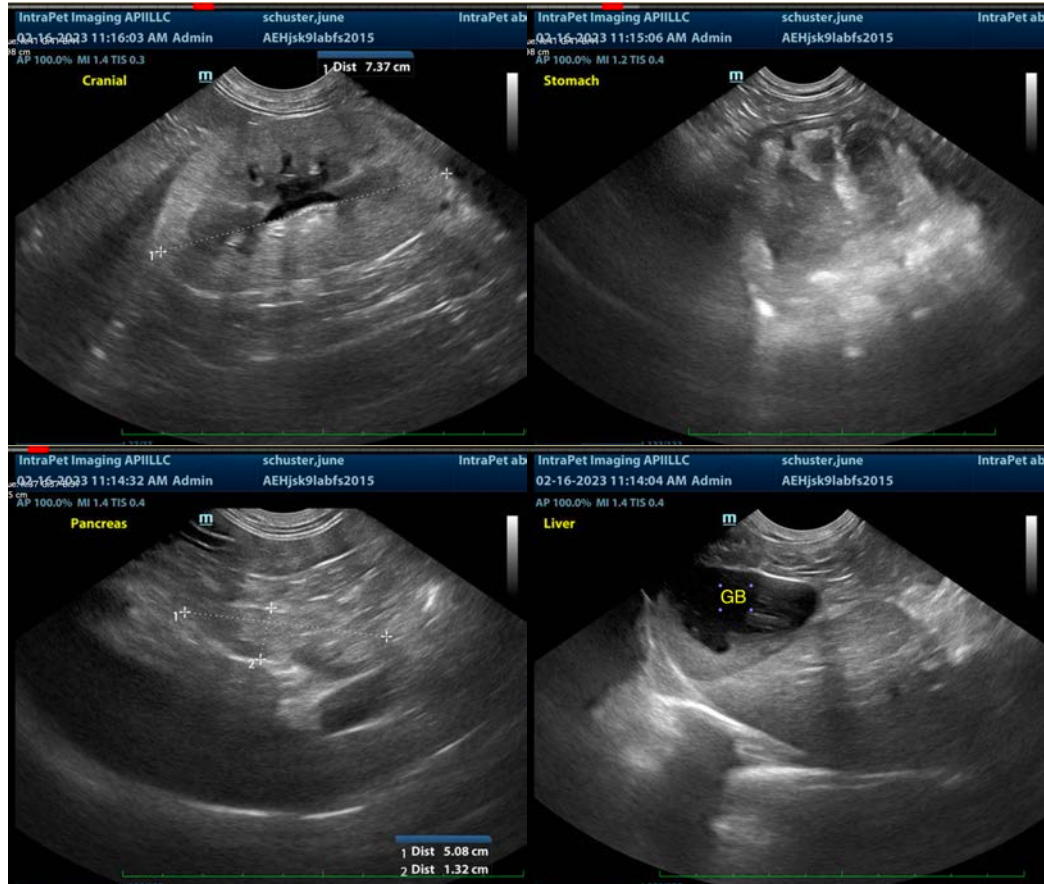
The primary finding, especially given this patient's reported azotemia and isosthenuria is the suspected pyelonephritis in this patient, which is believed to be the most likely contributing factor to the patient's clinical signs. If not already evaluated, a urine culture is recommended. Additionally, testing for Leptospirosis should be considered.

If gastrointestinal signs don't resolve with management of the pyelonephritis, and/or if there is any chronicity to gastrointestinal signs in this patient, a gastrointestinal malabsorption panel (including cobalamin, folate, TLI and PLI) to Texas A&M GI Laboratory is recommended for further evaluation of GI and pancreatic function.

In the meantime, supportive/symptomatic medical management of suspected pyelonephritis and the concurrent gastrointestinal signs is recommended with diuresis, broad-spectrum antibiotics, antiemetics, gastroprotectants, appetite stimulant if necessary, etc.







The information and recommendations provided are based on the images presented by the referring veterinarian/sonographer. No evaluation can be communicated regarding pathology that was not visible in the image/video clips provided.

Thank you for this referral. If the clinical or image interpretation does not parallel your findings or if I can be of any further assistance please contact me.

Beth Johnson, DVM, DACVIM
Beth.Johnson@sonopath.com