

**DATE PRESENTING CLINICAL SIGNS**

2/15/23 Weight loss, vomiting starting yesterday.

PATIENT

Ruby Pearson Current Medications: None listed.
Radiographs: Enlarged spleen.
Date of Previous IntraPet Ultrasound: No previous.
Sedation: Not required to complete full diagnostic ultrasound.
Stat Report: Not requested.

SPECIES

Canine

Imaging Performed By: Rachel Brillhart, RDMS.

ULTRASONOGRAPHIC EXAMINATION OF THE ABDOMEN**BREED**

Mixed

Urinary System

The urinary bladder is moderately distended with anechoic contents. No masses, inflammatory changes, echogenic sediment or cystoliths are observed. The urinary bladder, trigone and visible pelvic urethra are normal in thickness with a smooth mucosal surface.

SEX

Spayed Female

The right kidney is normal in size (6.55 cm), shape and echogenicity. It has smooth peripheral margination. There is a normal 1:3 cortex to medulla ratio with appropriate corticomedullary distinction. There is no evidence of pyelectasia, mineral or infarcts observed.

AGE

11/17/12

The left kidney is normal in size (5.83 cm), shape and echogenicity. It has smooth peripheral margination. There is a normal 1:3 cortex to medulla ratio with appropriate corticomedullary distinction. There is no evidence of pyelectasia, mineral or infarcts observed.

WEIGHT

51.1 Pounds

Adrenal Glands

The right adrenal gland is normal in size (2.41 cm long x 0.82 cm at the cranial pole and 0.77 cm at the caudal pole), shape and contour. Corticomedullary structure is unremarkable. Visible surrounding vasculature appears normal.

INTERPRETED BY

Beth Johnson, DVM
DACVIM

The left adrenal gland is normal in size (2.77 cm long x 0.71 cm at the cranial pole and 0.64 cm at the caudal pole), shape and contour. Corticomedullary structure is unremarkable. Visible surrounding vasculature appears normal.

HOSPITAL NAME

Paradise AH

Spleen

Spleen is subjectively large in size with a mildly swollen but smooth capsule. Parenchyma is normal and homogenous in echogenicity and echotexture. No focal nodules or masses are observed. Splenic vasculature appears normal.

REFERRING VET

Dr. Pearson

Liver

The liver is subjectively normal in size with normal smooth curvilinear peripheral contour. Parenchyma is appropriately hypoechoic to the spleen in echogenicity and appropriately mildly coarse and homogenous in echotexture. No focal lesions are observed. Visible vasculature and biliary tree appear normal without distension or congestion.

INVOICE

45163

The gallbladder is non-distended in size. The wall is smooth without visible thickening. Luminal contents are primarily anechoic. There is no evidence of cystic or common bile duct dilation.

Gastrointestinal

Diffusely, the stomach wall is normal in thickness, but near the upper limits of normal thickness to slightly thick in some views, measuring 0.70 cm thick maximally. Layering is normal and intact. The lumen of the stomach is mildly distended with very echogenic reverberation artifact from intraluminal gas. There is no

evidence of obstruction, foreign material or infiltrative disease; however, complete visualization of far wall is partially inhibited by gas. Pyloric outflow tract appears patent.

The visible small intestines are normal in wall thickness and layering (canine duodenum < 0.5 cm and feline duodenum < 0.4 cm; other < 0.3 cm). Small intestinal motility appears adequate (1-3 contractions per min). The lumen of the small intestine is empty with no evidence of obstruction, foreign material or infiltrative disease.

The visible colon is normal in wall thickness (< 0.2 cm) and layering. Contents are consistent with normal formed feces and gas.

Pancreas

The pancreatic parenchyma is appropriately isoechoic to surrounding tissue. Visible capsule is smooth and normal in contour. There is no visible pancreatic duct dilation. There is no evidence of active peripancreatic inflammation.

Free Abdomen

There is no evidence of free peritoneal effusion noted in these images.

There is no apparent lymphadenopathy noted in these images.

There is no evidence of heart base or pericardial pathology noted in these images. If cardiac function evaluation is desired, a full echocardiogram is recommended.

ULTRASONOGRAPHIC FINDINGS

- **Hypersplenism** – can be associated with congestion caused by sedation (if sedated) but can also be associated with diffuse infiltrative disease. Both benign conditions such as extramedullary hematopoiesis, lymphoid hyperplasia, as well as infiltrative neoplastic diseases such as round cell neoplasia should be considered.
- **Possible mild diffuse gastric wall thickening** – potentially secondary to infiltrative infectious, parasitic, inflammatory disease, etc. Infiltrative neoplasia is considered much less likely. Given the mild change, normal patient variant, prominent rugal folds, mild gastritis, etc. are also possible.

INTERPRETATION OF THE FINDINGS & FURTHER RECOMMENDATIONS

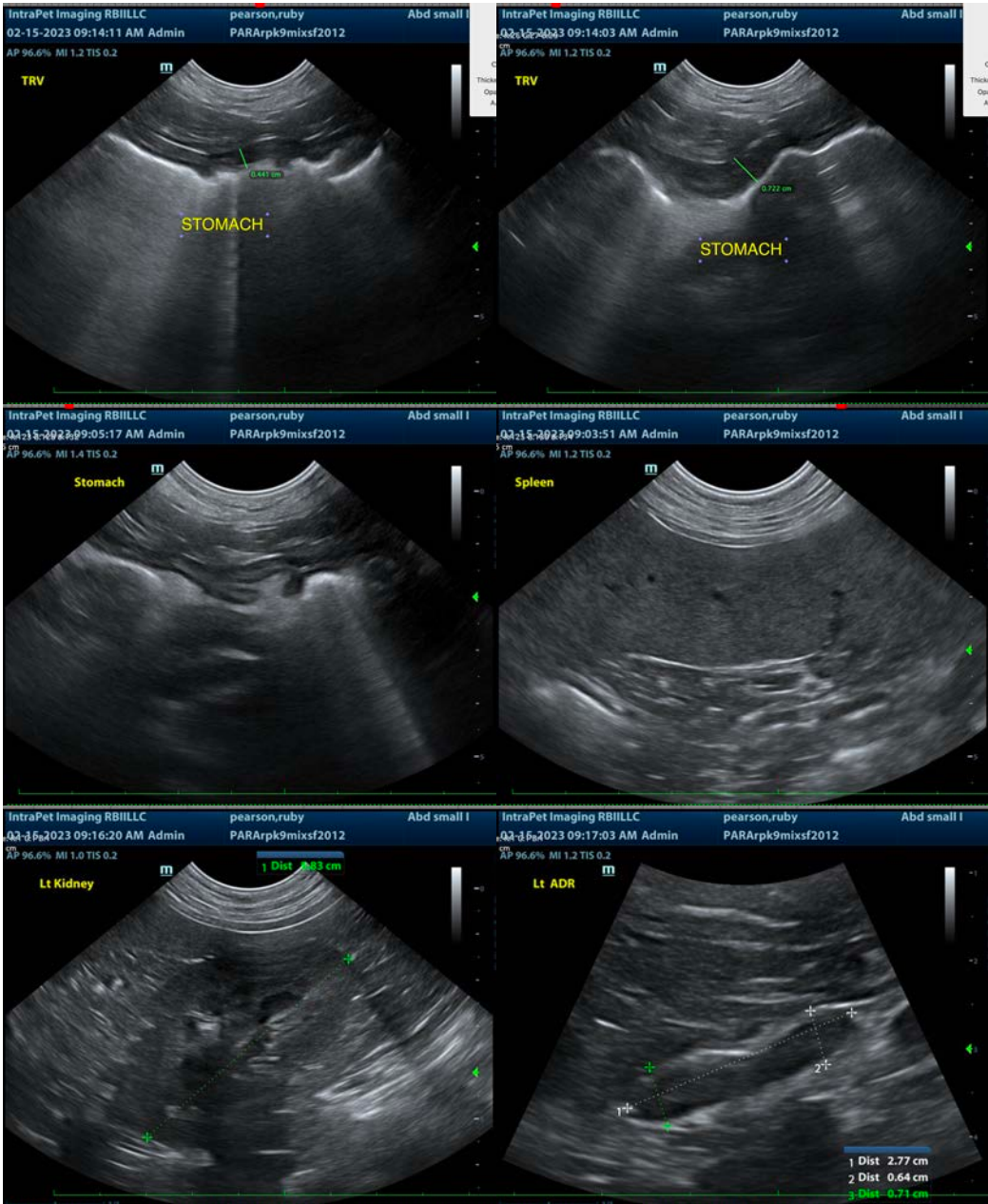
If not recently evaluated, a general metabolic health screen is recommended in the form of CBC/Chem panel, electrolytes, a urinalysis and, if indicated based on urinalysis results, urine culture. If protein is present in an otherwise quiet sediment, protein quantification with a urine protein to creatinine ration is recommended.

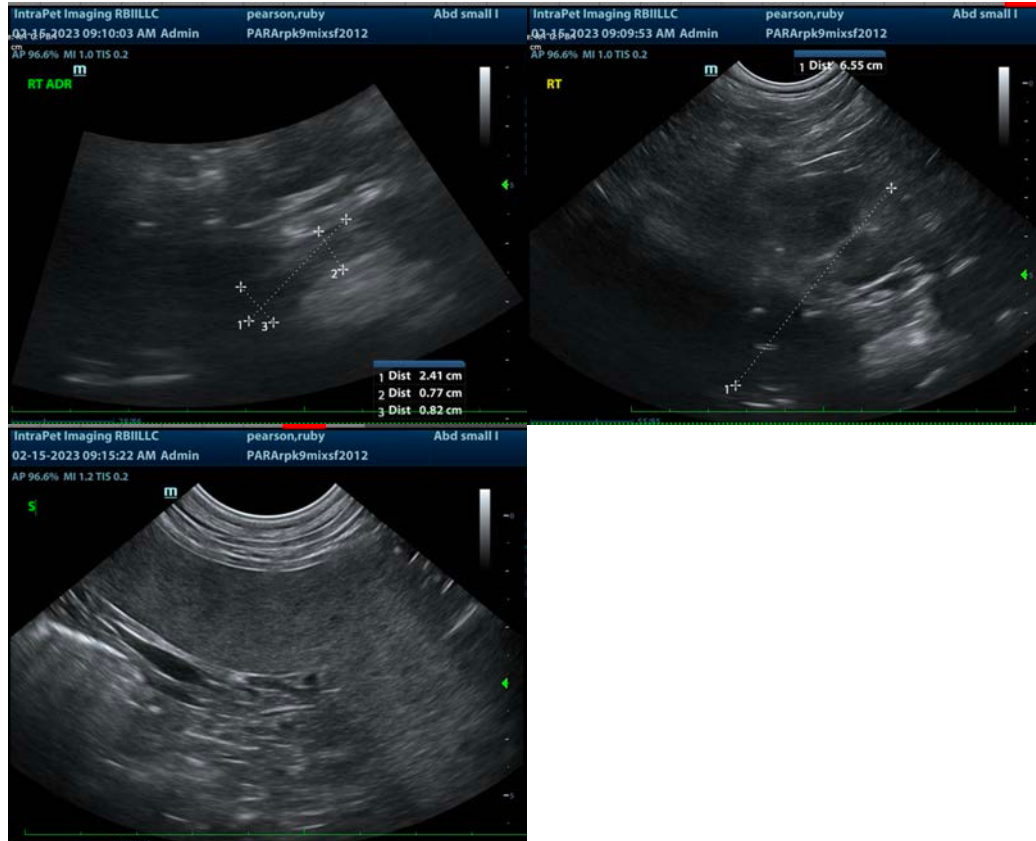
A fine needle aspirate of the spleen is recommended if patient's coagulation status is appropriate.

Pending those results, consider a GI panel to Texas A&M for evaluation of B12 levels, folate, PLI/TLI etc.. to further evaluate for pancreatic/small intestinal disease.

In the meantime, supportive/symptomatic medical management of the vomiting/possible mild gastritis is recommended with antiemetics, gastroprotectants, empirical deworming with a 5-day course of Panacur, and transition in diet based on trial and error response, potentially beginning with a bland, easy to digest diet or proceeding to a hydrolyzed protein diet, etc.

Ultimately, if a diagnosis isn't made and clinical signs persist, either recheck imaging of the stomach is recommended, or potentially upper GI gastroscopy/endoscopy for further evaluation as well as biopsies could be considered.





The information and recommendations provided are based on the images presented by the referring veterinarian/sonographer. No evaluation can be communicated regarding pathology that was not visible in the image/video clips provided.

Thank you for this referral. If the clinical or image interpretation does not parallel your findings or if I can be of any further assistance please contact me.

Beth Johnson, DVM, DACVIM
Beth.Johnson@sonopath.com