



PATIENT

Ginger Ellis

SPECIES

Feline

BREED

DSH

SEX

Spayed Female

AGE

14.5 Years

WEIGHT

6.5 Pounds

INTERPRETED BY

Beth Johnson, DVM
DACVIM

IMAGING PERFORMED BY

Dr. Tam Mengine

HOSPITAL NAME

Stoney Creek VH

REFERRING VET

Dr. Tam Mengine

INVOICE

35656

DATE

2/15/22

PRESENTING CLINICAL SIGNS

One month of frequent vomiting and 0.5# pound wt loss. Good appetite. Prior hx of renal dz (creat 2.5) - rechecked when vomiting started, creat progressed to 3.1, U/A unremarkable including UPC, except SpGr 1.016. Otherwise normal CBC/ Chem / T4 / U/A

ULTRASONOGRAPHIC EXAMINATION OF THE ABDOMEN

Urinary System

The urinary bladder is moderately distended with anechoic contents. No masses, inflammatory changes, echogenic sediment or cystoliths are observed. The urinary bladder, trigone and visible pelvic urethra are normal in thickness with a smooth mucosal surface.

The left kidney is normal in size, irregular and diffusely echogenic with decreased corticomedullary distinction and poor visualization of internal architecture. There is no pyelectasia noted and no mineral is observed. The left kidney measures 3.05 cm.

The right kidney is lower limits of normal size, and irregular and diffusely echogenic with decreased corticomedullary distinction and poor visualization of internal architecture. There is no pyelectasia noted and no mineral is observed. The right kidney measures 2.67 cm.

Adrenal Glands

The right adrenal gland is normal in size (0.32 cm at the cranial pole and 0.29 cm at the caudal pole), shape and contour. Corticomedullary structure is unremarkable. Visible surrounding vasculature appears normal.

The left adrenal gland is normal in size (0.40 cm at the cranial pole and 0.30 cm at the caudal pole), shape and contour. Corticomedullary structure is unremarkable. Visible surrounding vasculature appears normal.

Spleen

The spleen is subjectively normal in size with a normal smooth capsular contour. Parenchyma is appropriately finely textured and homogenous with normal echogenicity relative to surrounding tissue (hyperechoic to liver). No focal nodules or masses are observed. Splenic vasculature appears normal.

Liver

The liver is subjectively normal in size with normal smooth curvilinear peripheral contour. Parenchyma is appropriately hypoechoic to the spleen in echogenicity and appropriately mildly coarse and homogenous in echotexture. No focal lesions are observed. Visible vasculature and biliary tree appear normal without distension or congestion.

The gallbladder is non-distended in size. The wall is smooth without visible thickening. Luminal contents are primarily anechoic. There is no evidence of cystic or common bile duct dilation.

Gastrointestinal

The stomach wall is normal in thickness (canine < 0.5 cm and feline < 0.4 cm) and layering. The lumen of the stomach is empty with no evidence of obstruction, foreign material or infiltrative disease. Pyloric outflow tract appears patent.

The visible small intestines are normal in wall thickness. Normal layering is maintained except for a diffusely disproportionately thick muscularis layer relative to mucosa. Small intestinal motility appears



PATIENT

Ginger Ellis

adequate (1-3 contractions per min). The lumen of the small intestine is empty with no evidence of obstruction, foreign material or infiltrative disease.

The visible colon is normal in wall thickness (< 0.2 cm) and layering. Contents are consistent with normal formed feces and gas.

SPECIES

Feline

Pancreas

The pancreas is visible, characterized by hypoechoic parenchyma relative to surrounding tissue. The visible capsule is smooth and normal in contour. There is no visible pancreatic duct dilation. There is mild hyperechoic surrounding mesentery and fat. No free fluid.

BREED

DSH

Free Abdomen

There is no evidence of peritoneal effusion. Jejunal/mesenteric lymph nodes are present and hypoechoic, but maintain normal shape. Subjectively the mesentery is diffusely mildly hyperechoic compared to surrounding organs.

SEX

Spayed Female

ULTRASONOGRAPHIC FINDINGS

AGE

14.5 Years

- Thick muscularis with likely reactive mesenteric lymphadenopathy – This finding has been reported in cats with infiltrative bowel disease including both benign inflammatory disease as well as infiltrative neoplasia such as lymphoma. Infiltrative neoplasia causing lymphadenopathy cannot be ruled out, but is considered less likely.

WEIGHT

6.5 Pounds

- Prominent, hypoechoic pancreas with some subjective evidence of mild inflammation – Rule outs include mild acute or acute on chronic or acute resolving pancreatitis versus chronic low-grade smoldering pancreatitis. The diffusely hyperechoic mesentery further supports some mild ongoing pancreatitis or potentially diffuse gastroenteritis.

INTERPRETED BY

Beth Johnson, DVM
DACVIM

- Chronic Kidney Disease - This appearance of the kidneys is consistent with chronic kidney disease such as chronic glomerular or interstitial nephritis, chronic pyelonephritis, etc.

INTERPRETATION OF THE FINDINGS & FURTHER RECOMMENDATIONS

IMAGING PERFORMED BY

Dr. Tam Mengine

Given the weight loss with a good appetite combined with the pancreatic and mesenteric changes, recommendations include a gastrointestinal malabsorption panel to include TLI, PLI, folate and cobalamin to Texas A&M GI laboratory for further assessment of gastrointestinal function as well as the pancreas. A T4 and free T4 are also recommended, given the weight loss in the face of a good appetite, if not recently evaluated.

HOSPITAL NAME

Stoney Creek VH

Ultimately, biopsies of the gastrointestinal tract may be necessary to definitively diagnosis and therefore appropriately manage suspected infiltrative bowel disease. If biopsies are not pursued, empirical therapies with a transition to a novel or hydrolyzed protein diet combined with empirical cobalamin supplementation +/- steroids may help alleviate ongoing weight loss and clinical signs, unless hyperthyroidism is concurrently diagnosed.

REFERRING VET

Dr. Tam Mengine

If medical management is implemented and clinical signs persist, recheck ultrasound would be recommended to monitor the mesenteric changes for progression, such as clumped mesentery, the development of free fluid, etc., that may indicate a more serious infiltrative disease.

INVOICE

35656

DATE

2/15/22



PATIENT

Ginger Ellis

SPECIES

Feline

BREED

DSH

SEX

Spayed Female

AGE

14.5 Years

WEIGHT

6.5 Pounds

INTERPRETED BY

Beth Johnson, DVM
DACVIM

IMAGING PERFORMED BY

Dr. Tam Mengine

HOSPITAL NAME

Stoney Creek VH

REFERRING VET

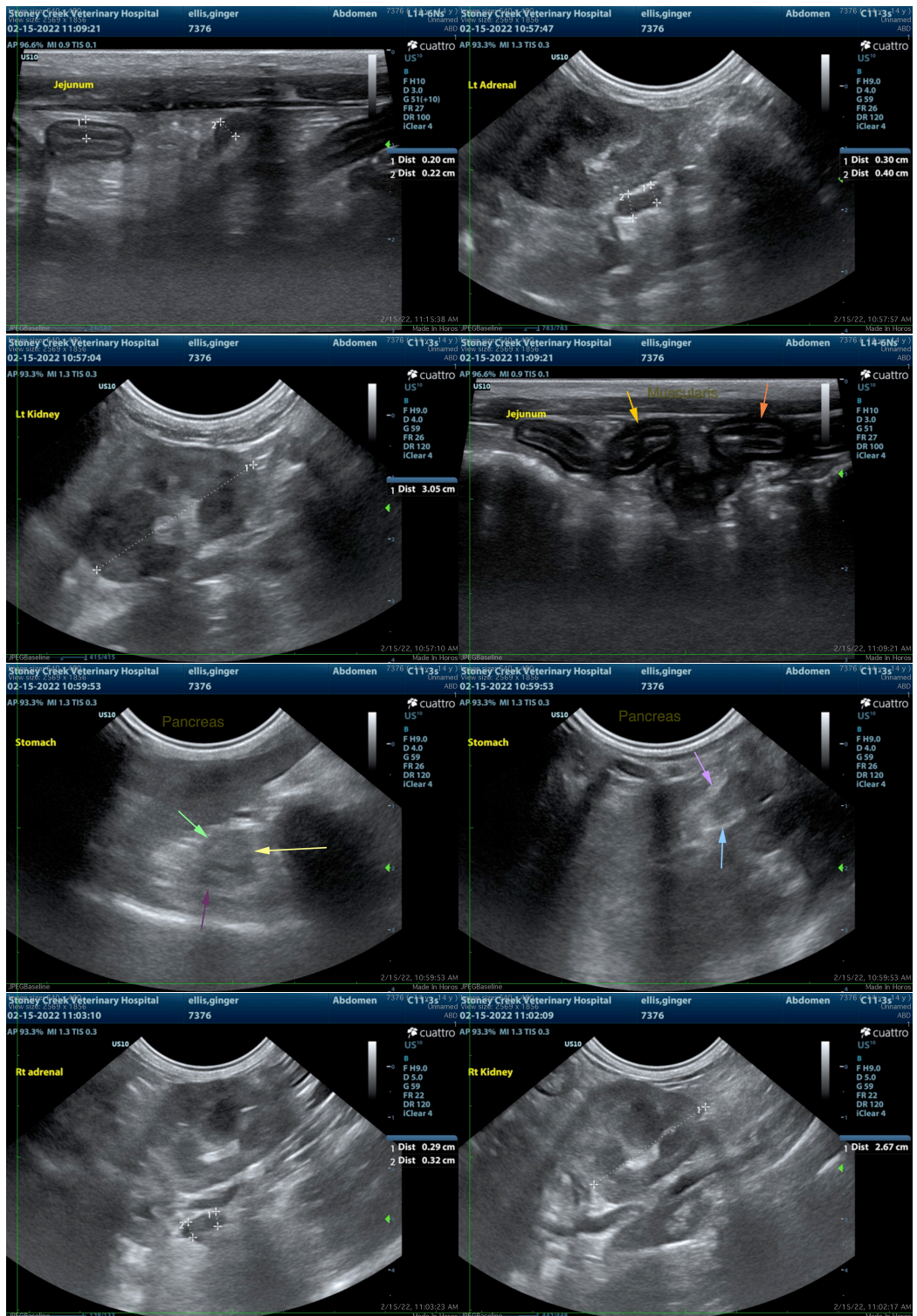
Dr. Tam Mengine

INVOICE

35656

DATE

2/15/22





PATIENT

Ginger Ellis

SPECIES

Feline

BREED

DSH

SEX

Spayed Female

AGE

14.5 Years

WEIGHT

6.5 Pounds

INTERPRETED BY

Beth Johnson, DVM
DACVIM

IMAGING PERFORMED BY

Dr. Tam Mengine

HOSPITAL NAME

Stoney Creek VH

REFERRING VET

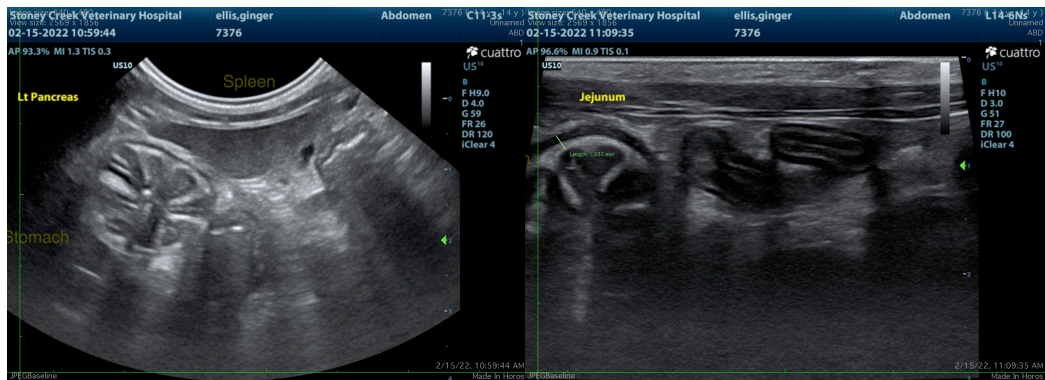
Dr. Tam Mengine

INVOICE

35656

DATE

2/15/22



The information and recommendations provided are based on the images presented by the referring veterinarian/sonographer. No evaluation can be communicated regarding pathology that was not visible in the image/video clips provided.

Thank you for this referral. If the clinical or image interpretation does not parallel your findings or if I can be of any further assistance please contact me.

Beth Johnson, DVM, DACVIM
Beth.Johnson@sonopath.com