



PATIENT

Daisy Rothwell

SPECIES

Canine

BREED

Goldendoodle

SEX

Spayed Female

AGE

12 Years 3 Months

WEIGHT

18.5 kg

INTERPRETED BY

Beth Johnson, DVM
DACVIM

IMAGING PERFORMED BY

Dr. Brian Barnes

HOSPITAL NAME

Westview VH

REFERRING VET

Dr. Brian Barnes

INVOICE

35677

DATE

2/15/22

PRESENTING CLINICAL SIGNS

Vomiting 2-3 times weekly becoming more frequent and now has poor appetite. Abnormal PE/Chem/CBC/UA Results: CBC: Lymp 0.8 (N 1.1-5.0) CHEM: CK 483 (N 10-200) SDMA 11 (N 0-14), TT4 30.1 (N 13-53) Cardiopet BNP 859 (N 0-900) U/A: Free catch, Dark yellow, cloudy, USG 1.046, pH 7.5, Pro 1+, Glu/ Ket/ bld/ bili/ negative, Ubg Normal, SEDI: WBC 2-5/HPF, RBC 0, BAc 0, Crystals 0 Xrays; 1. Normal thorax 2. Unexpected gas and fluid accumulation in the stomach and small intestine with slight gastric and small intestinal distention. Although this may be a transient gas and fluid accumulation of no significance, in a patient with a clinical history of gastrointestinal disease my primary consideration is that this is a significant finding. Rule out inflammatory enteric disease such as gastroenteritis, chronic pancreatic disease, gastric ulceration, inflammatory bowel disease, etc. 3. A surgical abdominal cause for the clinical history of chronic gastrointestinal signs is not identified. Recommendations 1. An indication for additional imaging of the thorax is not identified 2. Although a definitive indication for additional imaging of this abdomen is not identified, abdominal ultrasound may be of value to further characterize the changes identified in the small intestine on this study and further exclude the possibility of enteric or abdominal abnormalities which might not be appreciated radiographically.

ULTRASONOGRAPHIC EXAMINATION OF THE ABDOMEN

Urinary System

The urinary bladder is moderately distended with anechoic contents. No masses, inflammatory changes, echogenic sediment or cystoliths are observed. The urinary bladder, trigone and visible pelvic urethra are normal in thickness with a smooth mucosal surface.

The right kidney is normal in size (5.91 cm), shape and echogenicity. It has smooth peripheral margination. There is a normal 1:3 cortex to medulla ratio with appropriate corticomedullary distinction. There is no evidence of pyelectasia, mineral or infarcts observed.

The left kidney is normal in size (5.3 cm), shape and echogenicity. It has smooth peripheral margination. There is a normal 1:3 cortex to medulla ratio with appropriate corticomedullary distinction. There is no evidence of pyelectasia, mineral or infarcts observed.

Adrenal Glands

The right adrenal gland is normal in size (2.86 cm long x 0.53 cm at the cranial pole and 0.72 cm at the caudal pole), shape and contour. Corticomedullary structure is unremarkable. Visible surrounding vasculature appears normal.

The left adrenal gland is normal in size (2.18 cm long x 0.82 cm at the cranial pole and 0.64 cm at the caudal pole), shape and contour. Corticomedullary structure is unremarkable. Visible surrounding vasculature appears normal.

Spleen

The spleen is subjectively large in size with a nodular parenchyma characterized by multifocal poorly defined, hypoechoic to anechoic nodules of varying sizes that do not appear to disrupt the splenic capsule. Splenic vasculature appears normal.

Liver

The liver is subjectively normal in size with normal smooth curvilinear peripheral contour. Parenchyma is appropriately hypoechoic to the spleen in echogenicity and appropriately mildly coarse and homogenous in echotexture. No focal lesions are observed. Visible vasculature and biliary tree appear normal without distension or congestion.



PATIENT	GB is moderately distended with anechoic bile and gravity dependent echogenic sediment. The wall is smooth without visible thickening. There is no evidence of cystic or CBD dilation. There is no evidence of effusion or inflammation.
Daisy Rothwell	
SPECIES	Gastrointestinal
Canine	The stomach wall is increased in thickness, measuring 1.1 cm thick. Layering is maintained. However, the stomach is overall heterogeneous and more hypochoic than normal. The stomach lumen is empty.
BREED	The visible small intestines are normal in wall thickness and layering (canine duodenum < 0.5 cm and feline duodenum < 0.4 cm; other < 0.3 cm). Small intestinal motility appears adequate (1-3 contractions per min). The lumen of the small intestine is empty with no evidence of obstruction, foreign material or infiltrative disease.
Goldendoodle	
SEX	The visible colon is normal in wall thickness (< 0.2 cm) and layering. Contents are consistent with normal formed feces and gas.
Spayed Female	
AGE	Pancreas
12 Years 3 Months	The pancreatic parenchyma is appropriately isoechoic to surrounding tissue. Visible capsule is smooth and normal in contour. There is no visible pancreatic duct dilation. There is no evidence of active peripancreatic inflammation.
WEIGHT	Free Abdomen
18.5 kg	There is no evidence of peritoneal effusion.
INTERPRETED BY	There is a 2.0 cm round, hypochoic structure in the mid cranial abdomen, believed to be an enlarged lymph node.
Beth Johnson, DVM DACVIM	ULTRASONOGRAPHIC FINDINGS
IMAGING PERFORMED BY	<ul style="list-style-type: none"> Nodular spleen – Most concerning for infiltrative neoplasia such as round cell neoplasia, especially given the concurrent lymphadenopathy. Benign lesions such as hematomas, nodular hyperplasia, or extramedullary hematopoiesis can't be ruled out, but is considered much less likely. Cranial abdominal lymphadenopathy – Most concerning for infiltrative neoplasia as well. Thick, slightly heterogeneous gastric wall – This could be an acute gastritis/inflammatory change secondary to disease elsewhere, such as might be seen with mast cell tumor. However, infiltrative neoplasia also involving the gastric wall, while considered less likely, cannot be ruled. Gallbladder debris - Cholecystic debris is of unknown clinical significance. It can be seen with biliary stasis from fasting or illness. Cholecystic debris is not necessarily related to hepatobiliary disease. Echogenic bile is most commonly an incidental finding in dogs and should be interpreted in combination with clinical signs such as nausea, inappetence, cranial abdominal discomfort and/or laboratory changes such as increased ALP and/or increased Tbili.
Dr. Brian Barnes	
HOSPITAL NAME	
Westview VH	
REFERRING VET	
Dr. Brian Barnes	
INVOICE	INTERPRETATION OF THE FINDINGS & FURTHER RECOMMENDATIONS
35677	Recommendations include fine needle aspirate of the spleen for cytology, as is reportedly already pending. Other recommendations include 3-view thoracic radiographs to further assess for metastatic, which were reportedly recently evaluated. In the meantime, therapeutic recommendations surround the clinical signs of vomiting and decreased appetite, and include antiemetics, antacids, and sucralfate to manage gastritis +/- microulceration.
DATE	
2/15/22	



PATIENT

Daisy Rothwell

SPECIES

Canine

BREED

Goldendoodle

SEX

Spayed Female

AGE

12 Years 3 Months

WEIGHT

18.5 kg

INTERPRETED BY

Beth Johnson, DVM
DACVIM

IMAGING PERFORMED BY

Dr. Brian Barnes

HOSPITAL NAME

Westview VH

REFERRING VET

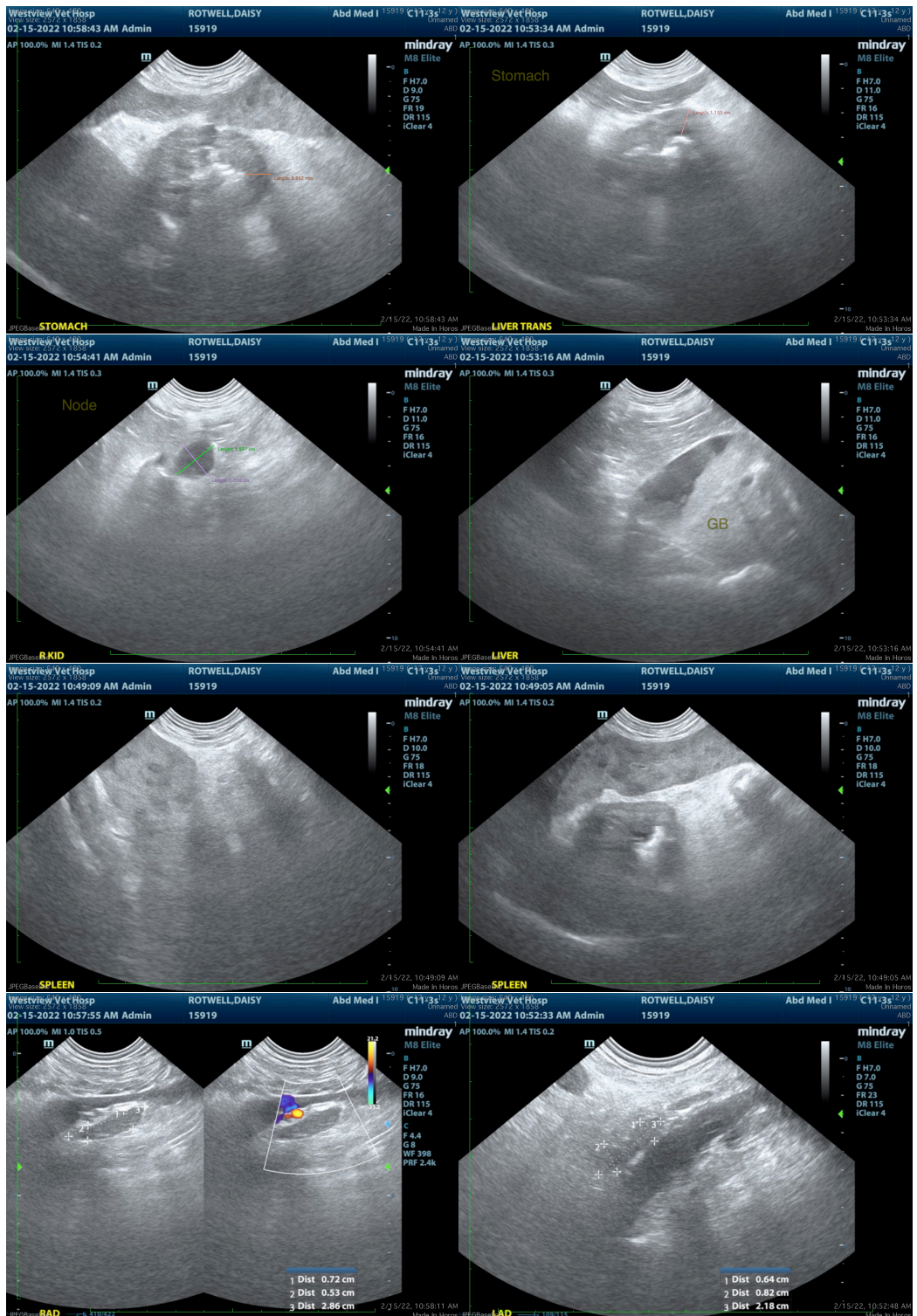
Dr. Brian Barnes

INVOICE

35677

DATE

2/15/22





PATIENT

Daisy Rothwell

SPECIES

Canine

BREED

Goldendoodle

SEX

Spayed Female

AGE

12 Years 3 Months

WEIGHT

18.5 kg

INTERPRETED BY

Beth Johnson, DVM
DACVIM

IMAGING PERFORMED BY

Dr. Brian Barnes

HOSPITAL NAME

Westview VH

REFERRING VET

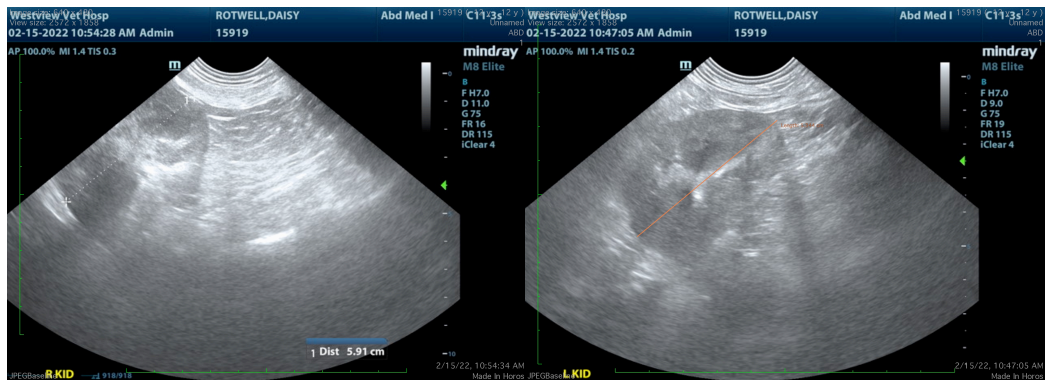
Dr. Brian Barnes

INVOICE

35677

DATE

2/15/22



The information and recommendations provided are based on the images presented by the referring veterinarian/sonographer. No evaluation can be communicated regarding pathology that was not visible in the image/video clips provided.

Thank you for this referral. If the clinical or image interpretation does not parallel your findings or if I can be of any further assistance please contact me.

Beth Johnson, DVM, DACVIM
Beth.Johnson@sonopath.com