

**DATE**

2/15/22

**PRESENTING CLINICAL SIGNS**

History: December 2021 - poor appetite has not improved. December 2017 - Liver enzymes, weight loss, not seen here; weight relatively stable, other recovery say 16 weight loss. Seen by specialist - concern liver shunt. Current Medications: Denamarin 1 SID since 2017, Entyce (0.9ml SID sept 2020) (0.75ml SID 12/2021), Lactulose 0.75 TID on 1/28/22 Hill's L/D and K/D diets since Jan 2018.

**PATIENT**

Daisy Englehart

Lab Results: Attached separately. Elevated bile acids - me 223 post-116 liver enzymes returned to normal albumin chronically low 2.2-2.6 2018-2022. Bile Acid March 2018 me 74 post 231. Elevated bile acids pre + post 2017. 2018 Albumin low 2.2-2.6 2018-2022. Recent ahemis. 7/2021 pcv = 32. 12/2021 pcv = 34. 1/29/22 pcv = 32. 2/7/22 pcv = 27

**SPECIES**

Canine

path review concern lymphocytic leukemia. 1/20/22 blood anemia 103 (normal to 99).

**BREED**

Date of Previous IntraPet Ultrasound: 12-8-2017, 9-11-2020.

Sedation: Declined - concern with hepatic disease and dry metabolism. Stat Report: Not requested.

Imaging Performed By: Rachel Brillhart, RDMS.

Miniature Schnauzer

**SEX**

Spayed Female

**ULTRASONOGRAPHIC EXAMINATION OF THE ABDOMEN****Urinary System**

Urinary bladder is moderately distended with anechoic contents. It has normal uniform wall thickness (< 0.2 cm). No masses or cystoliths are observed.

**AGE**

1/13/12

Kidneys are bilaterally normal in size (left kidney 4.29 cm, right kidney 3.8 cm), irregular and diffusely echogenic with decreased corticomedullary distinction and poor visualization of internal architecture. Renal pelvis is dilated (pyelectasia), measuring (0.6 cm in left kidney, 0.41 cm in right kidney). No visible obstruction is observed, but cannot be ruled out. Non-obstructive linear multifocal hyperechoic diverticular foci with acoustic shadowing are noted.

**WEIGHT**

16.4 lbs

**INTERPRETED BY**Beth Johnson, DVM  
DACVIM**Adrenal Glands**

Left adrenal gland is normal in size (1.88 cm long x 0.58 cm at cranial pole and 0.55 cm at caudal pole), shape and contour. Corticomedullary structure is unremarkable.

Right adrenal gland is normal in size (1.98 cm long x 0.69 at cranial pole and 0.47 cm at caudal pole), shape and contour. Corticomedullary structure is unremarkable.

**HOSPITAL NAME**

Bel Air VH

**Spleen**

Spleen is subjectively normal in size with normal smooth margins. Parenchyma is normal in echogenicity and echotexture. No focal nodules or masses are observed. Splenic vasculature appears normal.

**REFERRING VET**

Dr. Schmidt

**Liver**

Liver is subjectively normal in size. Margins are sharp and smooth. It has normal homogenous echotexture and normal echogenicity. No focal lesions are observed. Visible vasculature appears normal. GB contains a moderate amount of non-dependent, mildly aggregated/inspissated sludge. Hypo to anechoic cystic areas are noted between the gallbladder sludge and luminal wall. The wall is otherwise smooth without visible thickening. There is no evidence of cystic or CBD dilation. There is no evidence of effusion.

**INVOICE**

96088

**Gastrointestinal**

The visible gastric wall is normal in thickness (canine < 0.5 cm and feline < 0.4 cm). The stomach is empty.

The small intestines are normal in wall thickness and layering. Small intestinal motility appears adequate (1-3 contractions per min). There are no luminal contents noted within small intestines.

Colon is normal in wall thickness (< 0.2 cm) and layering.

### ***Pancreas***

Pancreas has normal homogenous echotexture and is normal in echogenicity and smooth margination. There is no evidence of peripancreatic inflammation.

### ***Free Abdomen***

Lymph nodes are normal with no observed enlargement.

## **ULTRASONOGRAPHIC FINDINGS**

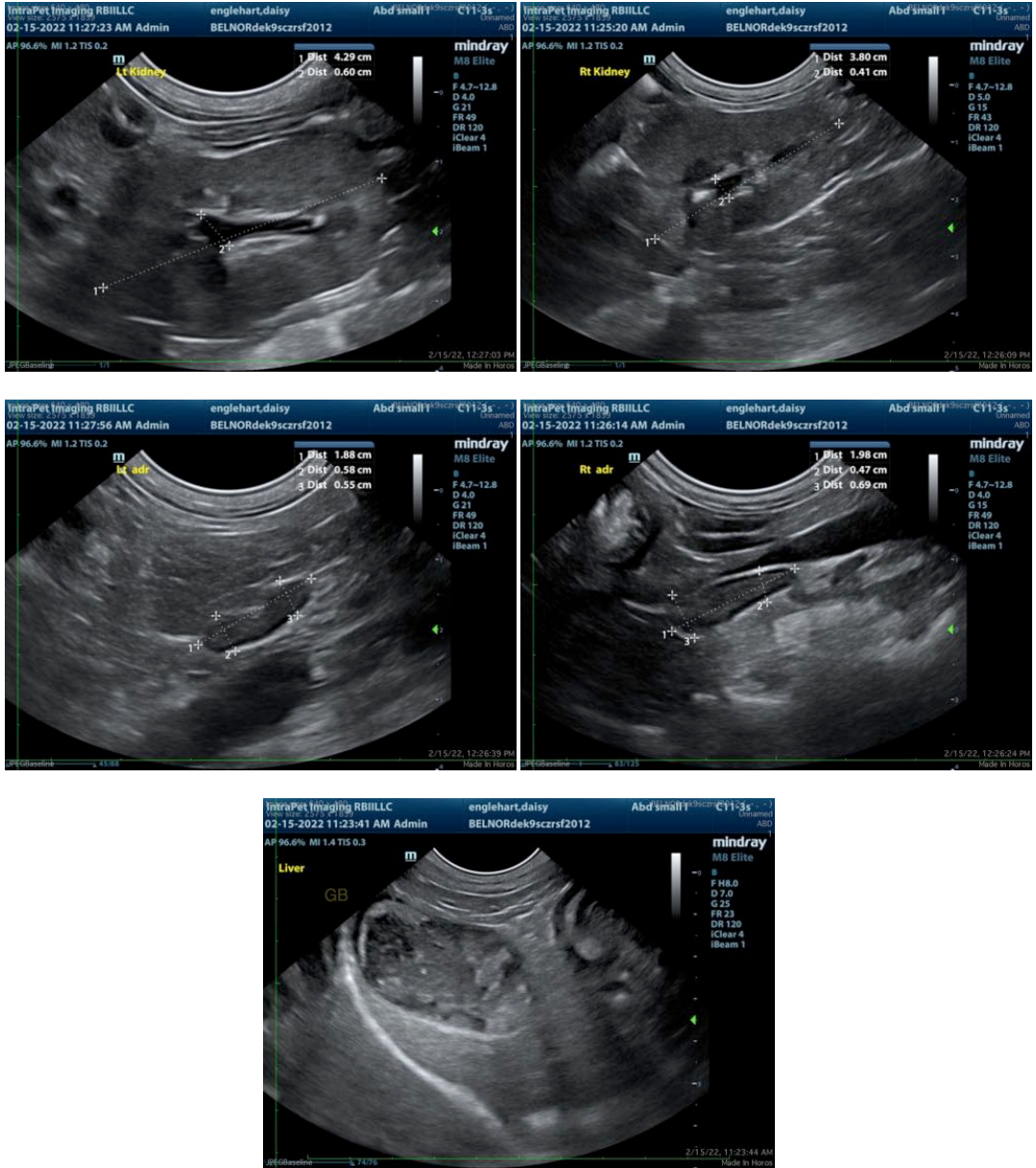
- Chronic Kidney Disease – This appearance of the kidneys is consistent with chronic kidney disease such as chronic glomerular or interstitial nephritis, chronic pyelonephritis, etc.
- Pyelectasia – Differentials for pyelectasia include pyelonephritis, diuresis, congenital malformation or ureteral or lower urinary tract obstruction.
- Non-obstructive, dystrophic mineralization.
- Early mucocele – Cholecystic debris is of unknown clinical significance. It can be seen with biliary stasis from fasting or illness. Cholecystic debris is not necessarily related to hepatobiliary disease. The non-dependent nature of this sludge combined with the cystic areas are suggestive, however, of possible emerging cystic mucosal hyperplasia or early gallbladder mucocele.

## **INTERPRETATION OF THE FINDINGS & FURTHER RECOMMENDATIONS**

The low albumin is likely secondary to decreased liver function given the historically high bile acids. However, proteinuria is also reportedly present. So if the sediment is otherwise quiet and urine culture is negative then recommendation including a urine protein to creatinine ratio to see if there is a concurrent protein loss through the urine.

If not already evaluated a gastrointestinal malabsorption panel including TLI, PLI, folate and cobalamin to Texas A&M GI laboratory can also be considered to further assess the GI tract and pancreas. However, given those recommendations the suspicion is this patient's clinical signs are secondary to an early gallbladder mucocele as well as decreased liver function given the markedly increased bile acids.

Further evaluation of the liver can be considered with an abdominal CT scan followed by a surgical liver biopsy at which time the gallbladder should also be assessed and likely removed. In the meantime if anesthesia is declined then continued medical management of clinical signs and potential hepatic encephalopathy is recommended. Ursodiol could be added if not in place due to the progressive gallbladder debris.



The information and recommendations provided are based on the images presented by the referring veterinarian. No evaluation can be communicated regarding pathology that was not visible in the image/video clips provided.

Thank you for this referral. If the clinical or image interpretation does not parallel your findings or if I can be of any further assistance please contact me.

Beth Johnson, DVM DACVIM

Beth.Johnson@SonoPath.com