



PATIENT PRESENTING CLINICAL SIGNS

PATIENT Charlie McHugh
SPECIES Canine
BREED Dachshund
SEX Neutered Male
AGE 7 years
WEIGHT 16.7 lbs

History: Presented 1/31/22 with hematochezia, diarrhea, vomiting, and inappetence. Labwork at that time supported HGE. Treated in hospital for 2 days on fluids, antibiotics and anti-nauseas. Clinically improved. Laboratory values started to improve. P was sent home with oral medications and daily SQ fluid therapy. Rechecked p on 2/7/22. Clinically doing very well. Eating and drinking. No vomiting or hematochezia. Does have a history of sudden acquired retinal degeneration that occurred 9/2020. P is nonvisual Physical exam findings: 2/7/22 - BAR, well hydrated. No concerns Abnormal CBC values: HCT 65%, RBC 9.26K, Hemoglobin 23g/dL Abnormal Chemistry Values: CRE 2.4, BUN 33, TP 8.8, albumin 3.5, globulin 5.3. ALT 131. ALP <10 Abnormal UA Values: USG 1031 Radiograph Findings(email radiographs if available): Reason for Ultrasound: Evaluate for underlying renal disease and causes of potential secondary polycythemia

ULTRASONOGRAPHIC EXAMINATION OF THE ABDOMEN

Urinary System

Urinary bladder is moderately distended with anechoic contents. It has normal uniform wall thickness (< 0.2 cm). No masses or cystoliths are observed.

The prostate is normal for a neutered dog.

Left kidney is normal in size (5.0 cm), shape with smooth peripheral margination. The left kidney is diffusely hyperechoic with decreased corticomedullary distinction and mildly decreased visualization of internal architecture. There is no pyelectasia noted. No mineral is observed.

Right kidney is normal in size (5.73 cm), shape with smooth peripheral margination. The left kidney is diffusely hyperechoic with decreased corticomedullary distinction and mildly decreased visualization of internal architecture. There is no pyelectasia noted. No mineral is observed.

Adrenal Glands

Left adrenal gland is normal in size (0.54 cm at cranial pole and 0.64 cm at caudal pole), shape and contour. Corticomedullary structure is unremarkable.

Right adrenal gland is normal in size (2.06 cm long x 0.68 cm at cranial pole and 0.65 cm at caudal pole), shape and contour. Corticomedullary structure is unremarkable.

Spleen

Spleen is subjectively normal in size with normal smooth margins. Parenchyma is normal in echogenicity and echotexture. No focal nodules or masses are observed. Splenic vasculature appears normal.

Liver

Liver is subjectively normal in size. Margins are sharp and smooth. It has normal homogenous echotexture and normal echogenicity. No focal lesions are observed. Visible vasculature appears normal. The gallbladder lumen is moderately distended. The wall of the gallbladder is not thickened and has a smooth mucosal surface. There is a moderate amount of non-organized echogenic debris. The cystic and common bile ducts are normal/not visible.

INTERPRETED BY

Beth Johnson, DVM
DACVIM

IMAGING PERFORMED BY

Loetitia Saint-Jacques, RVT

HOSPITAL NAME

Alpine AH

REFERRING VET

Dr. Sjoin

INVOICE

96069

DATE

2/14/22



PATIENT *Gastrointestinal*

Charlie McHugh The stomach is moderately dilated with fluid and irregular shadowing material most consistent with normal ingesta and gas. It measures at a normal thickness of <0.7cm with some variability due to the presence of rugal folds. The distinction of the gastric wall layering is adequate and there is no impression of reduced peristaltic activity. No masses or focal lesions were observed.

SPECIES

Canine The small intestines are normal in wall thickness and layering. Small intestinal motility appears adequate (1-3 contractions per min). There are no luminal contents noted within small intestines.

BREED

Dachshund Colon is normal in wall thickness (< 0.2 cm) and layering.

SEX

Neutered Male Pancreas is slightly hypoechoic to the surrounding tissue. The visible is smooth and normal in contour. There is no visible pancreatic duct dilation. However, there is mildly hyperechoic mesentery immediately surrounding the pancreas. No free fluid is appreciated.

AGE

7 years *Free Abdomen*

Lymph nodes are normal with no observed enlargement.

WEIGHT

16.7 lbs

ULTRASONOGRAPHIC FINDINGS

INTERPRETED BY

Beth Johnson, DVM
DACVIM

PRIMARY FINDINGS:

- Mild acute or possibly resolving pancreatitis.
- The significance of the aggregated gallbladder debris is unclear. This could represent an early mucocele, cholestasis, or may be secondary to fasting.
- Bilaterally hyperechoic kidneys with slight loss of corticomedullary distinction. Differentials include acute kidney insult or injury or infection on top of chronic glomerulonephritis, chronic interstitial nephritis, chronic pyelonephritis etc.

IMAGING PERFORMED BY

Loetitia Saint-Jacques, RVT

HOSPITAL NAME

Alpine AH

INTERPRETATION OF THE FINDINGS & FURTHER RECOMMENDATIONS

REFERRING VET

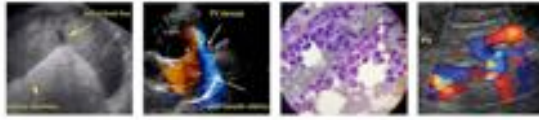
Dr. Sjoin Recommendations for this patient given the hyperechoic nature of the kidneys includes testing for infectious disease with a urine culture if not recently evaluated as well as testing for Leptospirosis. Other recommendations include continued medical management of any clinical signs associated with likely resolving, based on reported history, pancreatitis.

INVOICE

96069 If not already implemented a low-fat diet can be considered. However, if the patient is clinically doing well manage the renal disease through diet may be more important. If not recently evaluated a blood pressure is also recommended.

DATE

2/14/22



PATIENT

Charlie McHugh

SPECIES

Canine

BREED

Dachshund

SEX

Neutered Male

AGE

7 years

WEIGHT

16.7 lbs

INTERPRETED BY

Beth Johnson, DVM
 DACVIM

IMAGING PERFORMED BY

Loetitia Saint-Jacques, RVT

HOSPITAL NAME

Alpine AH

REFERRING VET

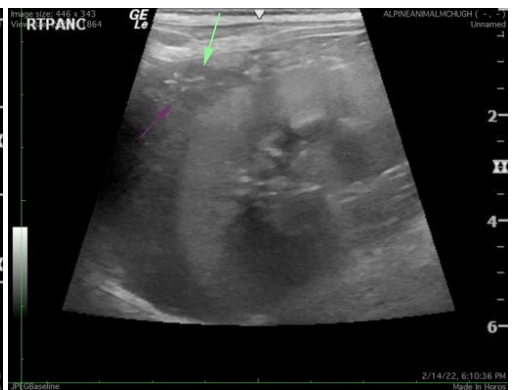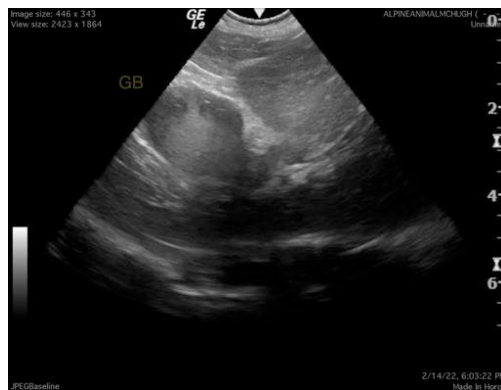
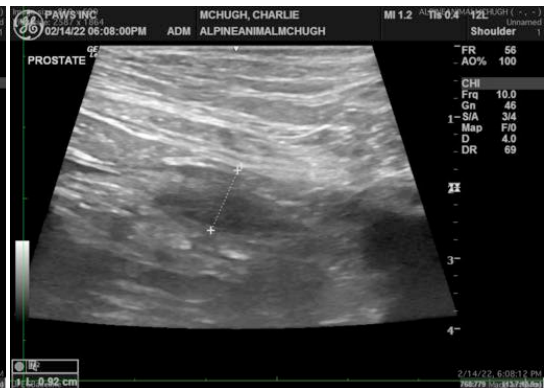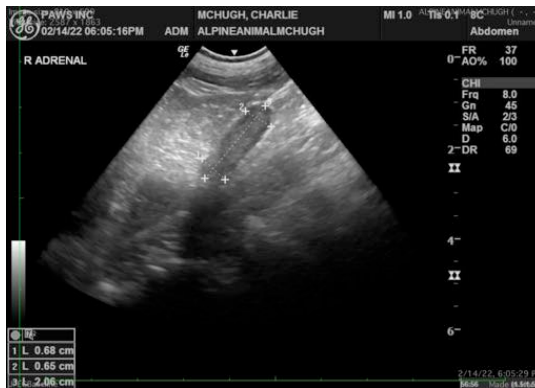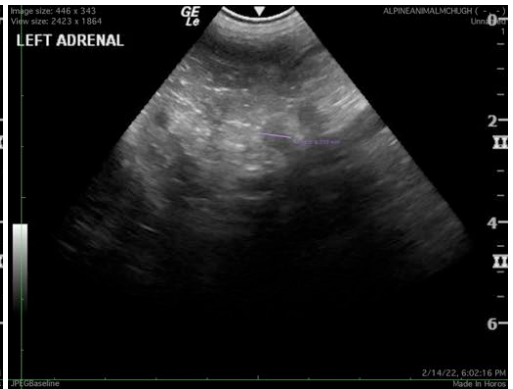
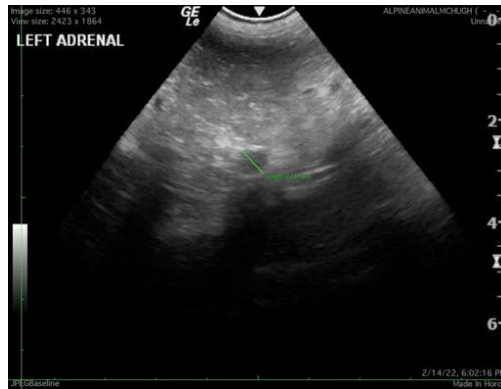
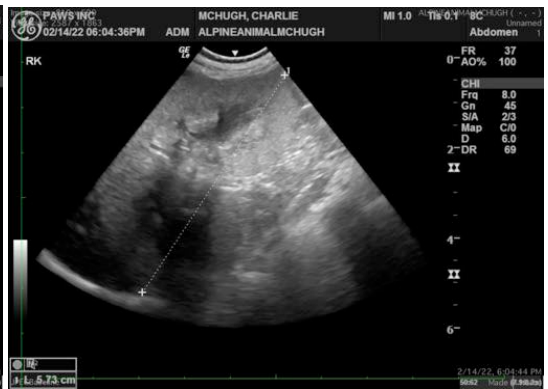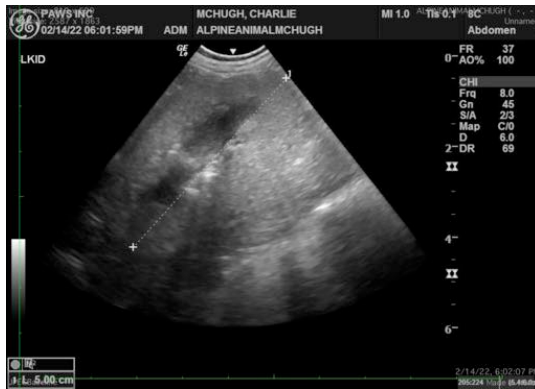Dr. Sjlain

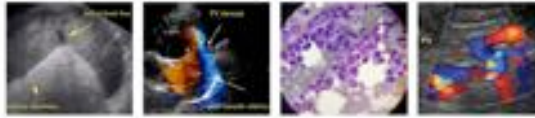
INVOICE

96069

DATE

2/14/22





PATIENT

Charlie McHugh

SPECIES

Canine

BREED

Dachshund

SEX

Neutered Male

AGE

7 years

WEIGHT

16.7 lbs

INTERPRETED BY

Beth Johnson, DVM
DACVIM

IMAGING PERFORMED BY

Loetitia Saint-Jacques, RVT

HOSPITAL NAME

Alpine AH

REFERRING VET

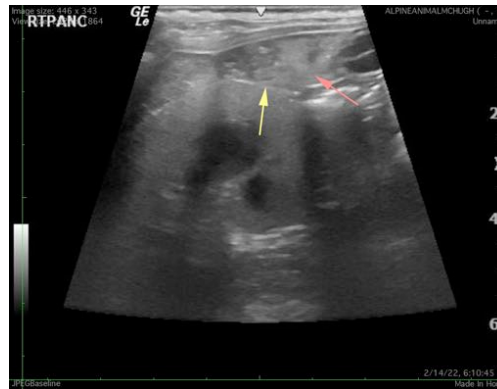
Dr. Sjoin

INVOICE

96069

DATE

2/14/22



The information and recommendations provided are based on the images presented by the referring veterinarian/sonographer. No evaluation can be communicated regarding pathology that was not visible in the image/video clips provided.

Thank you for this referral. If the clinical or image interpretation does not parallel your findings or if I can be of any further assistance please contact me.

Beth Johnson, DVM DACVIM

Beth.Johnson@SonoPath.com