



PATIENT

Trevi Roux

SPECIES

Canine

BREED

Lab Mix

SEX

Spayed Female

AGE

10 Years

WEIGHT

60 Pounds

INTERPRETED BY

Beth Johnson, DVM
DACVIM

IMAGING PERFORMED BY

Amy Mayhew, LVT

HOSPITAL NAME

SVS Imaging MI

REFERRING VET

Dr. Jordan Roux

INVOICE

21100

DATE

2/13/23

PRESENTING CLINICAL SIGNS

History: Intermittent vomiting and anorexia. Unresolved diarrhea - will resolve then represent a few days later. Attempted multiple treatments (pectalin paste, fenbendazole, bland diet, Metronidazole). Will resolve then represent

Abnormal PE/Chem/CBC/UA Results: Diarrhea Panel: WNL Abdominal Radiographs: WNL Hypoproteinemia in November (TP 4.3, Alb 1.8)and February (TP 3.8, ALB 1.8, Glob 2.0) Lymphopenia (11/2022 0.94 and 2/2023 0.63) Low ALK (ALKP 14 on 11/2022 and 13 on 2/2023) Labs attached.

ULTRASONOGRAPHIC EXAMINATION OF THE ABDOMEN

Urinary System

Urinary bladder is only mildly distended (empty). Visible contents are anechoic. Urinary bladder wall is unable to be fully assessed for pathology without further distension. No visible masses or cystoliths are observed. The trigone and visible pelvic urethra are normal thickness with a smooth mucosal surface. If there are urinary signs and/or concern for urinary bladder pathology, reassessment after complete filling is recommended.

Left kidney is normal is size (5.88 cm), shape and echogenicity. It has smooth peripheral margination. There is a normal 1:3 cortex to medulla ratio with appropriate corticomedullary distinction. There is no evidence of pyelectasia, mineral or infarcts observed.

Right kidney is normal is size (5.7 cm), shape and echogenicity. It has smooth peripheral margination. There is a normal 1:3 cortex to medulla ratio with appropriate corticomedullary distinction. There is no evidence of pyelectasia, mineral or infarcts observed.

Adrenal Glands

Left adrenal gland is normal in size (0.47 cm at cranial pole and 0.67 cm at caudal pole), shape and overall architecture, echogenicity and echotexture. Visible surrounding vasculature appears normal.

Right adrenal gland is normal in size (0.58 cm at cranial pole and 0.64 cm at caudal pole), shape and overall architecture, echogenicity and echotexture. Visible surrounding vasculature appears normal.

Spleen

Spleen is subjectively normal in size with a normal smooth capsular contour. Parenchyma is appropriately finely textured and homogenous with normal echogenicity relative to surrounding tissue (hyperechoic to liver). No focal nodules or masses are observed. Splenic vasculature appears normal.

Liver

Liver is subjectively normal in size with normal smooth curvilinear peripheral contour. Parenchyma is appropriately hypoechoic to the spleen in echogenicity and appropriately mildly coarse and homogenous in echotexture. No focal lesions are observed. Visible vasculature and biliary tree appear normal without distension or congestion.

Gallbladder is moderately distended with anechoic bile as well as mild to moderate suspended and gravity dependent echogenic debris. The wall is smooth without visible thickening. There is no evidence of cystic or CBD dilation. There is no evidence of effusion or inflammation.

Gastrointestinal



PATIENT

Trevi Roux

The visible stomach wall is normal in thickness and layering. The lumen of the stomach is empty with no evidence of obstruction, foreign material or infiltrative disease. Pyloric outflow tract appears patent.

SPECIES

Canine

Small intestine is diffusely mildly thick with a relatively thick mucosa compared to other layers. Normal wall layering is preserved; however, the mucosa is more echogenic than normal and contains hyperechoic striations perpendicular to the lumen. The lumen of the small intestine is empty with no evidence of obstruction or foreign material.

BREED

Lab Mix

The visible colon is normal in wall thickness and layering. Contents are consistent with normal formed feces and gas.

SEX

Spayed Female

The observed pancreas appears appropriately isoechoic to surrounding omental fat. Visible capsule is smooth and normal in contour. Visible pancreatic parenchyma is homogenous and unremarkable. There is no visible pancreatic duct dilation. There is no evidence of active peripancreatic inflammation.

AGE

10 Years

Free Abdomen

A very scant amount of anechoic free fluid was noted. The mesenteric lymph nodes are prominent in size with swollen capsular contour. Normal elongated shape (length to width ratio) is maintained. There is no loss of parenchymal detail.

WEIGHT

60 Pounds

ULTRASONOGRAPHIC FINDINGS

Primary Findings

- Lymphangiectasia- small bowel findings are most consistent with lacteal dilation. These findings can be observed with protein-losing enteropathies caused by either primary lymphangiectasia or primary infiltrative inflammatory disease with secondary lymphangiectasia. Infiltrative neoplasia is possible but considered less likely. Histopathology is necessary to definitively determine underlying cause.
- Reactive mesenteric lymph nodes – infiltrative neoplastic disease cannot be ruled out but is considered less likely.
- A very scant amount of anechoic free fluid, likely secondary to the hypoalbuminemia.

INTERPRETED BY

Beth Johnson, DVM
DACVIM

IMAGING PERFORMED BY

Amy Mayhew, LVT

HOSPITAL NAME

SVS Imaging MI

Secondary Findings

- Mild to moderate gallbladder debris - Cholecystic debris is of unknown clinical significance. It can be seen with biliary stasis from fasting or illness. Cholecystic debris is not necessarily related to hepatobiliary disease. Echogenic bile is most commonly an incidental finding in dogs and should be interpreted in combination with clinical signs such as nausea, inappetence, cranial abdominal discomfort and/or laboratory changes such as increased ALP and/or increased Tbili.

REFERRING VET

Dr. Jordan Roux

INVOICE

21100

INTERPRETATION OF THE FINDINGS & FURTHER RECOMMENDATIONS

A gastrointestinal malabsorption panel (including cobalamin, folate, TLI and PLI) to Texas A&M GI Laboratory is recommended for further evaluation of GI and pancreatic function.

DATE

2/13/23

Ideally, biopsies of the GI tract are recommended to definitively diagnose and therefore manage the infiltrative bowel process.



PATIENT

Trevi Roux

SPECIES

Canine

BREED

Lab Mix

SEX

Spayed Female

AGE

10 Years

WEIGHT

60 Pounds

INTERPRETED BY

Beth Johnson, DVM
DACVIM

IMAGING PERFORMED BY

Amy Mayhew, LVT

HOSPITAL NAME

SVS Imaging MI

REFERRING VET

Dr. Jordan Roux

INVOICE

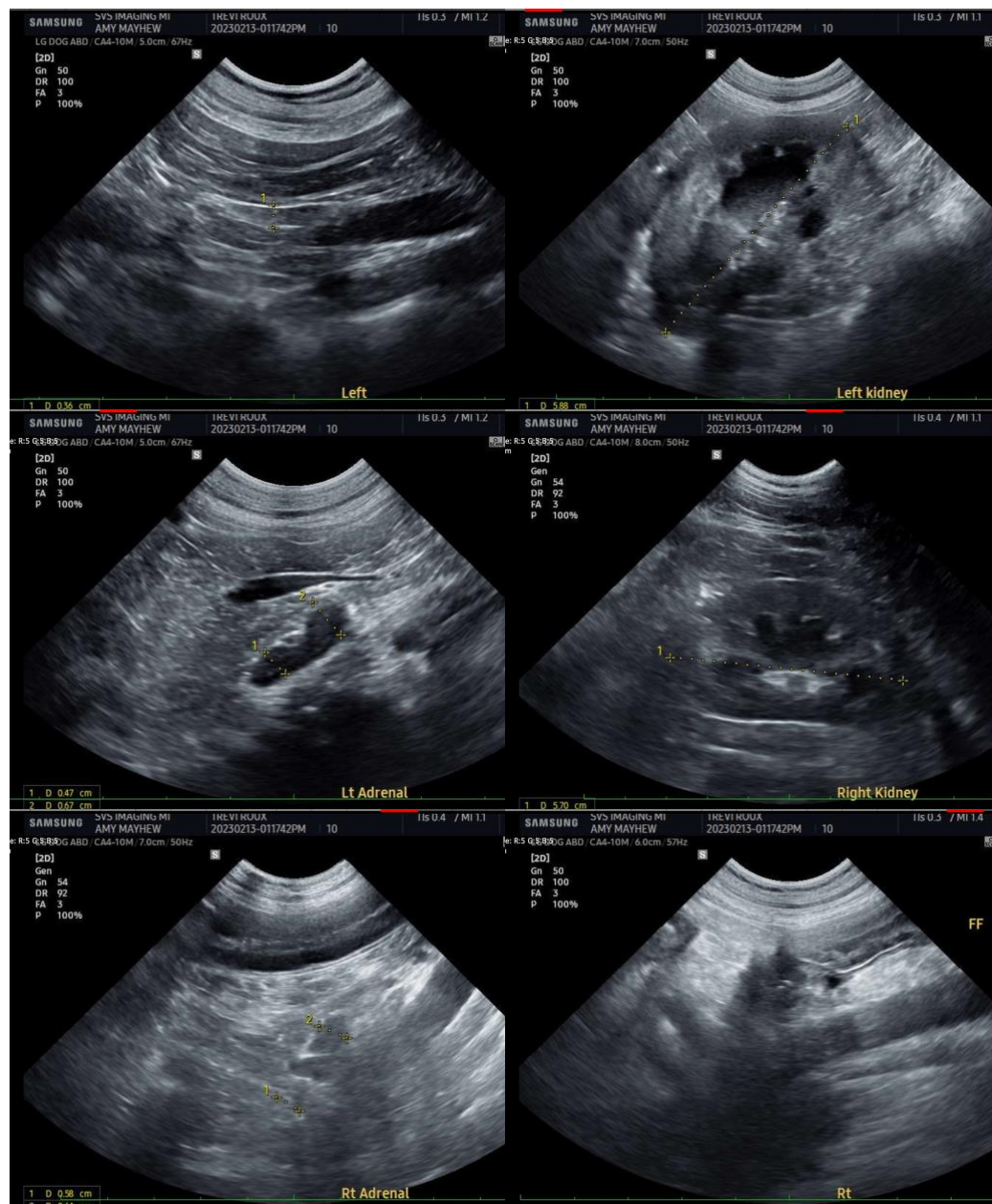
21100

DATE

2/13/23

If biopsies cannot be obtained safely due to low albumin or patient stability, etc., empirical therapies could include diet change to an ultra-low-fat diet, empirical deworming with a 5 day course of Panacur, cobalamin supplementation (unless cobalamin level is evaluated and supplementation is not warranted) a probiotic and prednisolone (if not contraindicated based on patient contraindications, co-morbidities, etc.). Calcium monitoring, and supplementation, if necessary, is also recommended.

Additionally, if not recently evaluated, to rule out concurrent proteinuria as a source of hypoalbuminemia, urinalysis and, if indicated based on urinalysis results, urine culture are recommended. If protein is present in an otherwise quiet sediment, protein quantification with a urine protein to creatinine ration is recommended.





PATIENT

Trevi Roux

SPECIES

Canine

BREED

Lab Mix

SEX

Spayed Female

AGE

10 Years

WEIGHT

60 Pounds

INTERPRETED BY

Beth Johnson, DVM
DACVIM

IMAGING PERFORMED BY

Amy Mayhew, LVT

HOSPITAL NAME

SVS Imaging MI

REFERRING VET

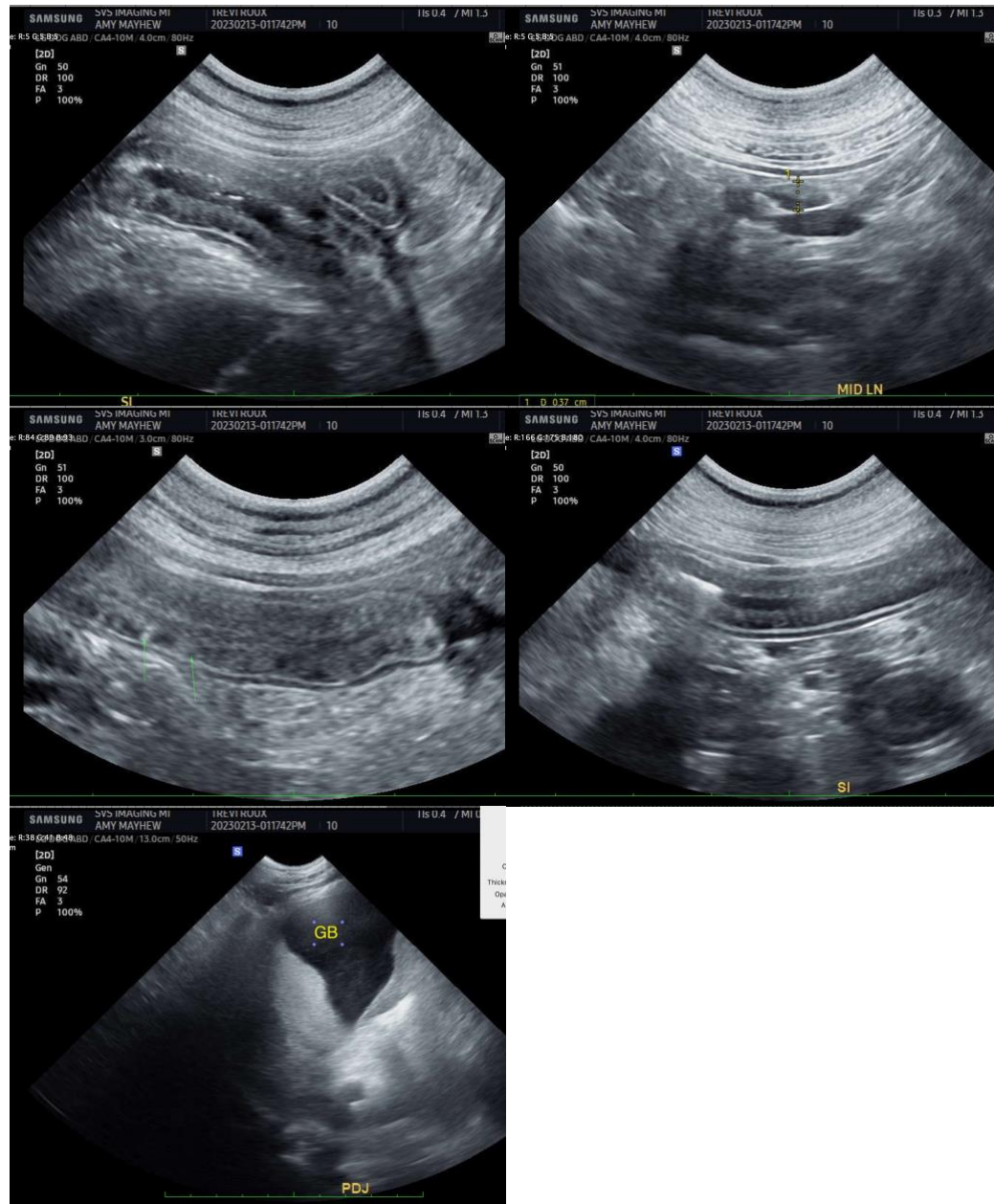
Dr. Jordan Roux

INVOICE

21100

DATE

2/13/23



The information and recommendations provided are based on the images presented by the referring veterinarian. No evaluation can be communicated regarding pathology that was not visible in the image/video clips provided.

Thank you for this referral. If the clinical or image interpretation does not parallel your findings or if I can be of any further assistance please contact me.

Beth Johnson, DVM DACVIM

Beth.Johnson@SonoPath.com



PATIENT

Trevi Roux

SPECIES

Canine

BREED

Lab Mix

SEX

Spayed Female

AGE

10 Years

WEIGHT

60 Pounds

INTERPRETED BY

Beth Johnson, DVM
DACVIM

**IMAGING
PERFORMED BY**

Amy Mayhew, LVT

HOSPITAL NAME

SVS Imaging MI

REFERRING VET

Dr. Jordan Roux

INVOICE

21100

DATE

2/13/23