**DATE PRESENTING CLINICAL SIGNS**

2/13/23

History of liver and splenic masses. Previous ultrasound scan also done at AVIMO. Previous ultrasound with Intrapet on 11/21, patient was diagnosed with Cushings and started on Vetoryl. In the last few months patient has been losing weight and having episodes of ADR.

PATIENT

Nikko Dobbines

Current Medications: Vetoryl 60mg SID, Mycequin/Proviale SID, Proviale SID, Gabapentin 300mg 1 -2 PO BID PRN, Hills i/d diet, Mirtazapline 15mg SID

SPECIES

Lab Results: See attached.

Canine

Date of Previous IntraPet Ultrasound: 10/29/21. See attached.

BREED

Labrador Mix

Sedation: Not required to complete full diagnostic ultrasound.

Stat Report: Not requested.

Imaging Performed By: Rachel Brillhart, RDMS.

SEX

Spayed Female

ULTRASONOGRAPHIC EXAMINATION OF THE ABDOMEN**Urinary System**

Urinary bladder is adequately distended with anechoic contents. No masses, inflammatory changes, echogenic sediment or cystoliths are observed. The urinary bladder, trigone and visible pelvic urethra are normal in thickness with a smooth mucosal surface.

AGE

6/25/09

Kidneys are overall normal in size and shape with smooth peripheral margination. A normal 1:3 cortex to medulla ratio is maintained. The medulla and cortices are uniform in texture with some mild increased cortical echogenicity and mild loss of corticomedullary distinction, expected in this age patient. There is no evidence of pyelectasia, mineral or infarcts observed. The right kidney measures 8.21 cm. The left kidney measures 7.22 cm. Small bilateral cortical cysts are present.

WEIGHT

55.8 Pounds

INTERPRETED BYBeth Johnson, DVM
DACVIM**Adrenal Glands**

Adrenal glands are plump/swollen in size. Normal shape and contour are maintained without evidence of capsular invasion. Corticomedullary structure is unremarkable. Visible surrounding vasculature appears normal. The right adrenal gland measures 3.25 cm long x 1.02 cm at the cranial pole and 1.37 cm at the caudal pole. The left adrenal gland measures 3.41 cm long x 1.1 cm at the cranial pole and 1.1 cm at the caudal pole.

HOSPITAL NAME

Abbey AH

Spleen

Spleen is subjectively normal in size with a normal smooth capsular contour. Parenchyma is appropriately finely textured and homogenous with normal echogenicity relative to surrounding tissue (hyperechoic to liver). No focal nodules or masses are observed. Splenic vasculature appears normal.

REFERRING VET

Dr. Kluttz

Liver

Diffusely, the liver is subjectively enlarged with mildly irregular margins. Parenchyma is heterogenous characterized by multiple poorly defined hypoechoic nodules within otherwise hyperechoic liver parenchyma. Visible vasculature and biliary tree appear normal without distension or congestion. In addition to the diffuse changes, there are two more discrete focal masses in the left liver. One of the masses measures approximately 7.0 cm x 8.0 cm in size with a mixed echogenic cystic appearance, including a 3-4 cm cystic center. The second mass is 6.95 cm x 5.64 cm in size with a similarly mixed echogenic appearance, but less cystic in appearance. Both masses result in mild disruption of architecture.

INVOICE

21093

Gallbladder is moderately distended with anechoic bile as well as moderate suspended and gravity dependent echogenic debris. The wall is smooth without visible thickening. There is no evidence of cystic or CBD dilation. There is no evidence of effusion or inflammation.

Gastrointestinal

The visible stomach wall is normal in thickness and layering. The lumen of the stomach is empty with no evidence of obstruction, foreign material or infiltrative disease. Pyloric outflow tract appears patent.

The visible small intestines are normal in wall thickness and layering. Small intestinal motility appears adequate (1-3 contractions per min). The lumen of the small intestine is empty with no evidence of obstruction, foreign material or infiltrative disease.

The visible colon is normal in wall thickness and layering. Contents are consistent with normal formed feces and gas.

Pancreas

The observed pancreas appears appropriately isoechoic to surrounding omental fat. The capsule is mildly irregular in shape. Parenchyma is mildly heterogenous and coarse. There is no visible pancreatic duct dilation. There is no evidence of active peripancreatic inflammation.

Free Abdomen

There is no evidence of peritoneal effusion. Sublumbar lymphadenopathy is noted with a slightly heterogenous but primarily isoechoic representative node measuring 0.87 cm thick.

ULTRASONOGRAPHIC FINDINGS

Primary Findings

- Bilateral adrenomegaly, consistent with this patient's reported history of hyperadrenocorticism and Vetoryl therapy.
- Moderate gallbladder debris - Cholecystic debris is of unknown clinical significance. It can be seen with biliary stasis from fasting or illness. Cholecystic debris is not necessarily related to hepatobiliary disease. Echogenic bile is most commonly an incidental finding in dogs and should be interpreted in combination with clinical signs such as nausea, inappetence, cranial abdominal discomfort and/or laboratory changes such as increased ALP and/or increased Tbili.
- A diffusely heterogenous liver. This is likely a benign change with two more aggressive appearing focal masses noted in the left liver. Both masses appear slightly progressive in size, but generally static given the long duration since the previous ultrasound, raising benign differentials as more likely. Having said that, given the loss of architecture and mild progression in size, etc., infiltrative neoplasia is still a differential, including primary hepatocellular carcinoma, sarcoma, round cell neoplasia, etc.
- The previously noted splenic nodule was not well observed in this study.
- Sublumbar lymphadenopathy- Both reactive, as well as infiltrative neoplasia are differentials and cannot be differentiated without tissue sampling.

Secondary Findings

- Age-related kidney changes with small bilateral cortical cysts

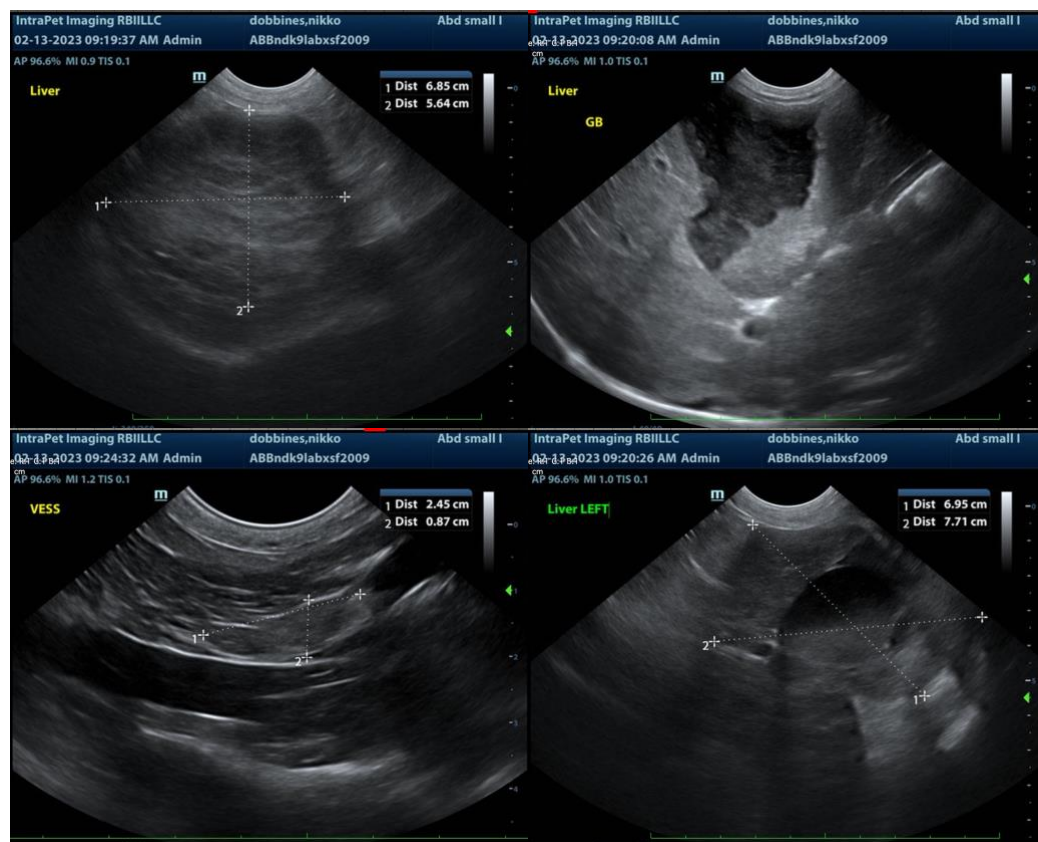
- Pancreatic age-related remodeling – Mild irregularities are consistent with benign age-related change. Low-grade smoldering chronic pancreatitis cannot be ruled out and should be suspected in the face of appropriate clinical signs.

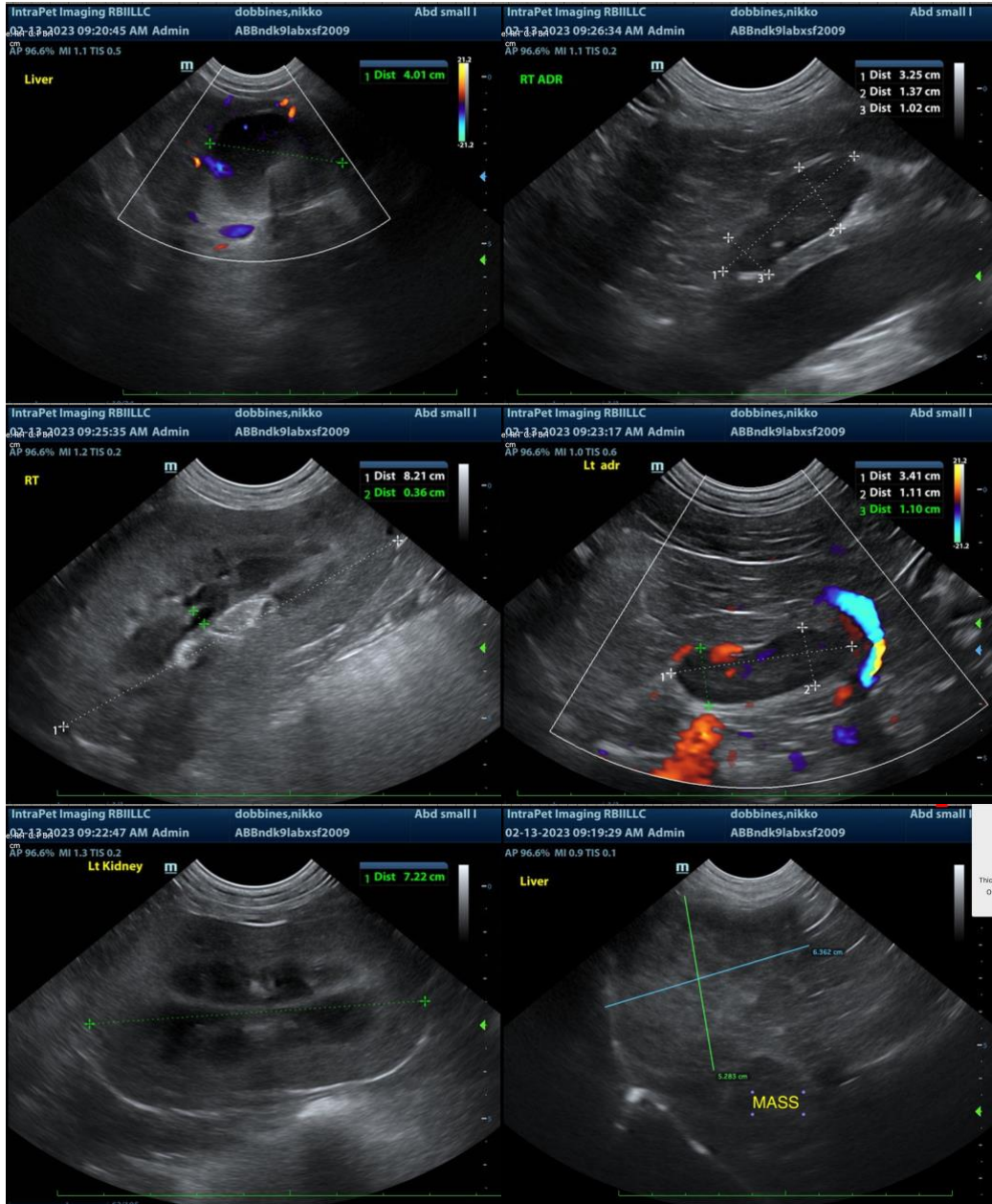
INTERPRETATION OF THE FINDINGS & FURTHER RECOMMENDATIONS

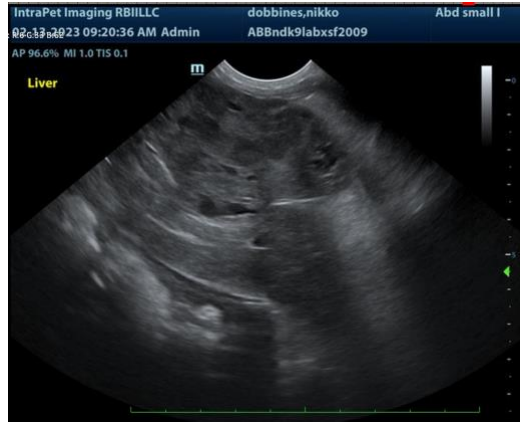If not previously evaluated, fine needle aspirates of the liver masses could be considered if patients coagulation status is appropriate.

Additionally, three view thoracic radiographs are recommended for further assessment of cardio-pulmonary status as well as to further evaluate for any evidence of metastatic disease, if not recently evaluated.

Having said that, however, this patients weight loss and intermittent malaise are likely secondary to hypocortisolemia and/or a Vetoryl reaction given the documented low stim results reported, combined with the more recent hyperkalemia, azotemia, etc. Recommendations include discontinuation of Vetoryl until signs of hyperadrenocorticism return (if they do). At that time, Vetoryl could be restarted, but should be restarted at a lower total daily dose and divided into twice daily dosing vs once daily dosing. Even if the patient requires 60 mg of Vetoryl per day eventually, 30 mg twice per day is often better tolerated than 60 mg once per day. This patient may truly be Addisonian, however, not require future Vetoryl and further investigation of that, at this time, is recommended with an ACTH stimulation test.







The information and recommendations provided are based on the images presented by the referring veterinarian. No evaluation can be communicated regarding pathology that was not visible in the image/video clips provided.

Thank you for this referral. If the clinical or image interpretation does not parallel your findings or if I can be of any further assistance please contact me.

Beth Johnson, DVM DACVIM
Beth.Johnson@SonoPath.com