



PATIENT

Marshall Molinaro

SPECIES

Canine

BREED

Alaskan Husky

SEX

Spayed Female

AGE

11 Years

WEIGHT

48 Pounds

INTERPRETED BY

Beth Johnson, DVM
DACVIM

IMAGING PERFORMED BY

Kara Wallisch

HOSPITAL NAME

Sondel Family VC

REFERRING VET

Elana Frankenthal

INVOICE

21090

DATE

2/13/23

PRESENTING CLINICAL SIGNS

History: Had seizure 1 week ago on Sunday (tonic clonic, first seizure). Exam/neuro exam WNL Area of interest: liver/spleen, rule out neoplasia

Abnormal PE/Chem/CBC/UA Results: CBC: HCT 38%, reticulocytosis Chem: ALP 600s Rest wnl

ULTRASONOGRAPHIC EXAMINATION OF THE ABDOMEN

Urinary System

Urinary bladder is adequately distended with anechoic contents. No masses, inflammatory changes, echogenic sediment or cystoliths are observed. The urinary bladder, trigone and visible pelvic urethra are normal in thickness with a smooth mucosal surface.

Left kidney is normal is size (5.8 cm), shape and echogenicity. It has smooth peripheral margination. There is a normal 1:3 cortex to medulla ratio with appropriate corticomedullary distinction. There is no evidence of pyelectasia, mineral or infarcts observed.

Right kidney is normal is size (6.6 cm), shape and echogenicity. It has smooth peripheral margination. There is a normal 1:3 cortex to medulla ratio with appropriate corticomedullary distinction. There is no evidence of pyelectasia, mineral or infarcts observed.

Adrenal Glands

The adrenal glands are unable to be well visualized in these images.

Spleen

Spleen is subjectively normal in size with a normal smooth capsular contour. Parenchyma is appropriately finely textured and homogenous with normal echogenicity relative to surrounding tissue (hyperechoic to liver). Multifocal well-demarcated hyperechoic homogenous nodules are noted. Splenic vasculature appears normal.

Liver

Liver is subjectively normal in size with normal smooth curvilinear peripheral contour. Parenchyma is appropriately hypoechoic to the spleen in echogenicity and appropriately mildly coarse and homogenous in echotexture. No focal lesions are observed. Visible vasculature and biliary tree appear normal without distension or congestion.

Gallbladder is moderately distended with anechoic bile as well as mild suspended and gravity dependent echogenic debris. The wall is smooth without visible thickening. There is no evidence of cystic or CBD dilation. There is no evidence of effusion or inflammation.

Gastrointestinal

The visible stomach wall is normal in thickness and layering. The lumen of the stomach is empty with no evidence of obstruction, foreign material or infiltrative disease. Pyloric outflow tract appears patent.

The visible small intestines are normal in wall thickness and layering. Small intestinal motility appears adequate (1-3 contractions per min). The lumen of the small intestine is empty with no evidence of obstruction, foreign material or infiltrative disease.



PATIENT

The visible colon is normal in wall thickness and layering. Contents are consistent with normal formed feces and gas.

Marshall Molinaro

Pancreas

SPECIES

The observed pancreas appears appropriately isoechoic to surrounding omental fat. Visible capsule is smooth and normal in contour. Visible pancreatic parenchyma is homogenous and unremarkable. There is no visible pancreatic duct dilation. There is no evidence of active peripancreatic inflammation.

Canine

BREED

Free Abdomen

Alaskan Husky

There is no evidence of peritoneal effusion. There is no apparent lymphadenopathy.

SEX

- Hyperechoic splenic nodules – most consistent with benign myelolipomas. Other differentials such as fibrosis or calcification caused by old hematomas or infarcts, chronic inflammation, granulomatous disease or metastatic disease cannot be ruled out, but are considered less likely.

Spayed Female

AGE

- Mild gallbladder debris - Cholecystic debris is of unknown clinical significance. It can be seen with biliary stasis from fasting or illness. Cholecystic debris is not necessarily related to hepatobiliary disease. Echogenic bile is most commonly an incidental finding in dogs and should be interpreted in combination with clinical signs such as nausea, inappetence, cranial abdominal discomfort and/or laboratory changes such as increased ALP and/or increased Tbili.

11 Years

WEIGHT

48 Pounds

INTERPRETATION OF THE FINDINGS & FURTHER RECOMMENDATIONS

INTERPRETED BY

There is no ultrasonographically visible evidence of neoplasia or a cause for this patients reported seizures. Recommendations include further work up for a possible underlying vascular event, looking for proteinuria via urinalysis and, if indicated based on urinalysis results, urine culture is recommended. If protein is present in an otherwise quiet sediment, protein quantification with a urine protein to creatinine ration is recommended. Check blood pressure as well, etc.

Beth Johnson, DVM
DACVIM

IMAGING PERFORMED BY

Ultimately, advanced imaging, such as an MRI, may be necessary.

Kara Wallisch

HOSPITAL NAME

Sondel Family VC

REFERRING VET

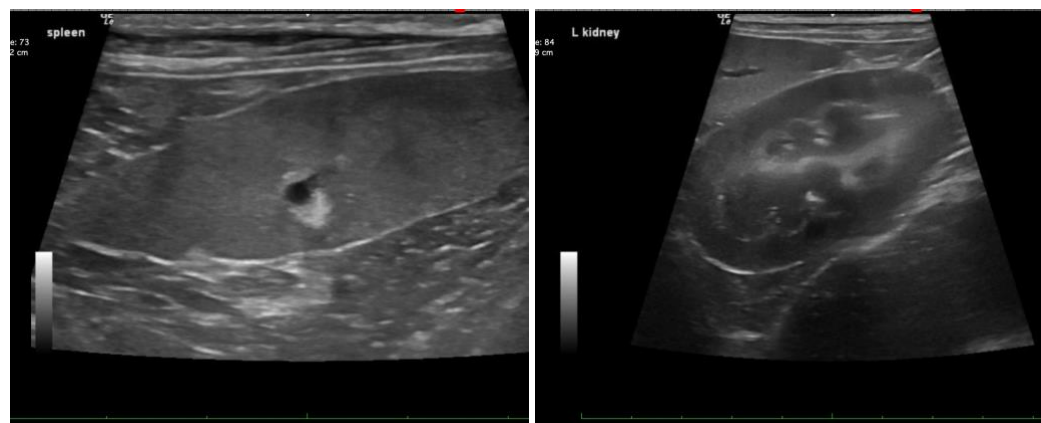Elana Frankenthal

INVOICE

21090

DATE

2/13/23





PATIENT

Marshall Molinaro

SPECIES

Canine

BREED

Alaskan Husky

SEX

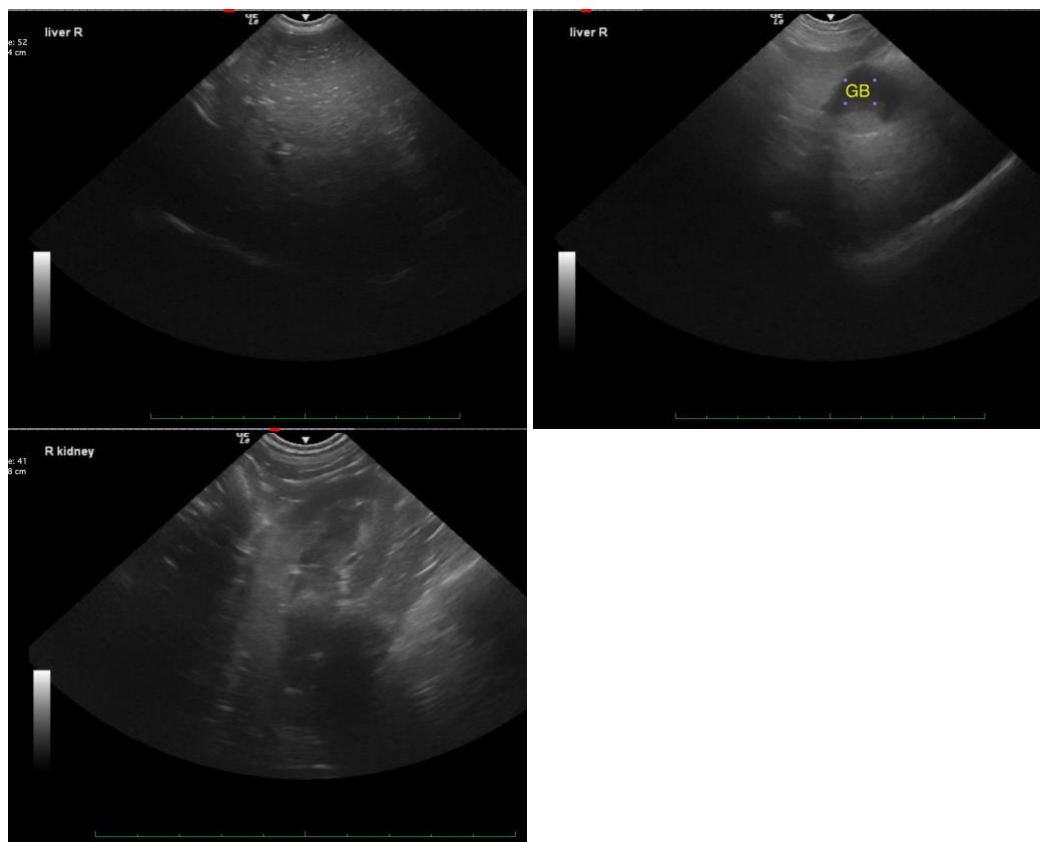
Spayed Female

AGE

11 Years

WEIGHT

48 Pounds



INTERPRETED BY

Beth Johnson, DVM
DACVIM

The information and recommendations provided are based on the images presented by the referring veterinarian. No evaluation can be communicated regarding pathology that was not visible in the image/video clips provided.

Thank you for this referral. If the clinical or image interpretation does not parallel your findings or if I can be of any further assistance please contact me.

IMAGING PERFORMED BY

Kara Wallisch

Beth Johnson, DVM DACVIM

Beth.Johnson@SonoPath.com

HOSPITAL NAME

Sondel Family VC

REFERRING VET

Elana Frankenthal

INVOICE

21090

DATE

2/13/23