



PATIENT

Alta Martin

SPECIES

Canine

BREED

Catahoula Leopard
Dog Mix

SEX

FS

AGE

13 years

WEIGHT

96 lbs

INTERPRETED BY

Beth Johnson, DVM
DACVIM

IMAGING PERFORMED BY

Pamela Harrigan,
RDCS

HOSPITAL NAME

Littleton Animal
Hospital

REFERRING VET

Dr. Tatyana Kalani

INVOICE

11305

DATE

2/12/2026

PRESENTING CLINICAL SIGNS

- Progressively increasing liver values. No clinical signs - owner reports she is doing well at home other than her mobility. ALT 177, AST 55, ALP 192, GGT 24. On Galliprant Dasaquin.

ULTRASONOGRAPHIC EXAMINATION OF THE ABDOMEN

Urinary System

The urinary bladder is adequately distended with anechoic contents. No masses, inflammatory changes, echogenic sediment or cystoliths are observed. The urinary bladder, trigone and visible pelvic urethra are normal in thickness with a smooth mucosal surface.

The right kidney is normal is size (6.7 cm), shape and echogenicity. It has smooth peripheral margination. There is a normal 1:3 cortex to medulla ratio with appropriate corticomedullary distinction. There is no evidence of pyelectasia, mineral or infarcts observed.

The left kidney is normal is size (7.69 cm), shape and echogenicity. It has smooth peripheral margination. There is a normal 1:3 cortex to medulla ratio with appropriate corticomedullary distinction. There is no evidence of pyelectasia, mineral or infarcts observed.

Adrenal Glands

Adrenal glands are plump/swollen in size. Normal shape and contour are maintained without evidence of capsular invasion. Corticomedullary structure is unremarkable. Visible surrounding vasculature appears normal. Left adrenal measures 0.91 cm at the cranial pole and 0.86 cm at the caudal pole. A hyperechoic nodule is noted in the cranial pole of the left adrenal gland. It measures approximately 0.7 cm in diameter. Nodule does not disrupt normal shape and/or architecture. Right adrenal measures 1.1 cm at the cranial pole and 0.87 cm at the caudal pole.

Spleen

Spleen is subjectively large in size with a normal smooth capsular contour. Parenchyma is appropriately finely textured and homogenous with normal echogenicity relative to surrounding tissue (hyperechoic to liver). No focal nodules or masses are observed. Splenic vasculature appears normal. The spleen is folded upon itself, which is a positional non-pathologic variant.

Liver

The liver is subjectively normal in size with normal smooth curvilinear peripheral contour. Parenchyma is appropriately hypoechoic to the spleen in echogenicity and appropriately mildly coarse and homogenous in echotexture. No focal lesions are observed. Visible vasculature and biliary tree appear normal without distension or congestion.

Gallbladder is moderately distended with anechoic bile as well as suspended and gravity dependent echogenic debris. The wall is smooth without visible thickening. There is no evidence of cystic or CBD dilation. There is no evidence of effusion or inflammation.

Gastrointestinal



PATIENT

Alta Martin

The visible stomach wall is normal in thickness and layering. The lumen of the stomach is empty with no evidence of obstruction, foreign material or infiltrative disease. Pyloric outflow tract appears patent.

SPECIES

Canine

The visible small intestine demonstrates areas of mildly thick muscularis layer relative to mucosa (disruption of the normal 1:3 muscularis:mucosa ratio). Small intestinal submucosa is slightly irregular, thick and hyperechoic, without evident loss of layering appreciated. The lumen of the small intestine is empty with no evidence of obstruction or foreign material.

BREED

Catahoula Leopard
Dog Mix

The visible colon is normal in wall thickness (< 0.2 cm) and layering. Contents are consistent with normal formed feces and gas.

SEX

FS

Pancreas

The pancreas that is observed appears appropriately isoechoic to surrounding omental fat. Visible capsule is smooth and normal in contour. Visible pancreatic parenchyma is homogenous and unremarkable. There is no visible pancreatic duct dilation. There is no evidence of active peripancreatic inflammation.

AGE

13 years

Free Abdomen

WEIGHT

96 lbs

There is no visible free peritoneal effusion noted in these images.

There is no apparent pathologic lymphadenopathy noted in these images.

INTERPRETED BY

Beth Johnson, DVM
DACVIM

ULTRASONOGRAPHIC FINDINGS

IMAGING PERFORMED BY

Pamela Harrigan,
RDCS

- Bilateral adrenomegaly with hyperechoic adrenal nodule in the cranial pole of the left adrenal gland – In a patient diagnosed with hyperadrenocorticism, this finding is most consistent with adrenal hyperplasia secondary to pituitary dependent hyperadrenocorticism. This finding can also be seen with stress and/or normal patient variant. Interpret in combination with clinical signs of hyperadrenocorticism and/or other adrenal disease. Hyperechoic adrenal nodule – Differentials include primary adrenal cortical adenoma or adenocarcinoma, pheochromocytoma, myelolipoma, adrenal hyperplasia secondary to pituitary disease or metastatic disease. Ultrasound alone cannot differentiate between functional and non-functional nodules and/or between benign and malignant disease. Small nodules without other evidence of abdominal disease (to suggest metastatic disease) and/or clinical signs (to suggest adrenal disease) are most often incidental and should be monitored.
- Mild gallbladder debris - Cholecystic debris is of unknown clinical significance. It can be seen with biliary stasis from fasting or illness. Cholecystic debris is not necessarily related to hepatobiliary disease. Echogenic bile is most commonly an incidental finding in dogs and should be interpreted in combination with clinical signs such as nausea, inappetence, cranial abdominal discomfort and/or laboratory changes such as increased ALP and/or increased Tbili.
- Mild/emerging inflammatory bowel disease (IBD) pattern – Thick muscularis has been reported with infiltrative bowel disease including both benign inflammatory disease as well as infiltrative neoplasia such as lymphoma. No loss of layering or distinct characteristics of malignancy are present. Therefore, differentials cannot be further ranked without tissue sampling.

HOSPITAL NAME

Littleton Animal
Hospital

REFERRING VET

Dr. Tatyana Kalani

INVOICE

11305

DATE

2/12/2026



PATIENT

Alta Martin

SPECIES

Canine

BREED

Catahoula Leopard
Dog Mix

SEX

FS

AGE

13 years

WEIGHT

96 lbs

INTERPRETED BY

Beth Johnson, DVM
DACVIM

**IMAGING
PERFORMED BY**

Pamela Harrigan,
RDCS

HOSPITAL NAME

Littleton Animal
Hospital

REFERRING VET

Dr. Tatyana Kalani

INVOICE

11305

DATE

2/12/2026

- Mild splenomegaly- can be associated with congestion caused by sedation (if sedated) but can also be associated with diffuse infiltrative disease. Both benign conditions such as extramedullary hematopoiesis, lymphoid hyperplasia as well as infiltrative neoplastic diseases such as round cell neoplasia should be considered.

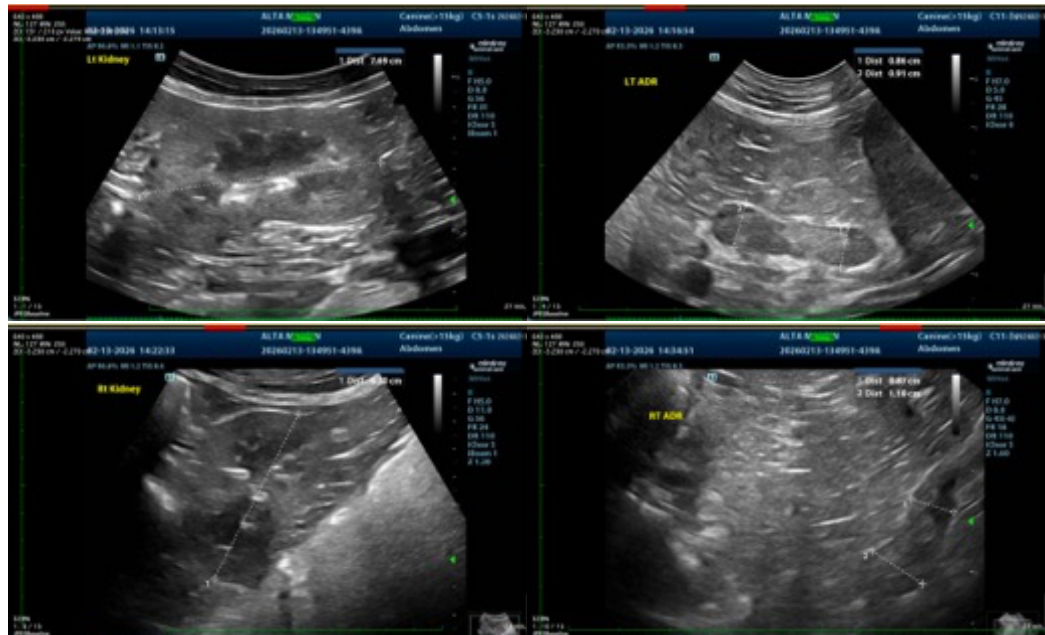
INTERPRETATION OF THE FINDINGS & FURTHER RECOMMENDATIONS

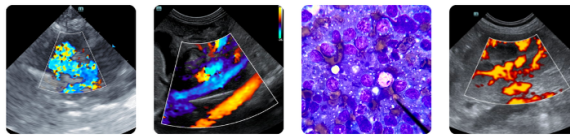
Further recommendations for patient's reportedly increased liver enzymes, given the changes described above, depend in large part on patient's clinical history. If clinical signs of hyperadrenocorticism are present, then hormone testing would be warranted beginning with a low dose dexamethasone suppression test. Additionally, regardless of clinical signs, a blood pressure is recommended. As is, if not recently evaluated, urinalysis and, if indicated based on urinalysis results, urine culture is recommended. If protein is present in an otherwise quiet sediment, protein quantification with a urine protein to creatinine ration is recommended.

Given the reported liver enzyme changes, bile acids could be considered if patient's total bilirubin is not increased.

Finally, given the mild bowel changes, in the face of any clinical gastrointestinal history including unintentional weight loss, vomiting, diarrhea, etc., further gastrointestinal workup may also be warranted. Beginning with a routine/fecal giardia exam if not recently evaluated. A gastrointestinal malabsorption panel (including cobalamin, folate, TLI and PLI) to Texas A&M GI Laboratory is recommended for further evaluation of GI and pancreatic function.

Other than supportive/symptomatic medical management of clinical signs, further treatment recommendations are largely dependent on results of the above.





PATIENT

Alta Martin

SPECIES

Canine

BREED

Catahoula Leopard
Dog Mix

SEX

FS

AGE

13 years

WEIGHT

96 lbs

INTERPRETED BY

Beth Johnson, DVM
DACVIM

**IMAGING
PERFORMED BY**

Pamela Harrigan,
RDCS

HOSPITAL NAME

Littleton Animal
Hospital

REFERRING VET

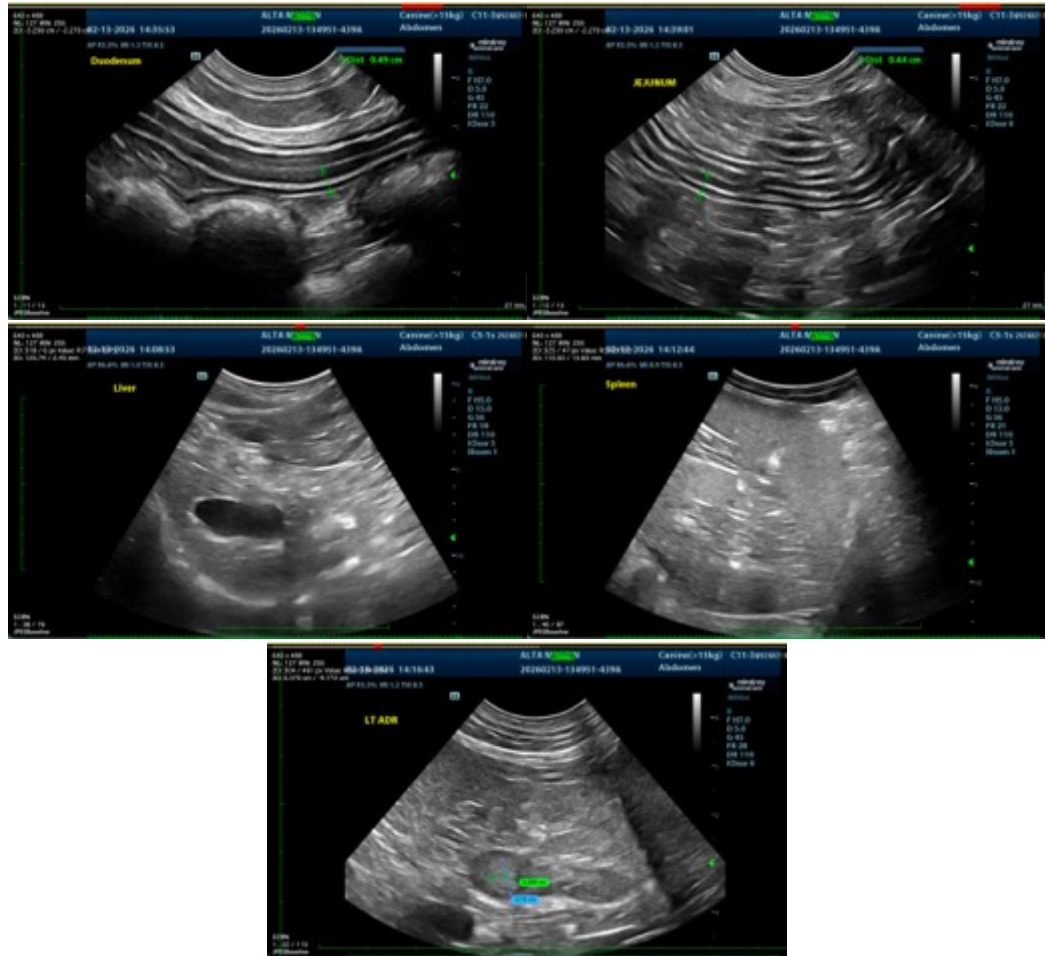
Dr. Tatyana Kalani

INVOICE

11305

DATE

2/12/2026



The information and recommendations provided are based on the images presented by the referring veterinarian/sonographer. No evaluation can be communicated regarding pathology that was not visible in the image/video clips provided.

Thank you for this referral. If the clinical or image interpretation does not parallel your findings or if I can be of any further assistance please contact me.

Beth Johnson, DVM, DACVIM
info@sonopath.com