

PATIENT

Willow Huff

SPECIES

Canine

BREED

Golden Retriever

SEX

Sayed Female

AGE

5 Years 11 Months

WEIGHT

71

INTERPRETED BY

Beth Johnson, DVM
DACVIM

IMAGING PERFORMED BY

Dr. Abadia

HOSPITAL NAME

Surfside Pet Hospital

REFERRING VET

Dr. Americo Abadia

INVOICE

72827

DATE

2/10/26

PRESENTING CLINICAL SIGNS

Owner been proactive and wants to scan pet yearly due to pets mom had spleen cancer in past. Pet is doing well , no history of abnormal BW

Abnormal PE/Chem/CBC/UA Results: Last BW feb 2025 - showed only a mild elevation on tbili- 0.3 , normal t4, normal cbc and normal u/a

ULTRASONOGRAPHIC EXAMINATION OF THE ABDOMEN

Urinary System

The urinary bladder is adequately distended with anechoic contents. No masses, inflammatory changes, echogenic sediment or cystoliths are observed. The urinary bladder, trigone and visible pelvic urethra are normal in thickness with a smooth mucosal surface.

The right kidney is normal is size (6.4 cm), shape and echogenicity. It has smooth peripheral margination. There is a normal 1:3 cortex to medulla ratio with appropriate corticomedullary distinction. There is no evidence of pyelectasia, mineral or infarcts observed.

The left kidney is normal is size (6.07 cm), shape and echogenicity. It has smooth peripheral margination. There is a normal 1:3 cortex to medulla ratio with appropriate corticomedullary distinction. There is no evidence of pyelectasia, mineral or infarcts observed.

Adrenal Glands

The right adrenal gland is normal in size (0.56 cm at cranial pole and 0.45 cm at caudal pole), shape and overall architecture, echogenicity and echotexture. Visible surrounding vasculature appears normal.

The left adrenal gland is normal in size (0.28 cm at cranial pole and 0.45 cm at caudal pole), shape and overall architecture, echogenicity and echotexture. Visible surrounding vasculature appears normal.

Spleen

The spleen is subjectively normal in size with a normal smooth capsular contour. Parenchyma is appropriately finely textured and homogenous with normal echogenicity relative to surrounding tissue (hyperechoic to liver). No focal nodules or masses are observed. Splenic vasculature appears normal.


Liver

The liver is subjectively normal in size with normal smooth curvilinear peripheral contour. Parenchyma is appropriately hypoechoic to the spleen in echogenicity and appropriately mildly coarse and homogenous in echotexture. No focal lesions are observed. Visible vasculature and biliary tree appear normal without distension or congestion.

The gallbladder is non-distended in size. The wall is smooth without visible thickening. Luminal contents are primarily anechoic. There is no evidence of cystic or common bile duct dilation.

Gastrointestinal

The visible stomach wall is normal in thickness and layering. The lumen of the stomach is empty with no evidence of obstruction, foreign material or infiltrative disease. Pyloric outflow tract appears patent.



PATIENT

Willow Huff

SPECIES

Canine

BREED

Golden Retriever

SEX

Sayed Female

AGE

5 Years 11 Months

WEIGHT

71

INTERPRETED BY

Beth Johnson, DVM
DACVIM

IMAGING PERFORMED BY

Dr. Abadia

HOSPITAL NAME

Surfside Pet Hospital

REFERRING VET

Dr. Americo Abadia

INVOICE

72827

DATE

2/10/26

The visible small intestines are normal in wall thickness and layering. Small intestinal motility appears adequate (1-3 contractions per min). The lumen of the small intestine is empty with no evidence of obstruction, foreign material or infiltrative disease.

The visible colon is normal in wall thickness (< 0.2 cm) and layering. Contents are consistent with normal formed feces and gas.

Pancreas

The pancreas that is observed appears appropriately isoechoic to surrounding omental fat. Visible capsule is smooth and normal in contour. Visible pancreatic parenchyma is homogenous and unremarkable. There is no visible pancreatic duct dilation. There is no evidence of active peripancreatic inflammation.

Free Abdomen

There is no visible free peritoneal effusion noted in these images.

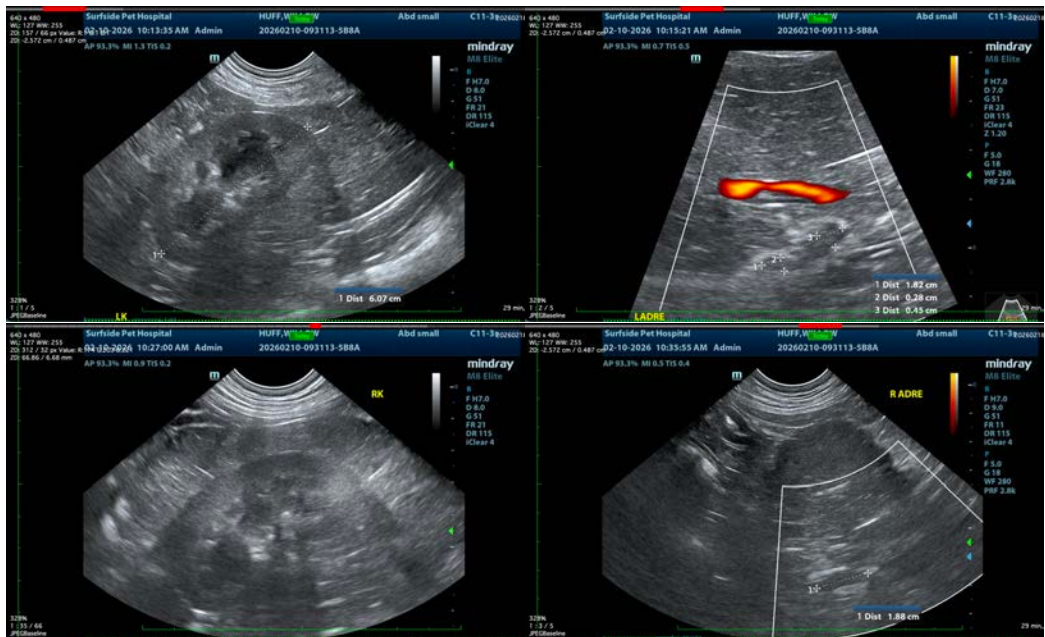
There is no apparent pathologic lymphadenopathy noted in these images.

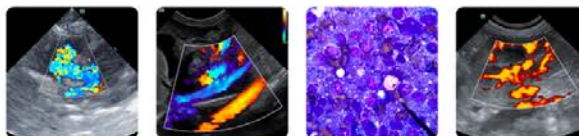
ULTRASONOGRAPHIC FINDINGS

- This is a largely unremarkable/structurally normal abdomen.

INTERPRETATION OF THE FINDINGS & FURTHER RECOMMENDATIONS

There are no specific follow up recommendations based on patient's provided history and this largely unremarkable ultrasound.





PATIENT

Willow Huff

SPECIES

Canine

BREED

Golden Retriever

SEX

Sayed Female

AGE

5 Years 11 Months

WEIGHT

71

INTERPRETED BY

Beth Johnson, DVM
DACVIM

IMAGING PERFORMED BY

Dr. Abadia

HOSPITAL NAME

Surfside Pet Hospital

REFERRING VET

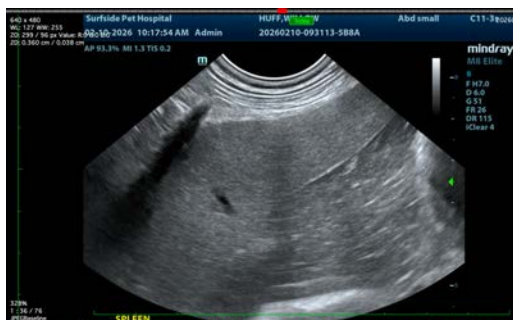Dr. Americo Abadia

INVOICE

72827

DATE

2/10/26



The information and recommendations provided are based on the images presented by the referring veterinarian/sonographer. No evaluation can be communicated regarding pathology that was not visible in the image/video clips provided.

Thank you for this referral. If the clinical or image interpretation does not parallel your findings or if I can be of any further assistance please contact me.

Beth Johnson, DVM, DACVIM
info@sonopath.com