



PATIENT

Millie Dyal

SPECIES

Canine

BREED

Goldendoodle

SEX

Spayed Female

AGE

9 Years

WEIGHT

34 lbs

INTERPRETED BY

Beth Johnson, DVM
DACVIM

IMAGING PERFORMED BY

Julia Bakker, DVM

HOSPITAL NAME

Orange Blossom
Veterinary Imaging

REFERRING VET

Kristie Johns, DVM

INVOICE

72864

DATE

2/10/26

PRESENTING CLINICAL SIGNS

Recent multi-day episode of fever, hematuria and proteinuria and leukocytosis with an otherwise normal labwork and unremarkable radiographs. Patient responded to IV fluids and a two week course of simplicef and enrofloxacin. Patient is now doing well with normal cbc and ua on recheck. screening for possible pyelonephritis or other causes of fever that might help dictate when to stop antibiotics.

ULTRASONOGRAPHIC EXAMINATION OF THE ABDOMEN

Urinary System

The urinary bladder is adequately distended with anechoic contents. No masses, inflammatory changes, echogenic sediment or cystoliths are observed. The urinary bladder, trigone and visible pelvic urethra are normal in thickness with a smooth mucosal surface.

The right kidney is normal is size (5.36 cm), shape and echogenicity. It has smooth peripheral margination. There is a normal 1:3 cortex to medulla ratio with appropriate corticomedullary distinction. There is no evidence of pyelectasia, mineral or infarcts observed.

The left kidney is normal is size (5.06 cm), shape and echogenicity. It has smooth peripheral margination. There is a normal 1:3 cortex to medulla ratio with appropriate corticomedullary distinction. There is no evidence of pyelectasia, mineral or infarcts observed.

Adrenal Glands

The right adrenal gland is normal in size (0.57 cm at cranial pole and 0.86 cm at caudal pole), shape and overall architecture, echogenicity and echotexture. Visible surrounding vasculature appears normal.

The left adrenal gland is normal in size (0.70 cm at cranial pole and 0.69 cm at caudal pole), shape and overall architecture, echogenicity and echotexture. Visible surrounding vasculature appears normal.

Spleen

The spleen is subjectively normal in size with a normal smooth capsular contour. Parenchyma is appropriately finely textured and homogenous with normal echogenicity relative to surrounding tissue (hyperechoic to liver). No focal nodules or masses are observed. Splenic vasculature appears normal.

Liver

The liver is subjectively normal in size with normal smooth curvilinear peripheral contour. Parenchyma is appropriately hypoechoic to the spleen in echogenicity and appropriately mildly coarse and homogenous in echotexture. No focal lesions are observed. Visible vasculature and biliary tree appear normal without distension or congestion.

Gallbladder is moderately distended with anechoic bile as well as suspended and gravity dependent echogenic debris. The wall is smooth without visible thickening. There is no evidence of cystic or CBD dilation. There is no evidence of effusion or inflammation.

Gastrointestinal

The visible stomach wall is normal in thickness and layering. The lumen of the stomach is empty with no evidence of obstruction, foreign material or infiltrative disease. Pyloric outflow tract appears patent.



PATIENT

Millie Dyal

The visible small intestines are normal in wall thickness and layering. Small intestinal motility appears adequate (1-3 contractions per min). The lumen of the small intestine is empty with no evidence of obstruction, foreign material or infiltrative disease.

SPECIES

Canine

The visible colon is normal in wall thickness (< 0.2 cm) and layering. Contents are consistent with normal formed feces and gas.

BREED

Goldendoodle

Pancreas

The pancreas that is observed appears appropriately isoechoic to surrounding omental fat. Visible capsule is smooth and normal in contour. Visible pancreatic parenchyma is homogenous and unremarkable. There is no visible pancreatic duct dilation. There is no evidence of active peripancreatic inflammation.

SEX

Spayed Female

Free Abdomen

There is no visible free peritoneal effusion noted in these images.

AGE

9 Years

There is no apparent pathologic lymphadenopathy noted in these images.

WEIGHT

34 lbs

ULTRASONOGRAPHIC FINDINGS

- Mild gallbladder debris - Cholecystic debris is of unknown clinical significance. It can be seen with biliary stasis from fasting or illness. Cholecystic debris is not necessarily related to hepatobiliary disease. Echogenic bile is most commonly an incidental finding in dogs and should be interpreted in combination with clinical signs such as nausea, inappetence, cranial abdominal discomfort and/or laboratory changes such as increased ALP and/or increased Tbili.

INTERPRETED BY

Beth Johnson, DVM
DACVIM

INTERPRETATION OF THE FINDINGS & FURTHER RECOMMENDATIONS

This is a largely unremarkable/structurally normal abdomen with no definitive ultrasonographically visible evidence of pyelonephritis or other causes of patient's historical fever and clinical signs present in these images at this time. Given the reported clinical and laboratory resolution of abnormalities, discontinuation of antibiotics may be appropriate. However, subjectively I typically continue antibiotics for 1-2 weeks beyond full remission, depending on the underlying diagnosis, full clinical picture, etc.

IMAGING PERFORMED BY

Julia Bakker, DVM

HOSPITAL NAME

Orange Blossom
Veterinary Imaging

REFERRING VET

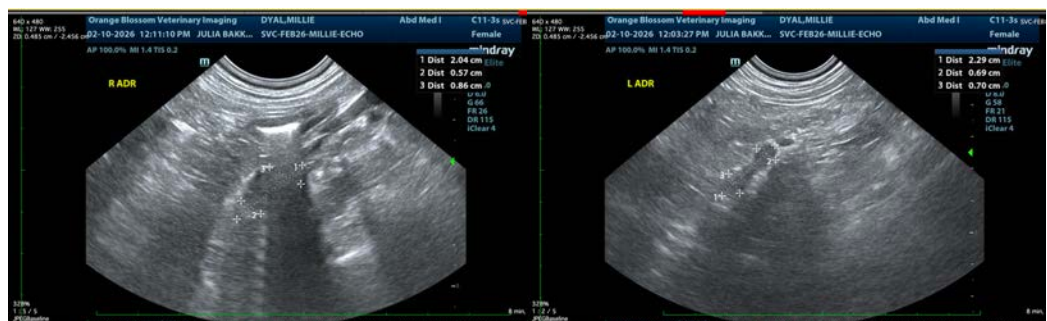Kristie Johns, DVM

INVOICE

72864

DATE

2/10/26





PATIENT

Millie Dyal

SPECIES

Canine

BREED

Goldendoodle

SEX

Spayed Female

AGE

9 Years

WEIGHT

34 lbs

INTERPRETED BY

Beth Johnson, DVM
DACVIM

IMAGING PERFORMED BY

Julia Bakker, DVM

HOSPITAL NAME

Orange Blossom
Veterinary Imaging

REFERRING VET

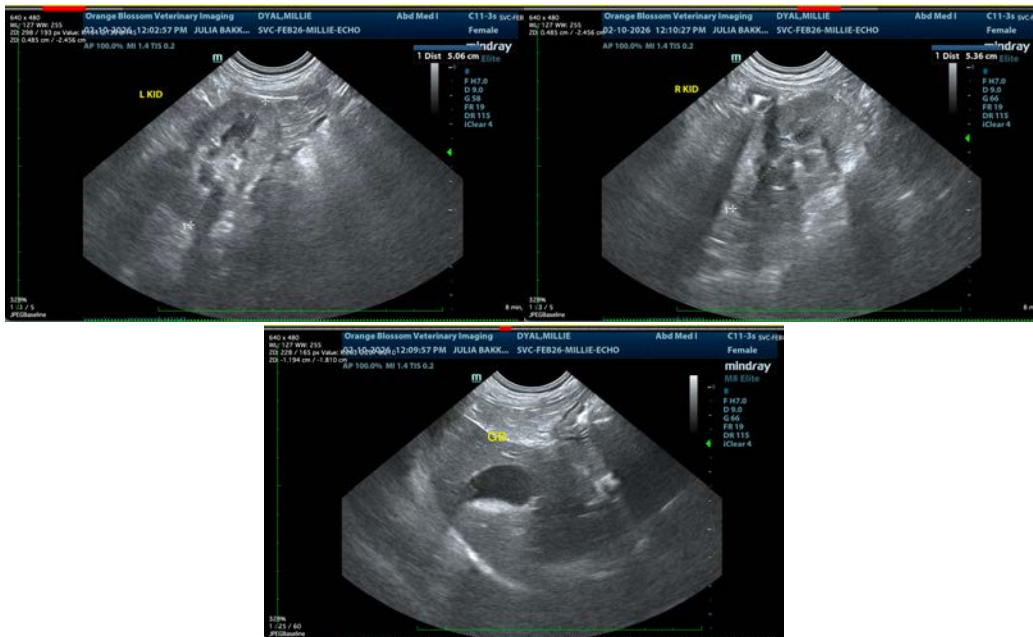
Kristie Johns, DVM

INVOICE

72864

DATE

2/10/26



The information and recommendations provided are based on the images presented by the referring veterinarian/sonographer. No evaluation can be communicated regarding pathology that was not visible in the image/video clips provided.

Thank you for this referral. If the clinical or image interpretation does not parallel your findings or if I can be of any further assistance please contact me.

Beth Johnson, DVM, DACVIM
info@sonopath.com