



**PATIENT**

Bella Solano

**SPECIES**

Canine

**BREED**

Maltese

**SEX**

Spayed Female

**AGE**

10 Years

**WEIGHT**

6.1

**INTERPRETED BY**

Beth Johnson, DVM  
DACVIM

**IMAGING PERFORMED BY**

Jessica Green

**HOSPITAL NAME**

Stanglein Vet Clinic

**REFERRING VET**

Dr. Laura Green

**INVOICE**

44676

**DATE**

2/1/23

**PRESENTING CLINICAL SIGNS**

Came in for coughing 1/27/23, new murmur ausc, chest rads ok. Sent out bloodwork. Current meds: denamarin, was sent home with Tamaril P this visit but not on it when blood drawn.

Abnormal PE/Chem/CBC/UA Results: ALT 472, AlkP 1139 (one year ago ALT 282 and AlkP 324)... Chest rads wnl.

**ULTRASONOGRAPHIC EXAMINATION OF THE ABDOMEN**

**Urinary System**

Urinary bladder is adequately distended. It has a normal uniform wall thickness. Contents include primarily anechoic fluid with occasional echogenic non-shadowing debris, most consistent with exfoliated cells, mucous and/or small blood clots. Both sterile inflammation as well as urinary tract infection can also present with echogenic debris. No masses or cystoliths are observed. The trigone and visible pelvic urethra are normal in thickness with a smooth mucosal surface.

The right kidney is normal in size (3.45 cm), shape and echogenicity. It has smooth peripheral margination. There is a normal 1:3 cortex to medulla ratio with appropriate corticomedullary distinction. There is no evidence of pyelectasia, mineral or infarcts observed. A hyperechoic band parallel to the corticomedullary border is present.

The left kidney is normal in size (3.2 cm), shape and echogenicity. It has smooth peripheral margination. There is a normal 1:3 cortex to medulla ratio with appropriate corticomedullary distinction. There is no evidence of pyelectasia, mineral or infarcts observed. A hyperechoic band parallel to the corticomedullary border is present.

**Adrenal Glands**

The right adrenal gland is normal in size (1.5 cm long x 0.38 cm at the cranial pole and 0.37 cm at the caudal pole), shape and contour. Corticomedullary structure is unremarkable. Visible surrounding vasculature appears normal.

The left adrenal gland is normal in size (0.43 cm at the cranial pole and 0.43 cm at the caudal pole), shape and contour. Corticomedullary structure is unremarkable. Visible surrounding vasculature appears normal.

**Spleen**

The spleen is subjectively normal in size with a normal smooth capsular contour. Parenchyma is appropriately finely textured and homogenous with normal echogenicity relative to surrounding tissue (hyperechoic to liver). No focal nodules or masses are observed. Splenic vasculature appears normal.

**Liver**

Liver is subjectively enlarged with mildly irregular margins. Parenchyma is heterogenous characterized by multiple poorly defined hypoechoic nodules within otherwise hyperechoic liver parenchyma. Visible vasculature and biliary tree appear normal without distension or congestion.

The gallbladder is non-distended in size. The wall is smooth without visible thickening. Luminal contents are primarily anechoic. There is no evidence of cystic or common bile duct dilation.

**Gastrointestinal**



**PATIENT**

Bella Solano

The stomach wall is normal in thickness (canine < 0.5 cm and feline < 0.4 cm) and layering. The lumen of the stomach is empty with no evidence of obstruction, foreign material or infiltrative disease. Pyloric outflow tract appears patent.

**SPECIES**

Canine

The visible small intestines are normal in wall thickness and layering. Hyperechoic mucosal fogging or speckling is noted. Small intestinal motility appears adequate (1-3 contractions per min). The lumen is empty with no evidence of obstruction or foreign material.

**BREED**

Maltese

The visible colon is normal in wall thickness (< 0.2 cm) and layering. Contents are consistent with normal formed feces and gas.

**Pancreas**

**SEX**

Spayed Female

The pancreatic parenchyma is appropriately isoechoic to surrounding tissue. Visible capsule is smooth and normal in contour. There is no visible pancreatic duct dilation. There is no evidence of active peripancreatic inflammation.

**AGE**

10 Years

**Free Abdomen**

**WEIGHT**

6.1

There is no evidence of free peritoneal effusion noted in these images.

There is no apparent lymphadenopathy noted in these images.

**PRIMARY FINDINGS**

**INTERPRETED BY**

Beth Johnson, DVM  
DACVIM

- **Bilateral medullary rim sign** - This finding is of unknown clinical significance and can be a normal variant, often idiopathic. Medullary rim sign can be present with renal disease including FIP, lymphoma, hypercalcemic nephropathy, Leptospirosis, tubular disease, other and should be interpreted in combination with other more specific indications of kidney disease such as isosthenuria, proteinuria, azotemia, etc. This is a common incidental finding in patients with diabetes mellitus.

**IMAGING PERFORMED BY**

Jessica Green

- **Mucosal speckling** - Mucosal speckling is often present with inflammatory bowel disease (IBD). It is not specific for type or severity of disease. Mild speckling change can occur as a normal patient variant in the post-prandial state.

**HOSPITAL NAME**

Stanglein Vet Clinic

- **Heterogenous Liver** - These changes are most consistent with benign processes such as nodular hyperplasia, steroid (vacuolar) hepatopathy, extramedullary hematopoiesis or possibly chronic inflammatory disease and less commonly infiltrative round cell or metastatic neoplasia.

**REFERRING VET**

Dr. Laura Green

**SECONDARY FINDINGS**

- Urinary bladder debris

**INVOICE**

44676

**INTERPRETATION OF THE FINDINGS & FURTHER RECOMMENDATIONS**

In general, the pathology described above is subtle/benign and likely of minimal clinical significance, and certainly unrelated to the presenting complaint of cough.

**DATE**

2/1/23

Having said that, given the appearance of this patient's kidneys combined with the increased liver enzymes, testing for Leptospirosis is recommended to definitively rule it out.

Additionally, if not recently evaluated, a urinalysis and, if indicated based on urinalysis results, urine culture are recommended. If protein is present in an otherwise quiet sediment, protein quantification with a urine protein to creatinine ration is recommended.



**PATIENT**

Bella Solano

Given the bowel changes described above, this patient could have an emerging infiltrative bowel disease that is subclinical but resulting in a reactive hepatopathy. Further evaluation of the gastrointestinal tract is recommended with a gastrointestinal malabsorption panel (including cobalamin, folate, TLI and PLI) to Texas A&M GI Laboratory.

**SPECIES**

Canine

Beyond that, differentials for increased ALP are vast and non-specific. Differentials include, but are not limited to, benign nodular hyperplasia which occurs in 70% of older dogs and often does not result in an abnormal ultrasound, reactive or idiopathic/vacuolar hepatopathy, cholestasis and/or hyperadrenocorticism as well as many chronic non-hepatobiliary diseases such as chronic infections/inflammation from dental disease, IBD, neoplasia, hyperlipidemia, hypothyroidism, chronic pancreatitis, chronic stress, etc.

**BREED**

Maltese

**SEX**

Spayed Female

There is no ultrasonographic evidence of cholestasis. Adrenocortical testing such as a low dose dexamethasone suppression test could be considered if clinical signs of hyperadrenocorticism are present. Ursodiol could be considered if gallbladder sludge is noted. A fine needle aspirate of the liver could be considered if patient's coagulation status is appropriate. Otherwise, recommendations include addressing any other concurrent disease and monitoring. If values are progressive, recheck imaging is recommended.

**AGE**

10 Years

**WEIGHT**

6.1

**INTERPRETED BY**

Beth Johnson, DVM  
DACVIM

**IMAGING PERFORMED BY**

Jessica Green

**HOSPITAL NAME**

Stanglein Vet Clinic

**REFERRING VET**

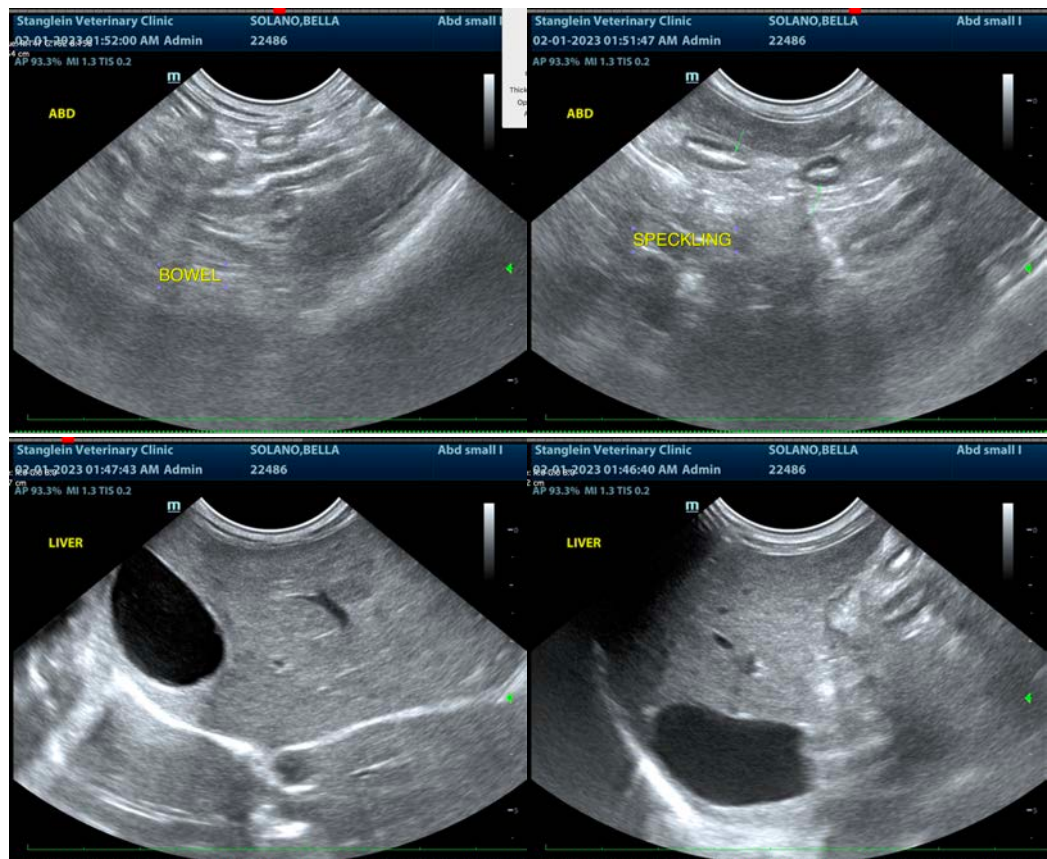
Dr. Laura Green

**INVOICE**

44676

**DATE**

2/1/23





**PATIENT**

Bella Solano

**SPECIES**

Canine

**BREED**

Maltese

**SEX**

Spayed Female

**AGE**

10 Years

**WEIGHT**

6.1

**INTERPRETED BY**

Beth Johnson, DVM  
DACVIM

**IMAGING PERFORMED BY**

Jessica Green

**HOSPITAL NAME**

Stanglein Vet Clinic

**REFERRING VET**

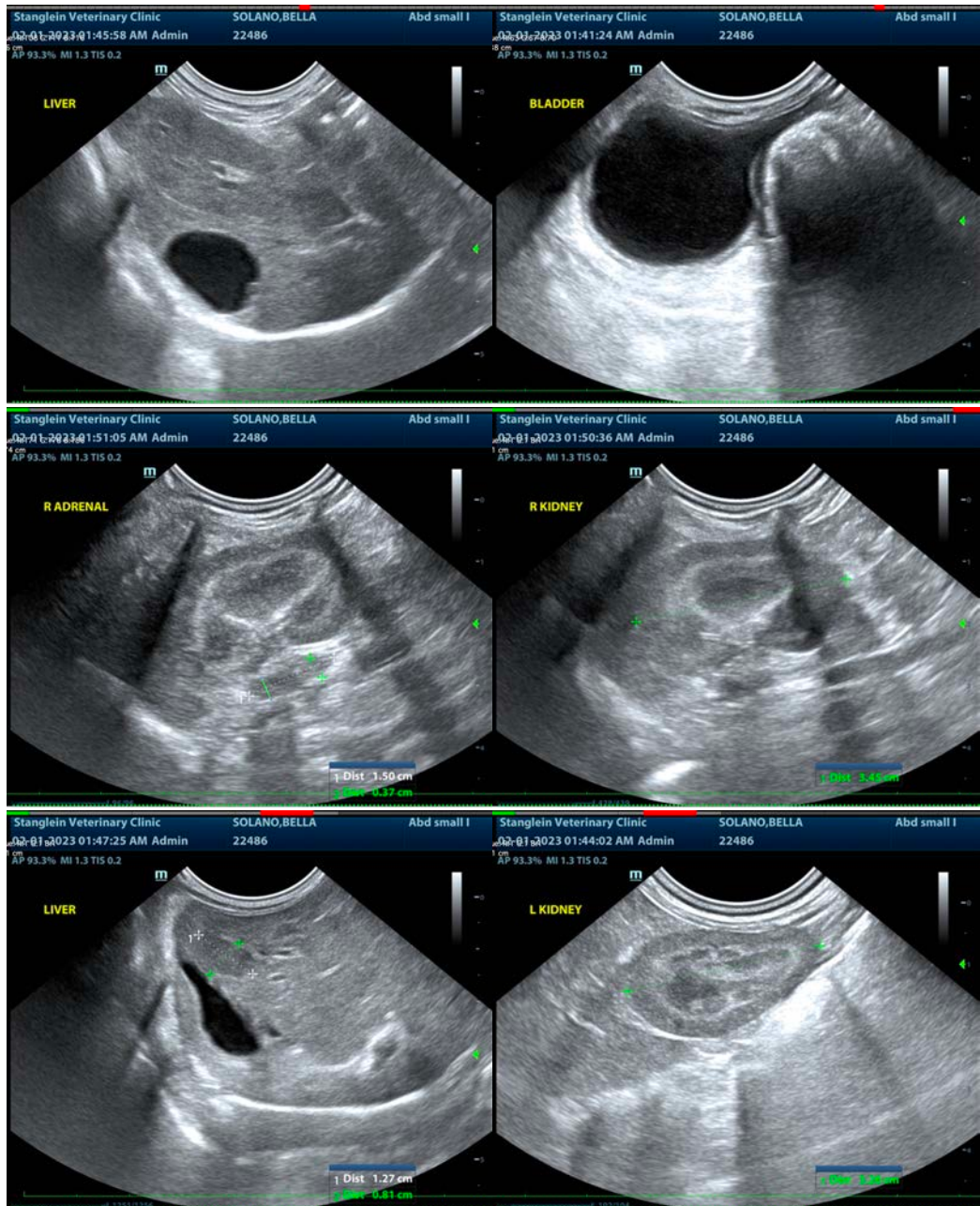
Dr. Laura Green

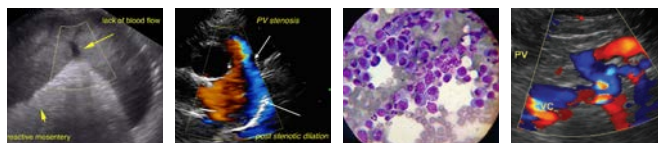
**INVOICE**

44676

**DATE**

2/1/23





**PATIENT**

Bella Solano

**SPECIES**

Canine

**BREED**

Maltese

**SEX**

Spayed Female

**AGE**

10 Years

**WEIGHT**

6.1

**INTERPRETED BY**

Beth Johnson, DVM  
DACVIM

**IMAGING PERFORMED BY**

Jessica Green

**HOSPITAL NAME**

Stanglein Vet Clinic

**REFERRING VET**

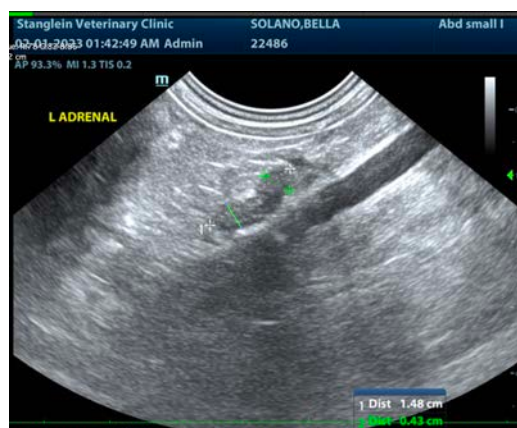Dr. Laura Green

**INVOICE**

44676

**DATE**

2/1/23



The information and recommendations provided are based on the images presented by the referring veterinarian/sonographer. No evaluation can be communicated regarding pathology that was not visible in the image/video clips provided.

Thank you for this referral. If the clinical or image interpretation does not parallel your findings or if I can be of any further assistance please contact me.

**Beth Johnson, DVM, DACVIM**  
Beth.Johnson@sonopath.com