

PATIENT

Wendy Baker

SPECIES

Feline

BREED

DSH

SEX

FS

AGE

10 years

WEIGHT

9.8 lbs

INTERPRETED BY

Beth Johnson, DVM
DACVIM

IMAGING PERFORMED BY

Dr. Jessica Boudreaux-
Milligan

HOSPITAL NAME

Dockside Veterinary
Imaging

REFERRING VET

Dr. Rachel Bouton

INVOICE

10912

DATE

12/9/2025

PRESENTING CLINICAL SIGNS

Unintentional weight loss in a geriatric feline with chronic vomiting, ddx inflammatory vs neoplastic disease.

Abnormal PE/Chem/CBC/UA Results: The thyroid level was found to be normal, Previous medical records are attached to this request.

ULTRASONOGRAPHIC EXAMINATION OF THE ABDOMEN

Urinary System

The urinary bladder is adequately distended with anechoic contents. No masses, inflammatory changes, echogenic sediment or cystoliths are observed. The urinary bladder, trigone and visible pelvic urethra are normal in thickness with a smooth mucosal surface.

The right kidney is normal is size (4.05 cm), shape and echogenicity. It has smooth peripheral margination. There is a normal 1:3 cortex to medulla ratio with appropriate corticomedullary distinction. There is no evidence of pyelectasia, mineral or infarcts observed.

The left kidney is normal is size (4.26 cm), shape and echogenicity. It has smooth peripheral margination. There is a normal 1:3 cortex to medulla ratio with appropriate corticomedullary distinction. There is no evidence of pyelectasia, mineral or infarcts observed.

Adrenal Glands

The areas of the adrenal glands are examined without evident adrenal gland pathology.

Spleen

Spleen is subjectively large in size with a normal smooth capsular contour. Parenchyma is appropriately finely textured and homogenous with normal echogenicity relative to surrounding tissue (hyperechoic to liver). No focal nodules or masses are observed. Splenic vasculature appears normal. The spleen is folded upon itself, which is a positional non-pathologic variant.

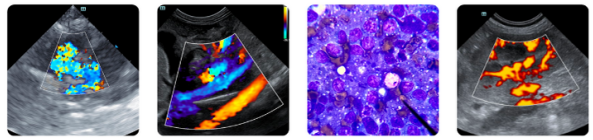
Liver

Liver is subjectively enlarged (swollen contour) without disruption of architecture. It has a normal homogenous echotexture. Parenchyma is diffusely hyperechoic characterized by less prominent than normal portal vein walls and increased echogenicity relative to the spleen and falciform fat. No focal lesions are observed. Visible vasculature and biliary tree appear normal without distension or congestion.

The gallbladder is non-distended in size. The wall is smooth without visible thickening. Luminal contents are primarily anechoic. There is no evidence of cystic or common bile duct dilation.

Gastrointestinal

The visible stomach wall is normal in thickness and layering. The lumen of the stomach is empty with no evidence of obstruction, foreign material or infiltrative disease. Pyloric outflow tract appears patent.



PATIENT

Wendy Baker

The visible small intestines are normal in wall thickness and layering. Small intestinal motility appears adequate (1-3 contractions per min). The lumen of the small intestine is empty with no evidence of obstruction, foreign material or infiltrative disease.

SPECIES

Feline

The visible colon is normal in wall thickness (< 0.2 cm) and layering. Contents are consistent with normal formed feces and gas.

Pancreas

BREED

DSH

Pancreas is prominent (enlarged) in size, hypoechoic to surrounding tissue and has a mildly irregular undulating contour. Parenchyma is coarse with mixed echogenic remodeling noted. No pancreatic duct dilation is noted.

SEX

FS

Free Abdomen

There is no visible free peritoneal effusion noted in these images.

AGE

10 years

Mesenteric lymph nodes are prominent in size with swollen capsular contour. Normal elongated shape (length to width ratio) is maintained. There is no loss of parenchymal detail.

ULTRASONOGRAPHIC FINDINGS

WEIGHT

9.8 lbs

- Splenomegaly– can be associated with congestion caused by sedation (if sedated) but can also be associated with diffuse infiltrative disease. Both benign conditions such as extramedullary hematopoiesis, lymphoid hyperplasia, amyloidosis as well as infiltrative neoplastic diseases such as round cell neoplasia should be considered.
- Hyperechoic hepatomegaly – This appearance could represent an acute hepatopathy or acute cholangiohepatitis, although infiltrative neoplasia including round cell neoplasia can't be ruled out without tissue sampling.
- Chronic low grade smoldering pancreatitis is suspected.
- Very mildly reactive mesenteric lymph nodes – infiltrative neoplastic disease cannot be ruled out but is considered less likely.

INTERPRETED BY

Beth Johnson, DVM
DACVIM

IMAGING PERFORMED BY

Dr. Jessica Boudreaux-
Milligan

HOSPITAL NAME

Dockside Veterinary
Imaging

REFERRING VET

Dr. Rachel Bouton

INTERPRETATION OF THE FINDINGS & FURTHER RECOMMENDATIONS

A gastrointestinal malabsorption panel (including cobalamin, folate, TLI and PLI) to Texas A&M GI Laboratory is recommended for further evaluation of GI and pancreatic function.

Fine needle aspirates of the spleen +/- liver +/- even pancreas could be considered if patient's coagulation status is appropriate.

INVOICE

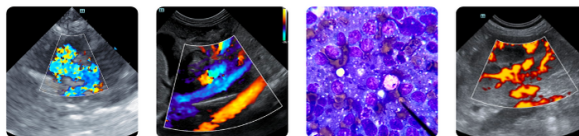
10912

In the meantime, in addition to supportive/symptomatic medical management of clinical signs, empirical deworming with a 5 – day course of Panacur could be considered, as could, if tolerated, a transition in diet is recommended, based on trial-and-error response.

DATE

12/9/2025

Some options to consider include a gastrointestinal biome diet vs a hydrolyzed protein diet (sometimes several trials with different brands are necessary) vs a fiber response/colitis diet vs a bland, easy to digest or low-fat diet vs other.



PATIENT

Wendy Baker

SPECIES

Feline

BREED

DSH

SEX

FS

AGE

10 years

WEIGHT

9.8 lbs

INTERPRETED BY

Beth Johnson, DVM
DACVIM

IMAGING PERFORMED BY

Dr. Jessica Boudreaux-
Milligan

HOSPITAL NAME

Dockside Veterinary
Imaging

REFERRING VET

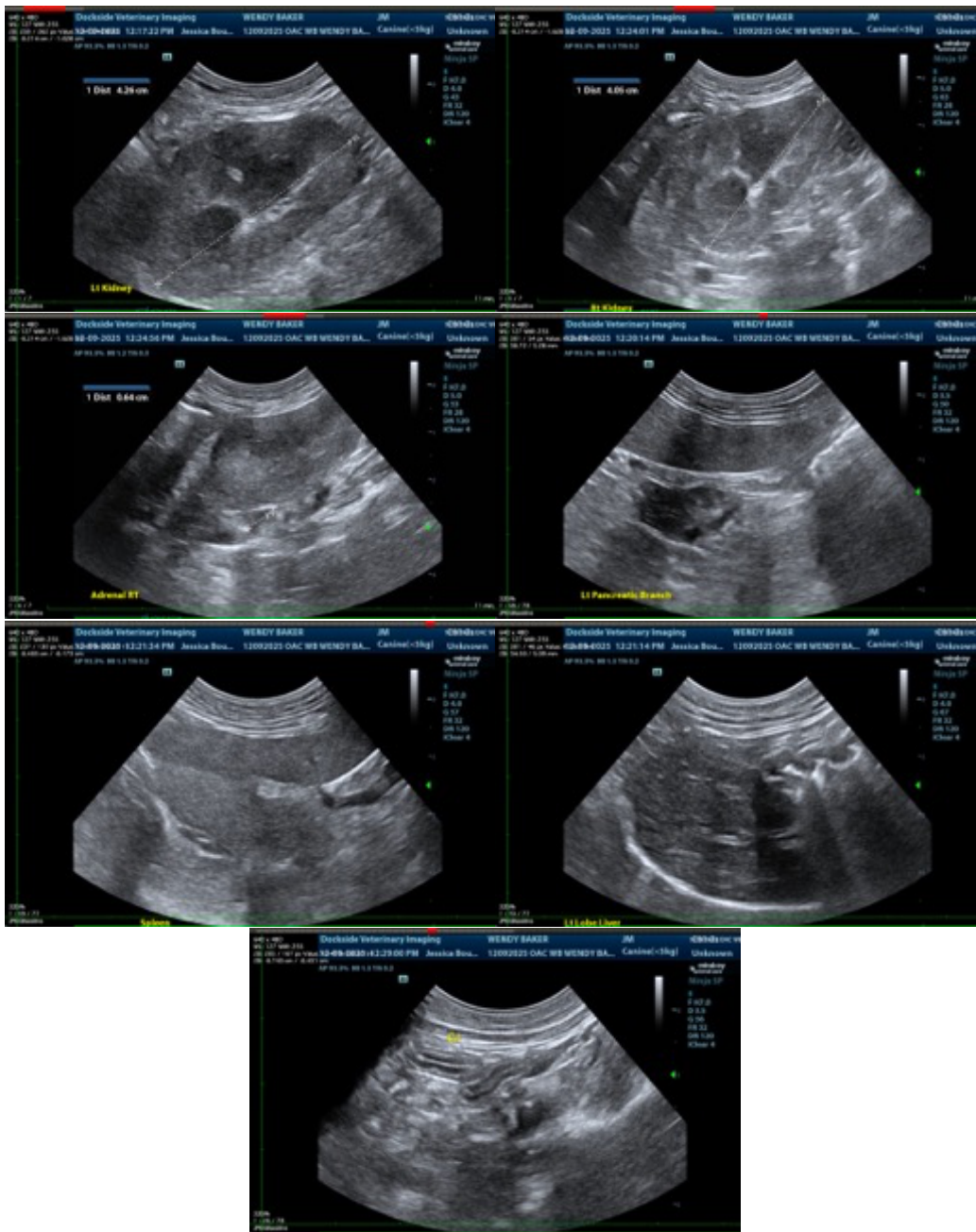
Dr. Rachel Bouton

INVOICE

10912

DATE

12/9/2025



The information and recommendations provided are based on the images presented by the referring veterinarian/sonographer. No evaluation can be communicated regarding pathology that was not visible in the image/video clips provided.

Thank you for this referral. If the clinical or image interpretation does not parallel your findings or if I can be of any further assistance please contact me.

Beth Johnson, DVM, DACVIM

info@sonopath.com