



## DATE PRESENTING CLINICAL SIGNS

12/9/25 **Patient History:** Recent onset PU/PD, increased appetite, waking in the middle of the night to urinate, pant, eat. Working up HAC diagnosis. ACTH stim equivocal. Plan to do AUS then LDDST. Liver enzymes elevated. Also recent episode of pancreatitis that led to 24 hospitalization for a few days.

## PATIENT

Callie Proutt

**Current Medications:** Gabapentin 100mg 1-2 caps PO BID prn

**Labwork Results:** Labwork attached, reported aS: ALT 169, ALP 1249, GGT 15, ACTH stim Pre3.4, post 21.1

**Date of Previous IntraPet Ultrasound:** No previous.

## SPECIES

**Sedation:** Not required to complete full diagnostic ultrasound.

Canine

**Stat Report:** Not requested.

**Imaging Performed by:** Stephanie Warga RDCS, RVT.

## BREED

Beagle

## ULTRASONOGRAPHIC EXAMINATION OF THE ABDOMEN

### Urinary System

## SEX

Spayed Female

Urinary bladder is only mildly distended (empty). Visible contents are anechoic. Urinary bladder wall is unable to be fully assessed for pathology without further distension. No visible masses or definitive cystoliths are observed. The trigone and visible pelvic urethra are normal thickness with a smooth mucosal surface. In the face of urinary signs and/or suspected urinary bladder pathology, reassessment after complete filling is recommended.

## AGE

9/1/12

The right kidney is normal is size (5.91 cm), shape and echogenicity. It has smooth peripheral margination. There is a normal 1:3 cortex to medulla ratio with appropriate corticomedullary distinction. There is no evidence of pyelectasia, mineral or infarcts observed.

## WEIGHT

43.2 lbs

The left kidney is normal is size (5.87 cm), shape and echogenicity. It has smooth peripheral margination. There is a normal 1:3 cortex to medulla ratio with appropriate corticomedullary distinction. There is no evidence of pyelectasia, mineral or infarcts observed.

## INTERPRETED BY

Beth Johnson, DVM  
DACVIM

### Adrenal Glands

## HOSPITAL NAME

Greenbrier Veterinary  
Clinic

The right adrenal gland is normal in size (0.52 cm at cranial pole and 0.45 cm at caudal pole), shape and overall architecture, echogenicity and echotexture. Visible surrounding vasculature appears normal.

The cranial pole of the left adrenal gland measures 0.65 cm. The caudal pole is mildly "plump" measuring 0.96 cm. Normal shape and contour are maintained without evidence of capsular invasion. Corticomedullary structure is unremarkable. Visible surrounding vasculature appears normal.

## REFERRING VET

Dr. Dellinger

### Spleen

## INVOICE

72440

Spleen is subjectively normal in size (1.6 cm thick at the hilus) with normal smooth margins. Parenchyma is normal in echogenicity with a diffusely coarse/heterogenous echotexture. No discrete sizable focal nodules or masses are observed. Splenic vasculature appears normal.

## ***Liver***

Liver is subjectively enlarged with mildly irregular margins. Parenchyma is moderately heterogenous characterized by multiple poorly defined hypoechoic nodules within otherwise hyperechoic liver parenchyma. Visible vasculature and biliary tree appear normal without distension or congestion

Gallbladder is moderately distended with anechoic bile as well as suspended and gravity dependent echogenic debris. The wall is smooth without visible thickening. There is no evidence of cystic or CBD dilation. There is no evidence of effusion or inflammation.

## ***Gastrointestinal***

The visible stomach wall is normal in thickness and layering. The lumen of the stomach is mildly distended with very echogenic reverberation artifact from intraluminal gas. There is no evidence of obstruction, foreign material, or infiltrative disease; however, visualization is partially inhibited by gas.

The visible small intestines are normal in wall thickness and layering. Small intestinal motility appears adequate (1-3 contractions per min). The lumen of the small intestine is mildly distended with very echogenic reverberation artifact from intraluminal gas. There is no evidence of obstruction, foreign material, or infiltrative disease; however, visualization is partially inhibited by gas.

The visible colon is normal in wall thickness (< 0.2 cm) and layering. Contents are consistent with normal formed feces and gas.

## ***Pancreas***

The observed pancreas is prominent (enlarged) in size, hypoechoic to surrounding tissue and irregular in shape with a swollen undulating contour. Enhanced hyperechoic ill-defined surrounding fat is noted.

## ***Free Abdomen***

There is no visible free peritoneal effusion noted in these images.

There is no apparent pathologic lymphadenopathy noted in these images.

## **ULTRASONOGRAPHIC FINDINGS**

- The appearance of the pancreas is concerning for chronic low-grade smoldering pancreatitis, and given the enhanced fat adjacent to the pancreas, potentially resolving acute pancreatitis, given patient's history, is suspected. Ongoing acute inflammation or even an emerging flare up can't be ruled out.
- Moderately heterogenous liver – These changes are most consistent with benign processes such as nodular hyperplasia, steroid (vacuolar) hepatopathy, extramedullary hematopoiesis or possibly chronic inflammatory disease and less commonly infiltrative round cell or metastatic neoplasia.
- Mild gallbladder debris - Cholecystic debris is of unknown clinical significance. It can be seen with biliary stasis from fasting or illness. Cholecystic debris is not necessarily related to hepatobiliary disease. Echogenic bile is most commonly an incidental finding in dogs and should be interpreted in

combination with clinical signs such as nausea, inappetence, cranial abdominal discomfort and/or laboratory changes such as increased ALP and/or increased Tbili.

- Mildly coarse spleen – can be associated with congestion caused by sedation (if sedated) but can also be associated with diffuse infiltrative disease. Both benign conditions such as extramedullary hematopoiesis, lymphoid hyperplasia, as well as infiltrative neoplastic diseases such as round cell neoplasia should be considered.
- Mildly “plump” left adrenal gland could indicate emerging adrenal disease and should be interpreted in combination with patient’s clinical history. Both hyperplasia as well as primary adenoma are differentials, with infiltrative neoplasia possible but considered much less likely.

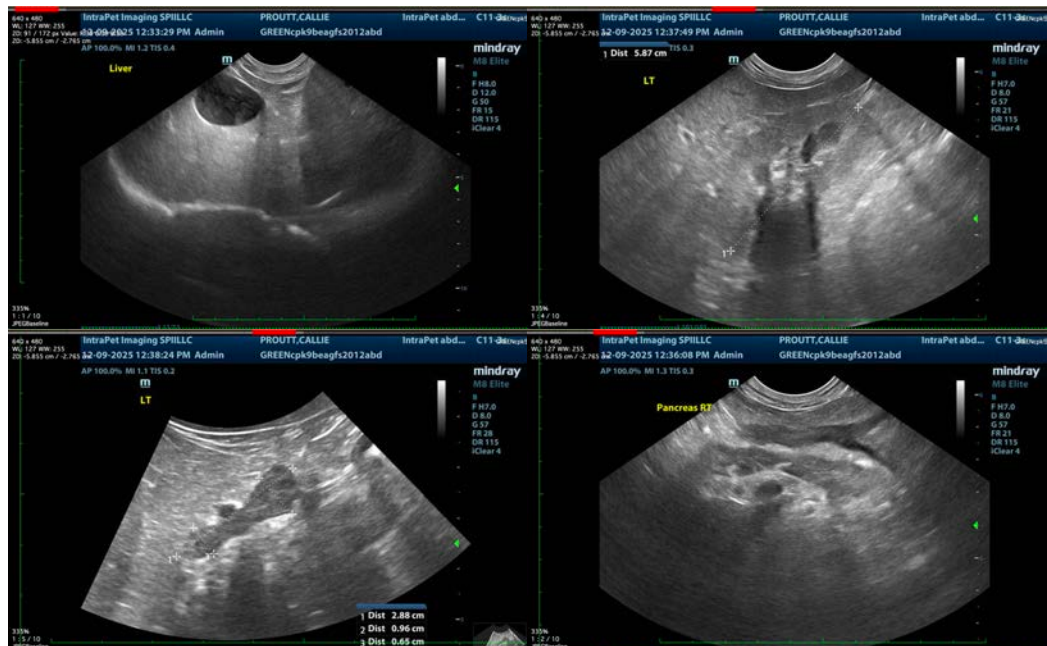
### INTERPRETATION OF THE FINDINGS & FURTHER RECOMMENDATIONS

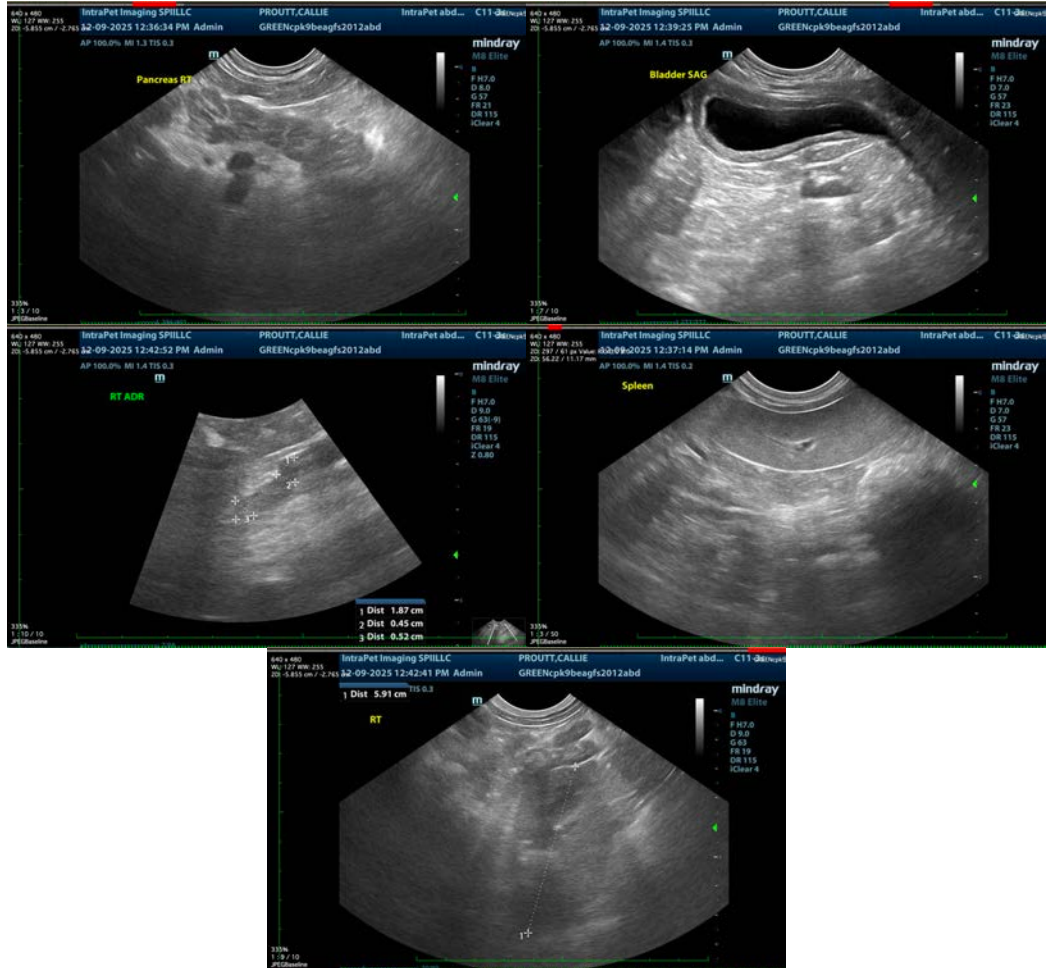
Given patient’s history, if not recently evaluated, a urinalysis and, if indicated based on urinalysis results, urine culture is recommended. If protein is present in an otherwise quiet sediment, protein quantification with a urine protein to creatinine ratio is recommended.

A blood pressure is also recommended.

The mildly “plump” left adrenal gland could indicate (especially when combined with patient’s clinical history) emerging hyperadrenocorticism, most likely pituitary dependent based on the appearance of the adrenal glands. Therefore, hormone testing in the form of a low-dose Dexamethasone suppression test is appropriate.

In the meantime, continued supportive/symptomatic medical management of the pancreatic changes described above are largely dependent on patient’s clinical signs other than (if tolerated) continuing a low-fat diet may be helpful.





The information and recommendations provided are based on the images presented by the referring veterinarian/sonographer. No evaluation can be communicated regarding pathology that was not visible in the image/video clips provided.

Thank you for this referral. If the clinical or image interpretation does not parallel your findings or if I can be of any further assistance please contact me.

**Beth Johnson, DVM, DACVIM**  
info@sonopath.com