

PATIENT

Georgio Stock

SPECIES

Feline

BREED

DSH

SEX

MN

AGE

13 years

WEIGHT

6.8 kg

INTERPRETED BY

Beth Johnson, DVM
DACVIM

**IMAGING
PERFORMED BY**

Loetitia Saint-Jacques,
LVT

HOSPITAL NAME

Incline Veterinary
Hospital

REFERRING VET

Dr. Kateryna Sovik

INVOICE

10901

DATE

12/8/2025

PRESENTING CLINICAL SIGNS

Pt has chronic loose stools (suspected IBD, based on AUS 02/2024). Pt hasn't been managed (still soft stools, but not watery diarrhea) with Prednisolone and royal canin hydrolyzed protein diet. Pt also has moderate lumbosacral degenerative disease, started Solensia treatment for pain management 11/24. Working dx IBD, Prednisolone 3 mg/ml- 2.2 ml PO SID, dose for PT is 1 mg/kg SID; Gabapentin 10 mg/ml once every 8 hours Any additional information Checked Blood glucose 12/2, was elevated at 222mg/dL. Starting to taper down Prednisolone. Is Budesonide a good alternative treatment for IBD?

Abnormal PE/Chem/CBC/UA Results: Bg 222.

ULTRASONOGRAPHIC EXAMINATION OF THE ABDOMEN

Urinary System

Urinary bladder is adequately distended. It has a normal uniform wall thickness. Contents include primarily anechoic fluid with occasional echogenic non-shadowing debris, most consistent with exfoliated cells, mucous and/or small blood clots, as well as dependent mineral "sand" (crystals) debris. Both sterile inflammation as well as urinary tract infection can present with echogenic debris. No masses or discrete definitive cystoliths are observed. The trigone and visible pelvic urethra are normal in thickness with a smooth mucosal surface.

The right kidney is normal is size (4.24 cm), shape and echogenicity. It has smooth peripheral margination. There is a normal 1:3 cortex to medulla ratio with appropriate corticomedullary distinction. There is no evidence of pyelectasia, mineral or infarcts observed.

The left kidney is normal is size (4.13 cm), shape and echogenicity. It has smooth peripheral margination. There is a normal 1:3 cortex to medulla ratio with appropriate corticomedullary distinction. There is no evidence of pyelectasia, mineral or infarcts observed.

Adrenal Glands

The right adrenal gland is normal in size (0.25 cm), shape and overall architecture, echogenicity and echotexture. Visible surrounding vasculature appears normal.

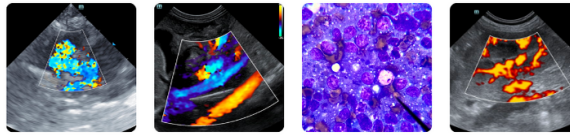
The left adrenal gland is normal in size (0.32 cm), shape and overall architecture, echogenicity and echotexture. Visible surrounding vasculature appears normal.

Spleen

Spleen is subjectively large in size (1.1 cm thick at the hilus) with a mildly swollen but smooth capsule. Parenchyma is normal and homogenous in echogenicity and echotexture. No focal nodules or masses are observed. Splenic vasculature appears normal.

Liver

The liver is subjectively normal in size with normal smooth curvilinear peripheral contour. Parenchyma is appropriately hypoechoic to the spleen in echogenicity and appropriately mildly coarse and homogenous in echotexture. In the mid liver, there is an approximately 1.5 cm x 3.5 cm partially septated, anechoic density. Visible vasculature and biliary tree appear normal without distension or congestion.



PATIENT

Georgio Stock

SPECIES

Feline

BREED

DSH

SEX

MN

AGE

13 years

WEIGHT

6.8 kg

INTERPRETED BY

Beth Johnson, DVM
DACVIM

**IMAGING
PERFORMED BY**

Loetitia Saint-Jacques,
LVT

HOSPITAL NAME

Incline Veterinary
Hospital

REFERRING VET

Dr. Kateryna Sovik

INVOICE

10901

DATE

12/8/2025

The gallbladder is non-distended in size. The wall is smooth without visible thickening. Luminal contents are primarily anechoic. There is no evidence of cystic or common bile duct dilation.

Gastrointestinal

The visible stomach wall is normal in thickness and layering. The lumen of the stomach is mildly distended with very echogenic reverberation artifact from intraluminal gas. There is no evidence of obstruction, foreign material, or infiltrative disease; however, visualization is partially inhibited by gas. The exception to the above is a focal area that appears to be, and is labeled, pylorus. That measures approximately 0.7 cm x 0.4 cm in size and is hypoechoic surrounded by subtle shadowing from the gas. It's difficult to determine whether this density is intramural or luminal content.

The visible small intestine demonstrates areas of moderately thick muscularis layer relative to mucosa (disruption of the normal 1:3 muscularis:mucosa ratio). Small intestinal submucosa is slightly irregular, thick and hyperechoic, without evident loss of layering appreciated. The lumen of the small intestine is empty with no evidence of obstruction or foreign material.

The visible colon is normal. The lumen is diffusely, mildly distended with soft stool.

Pancreas

The pancreas that is observed appears appropriately isoechoic to surrounding omental fat. Visible capsule is smooth and normal in contour. Visible pancreatic parenchyma is homogenous and unremarkable. There is no visible pancreatic duct dilation. There is no evidence of active peripancreatic inflammation.

Free Abdomen

There is no visible free peritoneal effusion noted in these images.

There is no apparent pathologic lymphadenopathy noted in these images.

Assessment of heart base images is included when/if a splenic nodule/mass is present (as a complimentary add on). They are also assessed when a specific request is made for assessment of a limited second cavity (heart base and/or thorax) for an additional charge. Images of the heart (and/or) thorax were not assessed for this study. Please contact us if you would like a second cavity.

PRIMARY FINDINGS

- Mild inflammatory bowel disease (IBD) pattern – Thick muscularis has been reported with infiltrative bowel disease including both benign inflammatory disease as well as infiltrative neoplasia such as lymphoma. No loss of layering, etc. is noted to make lymphoma more probable, but lymphoma cannot be definitively ruled out without tissue sampling.
- The pyloric change described above could represent the same infiltrative with both benign and malignant differentials being possible, or it could be a luminal density, even a piece of kibble versus other.
- Splenomegaly– can be associated with congestion caused by sedation (if sedated) but can also be associated with diffuse infiltrative disease. Both benign conditions such as extramedullary hematopoiesis, lymphoid hyperplasia, amyloidosis as well as infiltrative neoplastic diseases such as round cell neoplasia should be considered.



PATIENT

Georgio Stock

SPECIES

Feline

BREED

DSH

SEX

MN

AGE

13 years

WEIGHT

6.8 kg

INTERPRETED BY

Beth Johnson, DVM
DACVIM

IMAGING PERFORMED BY

Loetitia Saint-Jacques,
LVT

HOSPITAL NAME

Incline Veterinary
Hospital

REFERRING VET

Dr. Kateryna Sovik

INVOICE

10901

DATE

12/8/2025

SECONDARY FINDINGS

- Suspect incidental hepatic cyst. The lesion has progressed in size from the previous study but trends in appearance toward benign.
- A moderate to large amount of echogenic urinary bladder mineral/sand debris.

INTERPRETATION OF THE FINDINGS & FURTHER RECOMMENDATIONS

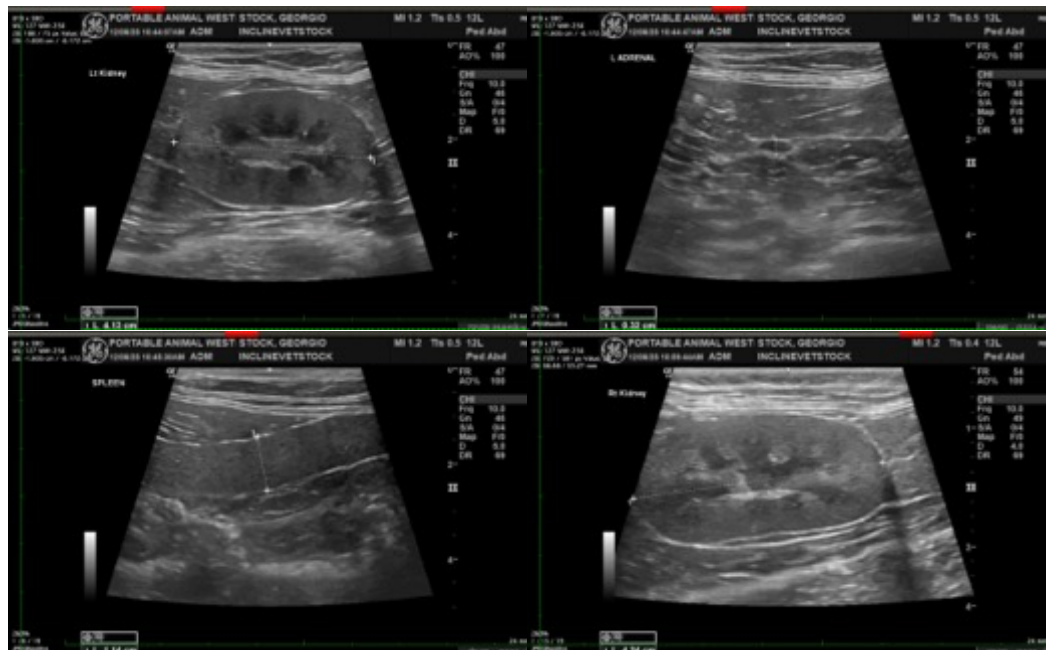
Further recommendations regarding patient's ongoing diarrhea depend largely on what diagnostic process has previously been pursued. If not recently evaluated, a gastrointestinal malabsorption panel (including cobalamin, folate, TLI and PLI) to Texas A&M GI Laboratory is recommended for further evaluation of GI and pancreatic function.

Additionally, a fecal enteropathogen PCR panel to Texas A&M GI Laboratory could be considered for further evaluation of possible infectious disease. Contact lab for recommendations on how long to discontinue antibiotics (if indicated) prior to obtaining a stool sample for submission.

Ultimately, however, tissue sampling may be necessary for a definitive diagnosis and therefore to further guide medical management.

Fine needle aspirates of the spleen could be considered if patient's coagulation status is appropriate or ultimately, biopsies of the GI tract being sure to include ileum, if possible, as well as the atypical area in the pylorus, if it's persistent with follow up imaging.

In the meantime, given patient's steroid therapy and emerging hyperglycemia, a full internal medicine consult and/or referral to an internist, if available, could be considered to help balance medication choices with possible emerging diabetes mellitus.



Imaging
performed by



Portable Animal Wound Sonography, Inc.
pawsonography@gmail.com
530-786-8340



Clinical Sonography & Telectylogy
Educational Teleconsultation Services™

SonoPath

FOSTERING THE ART OF VETERINARY MEDICINE™

SonoPath.com info@sonopath.com 1.800.838.4268

PATIENT

Georgio Stock

SPECIES

Feline

BREED

DSH

SEX

MN

AGE

13 years

WEIGHT

6.8 kg

INTERPRETED BY

Beth Johnson, DVM
DACVIM

IMAGING PERFORMED BY

Loetitia Saint-Jacques,
LVT

HOSPITAL NAME

Incline Veterinary
Hospital

REFERRING VET

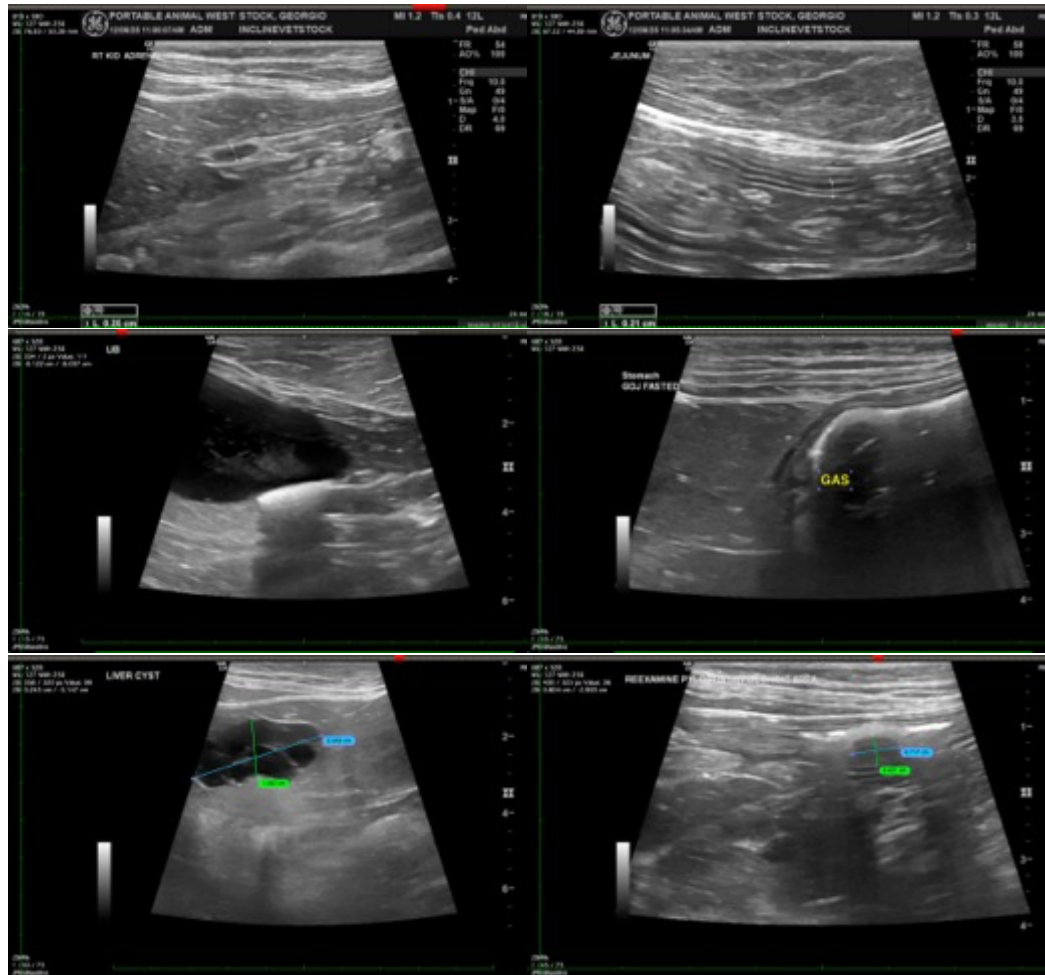
Dr. Kateryna Sovik

INVOICE

10901

DATE

12/8/2025



The information and recommendations provided are based on the images presented by the referring veterinarian/sonographer. No evaluation can be communicated regarding pathology that was not visible in the image/video clips provided.

Thank you for this referral. If the clinical or image interpretation does not parallel your findings or if I can be of any further assistance please contact me.

Beth Johnson, DVM, DACVIM
info@sonopath.com