

IMAGING PERFORMED BY

IntraPet.com



SonoPath

Clinical Sonography & Telecytology

EDUCATIONAL TELECONSULTATION SERVICES™

1-800-838-4268 info@sonopath.com SonoPath.com

DATE PRESENTING CLINICAL SIGNS

12/6/22 Presented to ER for significant ecchymosis ventral abdomen more to the left side, 2in subcutaneous mass left inguinum/medial stifle. PT/PTT and platelets wnl. Cytology of mass nondiagnostic due to hemodilution, blood was immediately aspirated from mass, concern for possible hemangiosarcoma.

PATIENT

Mabel Hollenbach

Current Medications: None listed.
Date of Previous IntraPet Ultrasound: 2/25/20. See attached.
Sedation: Not required to complete full diagnostic ultrasound.
Stat Report: Not requested.

SPECIES

Canine

ULTRASONOGRAPHIC EXAMINATION OF THE ABDOMEN

BREED

Shih Tzu

Urinary System

The urinary bladder is moderately distended with anechoic contents. No masses, inflammatory changes, echogenic sediment or cystoliths are observed. The urinary bladder, trigone and visible pelvic urethra are normal in thickness with a smooth mucosal surface.

SEX

Spayed Female

The right kidney is normal in size (5.04 cm), shape and echogenicity. It has smooth peripheral margination. There is a normal 1:3 cortex to medulla ratio with appropriate corticomedullary distinction. There is no evidence of pyelectasia, mineral or infarcts observed.

AGE

1/25/13

The left kidney is normal in size (4.37 cm), shape and echogenicity. It has smooth peripheral margination. There is a normal 1:3 cortex to medulla ratio with appropriate corticomedullary distinction. There is no evidence of pyelectasia, mineral or infarcts observed.

WEIGHT

15.5 Pounds

Adrenal Glands

The right adrenal gland is enlarged (2.73 cm long x 1.97 cm wide) with mild heterogenous parenchymal changes. Swollen capsular expansion is noted without evident capsular escape. The suspicion for vascular invasion in these images.

INTERPRETED BY

Beth Johnson, DVM
DACVIM

The left adrenal gland is normal in size (2.37 cm long x 0.82 cm at the cranial pole and 0.49 cm at the caudal pole), shape and contour. A hyperechoic nodule is noted in the cranial pole of the left adrenal gland. Nodule does not disrupt normal shape and/or architecture. Visible surrounding vasculature appears normal.

IMAGING PERFORMED BY

Andi Parkinson RDMS

Spleen

The spleen is subjectively normal in size with a normal smooth capsular contour. Parenchyma is appropriately finely textured and homogenous with normal echogenicity relative to surrounding tissue (hyperechoic to liver). No focal nodules or masses are observed. Splenic vasculature appears normal.

HOSPITAL NAME

Perry Hall AH

Liver

The liver is subjectively normal in size with normal smooth curvilinear peripheral contour. Parenchyma is appropriately hypoechoic to the spleen in echogenicity and appropriately mildly coarse and homogenous in echotexture. No focal lesions are observed. Visible vasculature and biliary tree appear normal without distension or congestion.

REFERRING VET

Dr. Baer

INVOICE

43239

The gallbladder is non-distended in size. The wall is smooth without visible thickening. Luminal contents are primarily anechoic. There is no evidence of cystic or common bile duct dilation.

Gastrointestinal

The stomach wall is normal in thickness (canine < 0.5 cm and feline < 0.4 cm) and layering. The lumen of the stomach is empty with no evidence of obstruction, foreign material or infiltrative disease. Pyloric outflow tract appears patent.

The visible small intestines are normal in wall thickness and layering (canine duodenum < 0.5 cm and feline duodenum < 0.4 cm; other < 0.3 cm). Small intestinal motility appears adequate (1-3 contractions per min). The lumen of the small intestine is empty with no evidence of obstruction, foreign material or infiltrative disease.

The visible colon is normal in wall thickness (< 0.2 cm) and layering. Contents are consistent with normal formed feces and gas.

Pancreas

The observed pancreas appears appropriately isoechoic to surrounding omental fat. The capsule is mildly irregular in shape. Parenchyma is mildly heterogenous and coarse. There is no visible pancreatic duct dilation. There is no evidence of active peripancreatic inflammation.

Free Abdomen

There is no evidence of free peritoneal effusion noted in these images.

There is no apparent lymphadenopathy noted in these images.

Other

There is an image provided of the reported subcutaneous inguinal mass, which appears to have a heterogeneous, potentially partially fluid-filled appearance.

ULTRASONOGRAPHIC FINDINGS

- **Pancreatic age-related remodeling** – Mild irregularities are consistent with benign age-related change. Low-grade smoldering chronic pancreatitis cannot be ruled out and should be suspected in the face of appropriate clinical signs.
- **Right adrenal mass with suspect vascular invasion** – Concerning for adenocarcinoma versus pheochromocytoma versus other. A benign adenoma with possible thrombus within the vena cava versus tumor invasion can't be ruled out but is considered less likely.
- **Left adrenal nodule** – Benign in appearance and has not changed since the ultrasound several years ago.

INTERPRETATION OF THE FINDINGS & FURTHER RECOMMENDATIONS

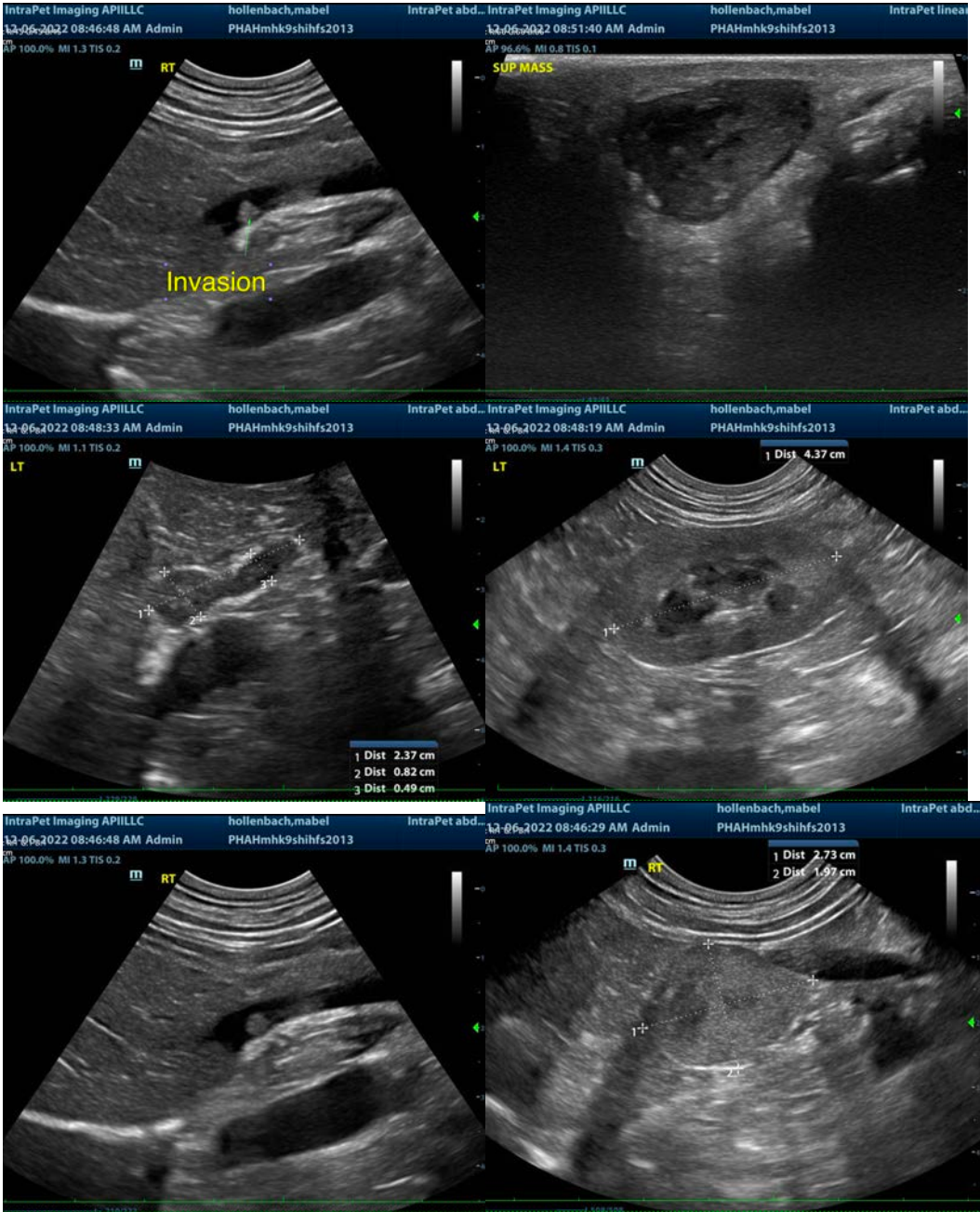
Given the suspicion for potentially two different cancers in this patient, three view thoracic radiographs are recommended for further assessment of cardio-pulmonary status as well as to further evaluate for any evidence of metastatic disease, if not recently evaluated.

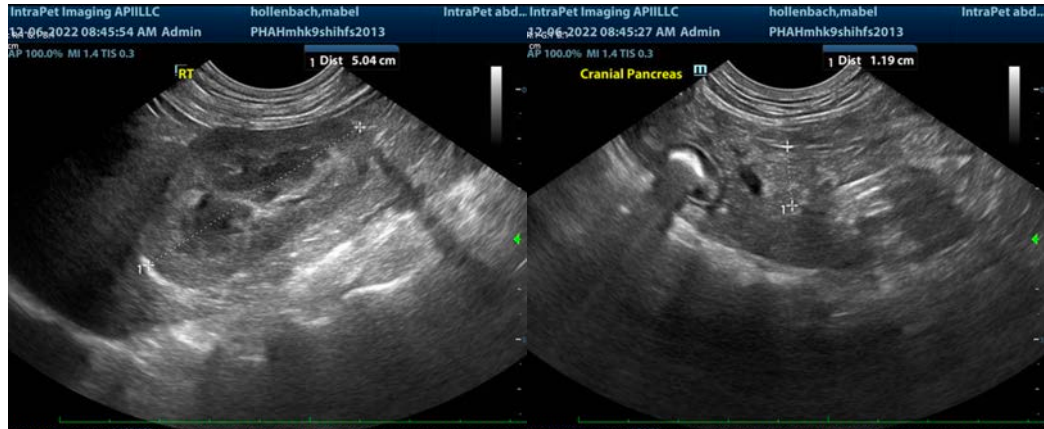
Further adrenal hormone testing in the form of a low-dose Dexamethasone suppression test could be considered, especially if there are clinical signs of hyperadrenocorticism, such as polyuria, polydipsia, etc.

Regardless of clinical signs, given these findings, a urinalysis and, if indicated based on urinalysis results, urine culture are recommended. If protein is present in an otherwise quiet sediment, protein quantification with a urine protein to creatinine ration is recommended.

Blood pressure is also recommended if not recently evaluated.

Ultimately, both a right adrenalectomy as well as removal of the reported subcutaneous inguinal mass are recommended with submission of samples for histopath. If surgery is elected, a pre-surgical planning abdominal CT scan of the adrenal mass is recommended.





The information and recommendations provided are based on the images presented by the referring veterinarian/sonographer. No evaluation can be communicated regarding pathology that was not visible in the image/video clips provided.

Thank you for this referral. If the clinical or image interpretation does not parallel your findings or if I can be of any further assistance please contact me.

Beth Johnson, DVM, DACVIM
Beth.Johnson@sonopath.com