



<b>PATIENT</b>	<b>PRESENTING CLINICAL SIGNS</b>
Kelso Notley	PUPD lately Abnormal PE/Chem/CBC/UA Results: Please see attached BW
<b>SPECIES</b>	<b>ULTRASONOGRAPHIC EXAMINATION OF THE ABDOMEN</b>
Canine	<b>Urinary System</b>  Urinary bladder is adequately distended with primarily anechoic contents and occasional echogenic non-shadowing debris. Apical urinary bladder wall is diffusely thick. (0.50 cm) Mucosa is hyperechoic and irregular. No masses or cystoliths are observed. The trigone and visible pelvic urethra are normal thickness with a smooth mucosal surface.  The area of the prostate is examined without evident pathology.
<b>BREED</b>	
Border Terrier	
<b>SEX</b>	
Neutered Male	Kidneys are overall normal in size and shape with smooth peripheral margination. A normal 1:3 cortex to medulla ratio is maintained. The medulla and cortices are uniform in texture with some mild increased cortical echogenicity and mild loss of corticomedullary distinction, expected in this age patient. There is no evidence of pyelectasia, mineral or infarcts observed. The right kidney measures 4.5 cm. The left kidney measures 4.41 cm.
<b>AGE</b>	<b>Adrenal Glands</b>
14 Years	The right adrenal gland measures 1.9 cm at the cranial pole and 0.75 cm at the caudal pole. A hyperechoic nodule is noted involving the cranial pole of the adrenal gland that measures 1.9 cm x 2.5 cm. The nodule has a heterogeneous appearance and results in swollen capsular expansion, but no evidence of capsular escape or disruption to architecture, vascular invasion, etc.
<b>WEIGHT</b>	
10.3 kg	
<b>INTERPRETED BY</b>	The left adrenal gland is normal in size (1.68 cm long x 0.50 cm at the cranial pole and 0.66 cm at the caudal pole), shape and contour. Corticomedullary structure is unremarkable. Visible surrounding vasculature appears normal.
Beth Johnson, DVM DACVIM	<b>Spleen</b>
<b>IMAGING PERFORMED BY</b>	The spleen is subjectively normal in size with a normal smooth capsular contour. Parenchyma is appropriately finely textured and homogenous with normal echogenicity relative to surrounding tissue (hyperechoic to liver). No focal nodules or masses are observed. Splenic vasculature appears normal.
Kelly Reschny	<b>Liver</b>
<b>HOSPITAL NAME</b>	Liver is subjectively enlarged with mildly irregular margins. Parenchyma is heterogenous characterized by multiple poorly defined hypoechoic nodules within otherwise hyperechoic liver parenchyma. Visible vasculature and biliary tree appear normal without distension or congestion.
Westoak AH	
<b>REFERRING VET</b>	The gallbladder is non-distended in size. The wall is smooth without visible thickening. Luminal contents are primarily anechoic. There is no evidence of cystic or common bile duct dilation.
Dr. Kohlmaier	<b>Gastrointestinal</b>
<b>INVOICE</b>	The visible stomach wall is normal in thickness and layering. The lumen of the stomach is mildly distended with echogenic non-shadowing luminal contents and gas consistent with normal ingesta. There is no evidence of obstruction, foreign material or infiltrative disease. Pyloric outflow tract appears patent.
43231	
<b>DATE</b>	The visible small intestines are normal in wall thickness and layering. Small intestinal motility appears adequate (1-3 contractions per min). The lumen of the small intestine is mildly distended with echogenic
12/6/22	



**PATIENT**

Kelso Notley

non-shadowing luminal contents and gas consistent with normal ingesta. There is no evidence of obstruction, foreign material or infiltrative disease.

The visible colon is normal in wall thickness (< 0.2 cm) and layering. Contents are consistent with normal formed feces and gas.

**SPECIES**

Canine

**Pancreas**

The pancreatic parenchyma is appropriately isoechoic to surrounding tissue. Visible capsule is smooth and normal in contour. There is no visible pancreatic duct dilation. There is no evidence of active peripancreatic inflammation.

**BREED**

Border Terrier

**Free Abdomen**

There is no evidence of free peritoneal effusion noted in these images.

**SEX**

Neutered Male

There is no apparent lymphadenopathy noted in these images.

**PRIMARY FINDINGS**

**AGE**

14 Years

- **Hyperechoic adrenal nodule/mass in the cranial pole of the right adrenal gland** – Differentials include primary adrenal cortical adenoma or less likely adenocarcinoma or pheochromocytoma. Adrenal hyperplasia secondary to pituitary disease is equally possible. Some hyperechoic nodules without other evidence of abdominal disease or evidence of adrenal disease are incidental and require nothing further than monitoring.

**WEIGHT**

10.3 kg

- **Heterogenous Liver** – These changes are most consistent with benign processes such as nodular hyperplasia, steroid (vacuolar) hepatopathy, extramedullary hematopoiesis or possibly chronic inflammatory disease and less commonly infiltrative round cell or metastatic neoplasia.

**INTERPRETED BY**

Beth Johnson, DVM  
DACVIM

**SECONDARY FINDINGS**

- **Chronic Cystitis** - Urinary bladder wall changes are most consistent with chronic cystitis. Infiltrative neoplasia cannot be ruled out but is considered less likely give the location and diffuse nature of the changes.
- Age related kidney changes

**IMAGING PERFORMED BY**

Kelly Reschny

**INTERPRETATION OF THE FINDINGS & FURTHER RECOMMENDATIONS**

**HOSPITAL NAME**

Westoak AH

The changes described above could suggest hyperadrenocorticism as a cause for this patient's reported PU/PD. Both adrenal dependent and pituitary dependent are possible with slightly increased suspicion for adrenal dependent disease is hyperadrenocorticism is diagnosed.

Recommendations include a low-dose Dexamethasone suppression test, both to try to diagnose hyperadrenocorticism, as well as further help to differentiate.

**REFERRING VET**

Dr. Kohlmaier

Additionally, a urine culture is recommended if not recently evaluated as is a blood pressure.

**INVOICE**

43231

**DATE**

12/6/22



**PATIENT**

Kelso Notley

**SPECIES**

Canine

**BREED**

Border Terrier

**SEX**

Neutered Male

**AGE**

14 Years

**WEIGHT**

10.3 kg

**INTERPRETED BY**

Beth Johnson, DVM  
 DACVIM

**IMAGING PERFORMED BY**

Kelly Reschny

**HOSPITAL NAME**

Westoak AH

**REFERRING VET**

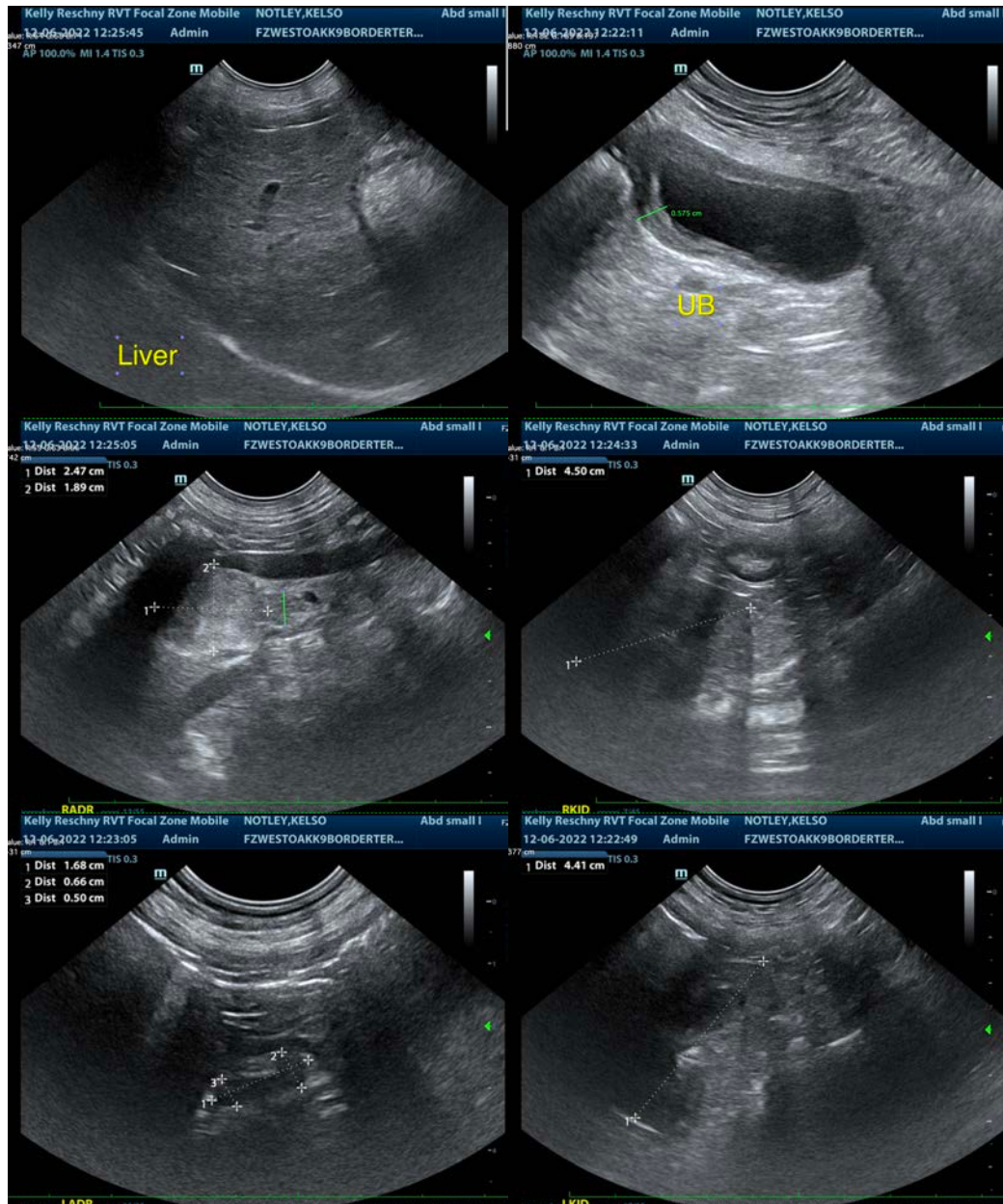
Dr. Kohlmaier

**INVOICE**

43231

**DATE**

12/6/22



The information and recommendations provided are based on the images presented by the referring veterinarian/sonographer. No evaluation can be communicated regarding pathology that was not visible in the image/video clips provided.

Thank you for this referral. If the clinical or image interpretation does not parallel your findings or if I can be of any further assistance please contact me.

**Beth Johnson, DVM, DACVIM**  
 Beth.Johnson@sonopath.com