



DATE	PRESENTING CLINICAL SIGNS
12/4/2025	Patient History: Severe lethargy, not drinking much, diarrhea yesterday. Recent weight loss from 80 pounds in Jan 2025 to 73 in OCT 2025 and today 64 pounds. Exam: abdominal discomfort, lethargic, tacky MM.
PATIENT Winnie Sheldon	Chronic Issues: Proteinuric kidney disease / chronic kidney disease with overt albuminuria and protein-losing nephropathy (PLN) with episodes of azotemia (examples: creatinine 3.9 mg/dL on 08/18/2025; prior year 2.1 mg/dL). Hypertension documented (BP 154/121 on 08/20/2025). Persistent proteinuria/microalbuminuria (microalbumin >30 mg/dL on multiple dates). Recurrent bacteriuria/UTI(culture-proven Proteus mirabilis 09/2025). Urinary incontinence intermittently present and responsive to estriol (Incurin). Chronic allergic/atopic dermatitis with recurrent pruritus/foot licking responsive to Cytopoint. Recurrent otitis externa (yeast) and suspected food allergy. Orthopedic/spinal pain and intermittent lameness (left forelimb/spinal tenderness noted 02/07/2024). Historical sebaceous cysts /small dermal masses monitored. Patient kidneys palpate painful and enlarged.
SPECIES Canine	
BREED Border Collie Mix	Current Medications: Telmisartan 40 mg daily, Incurin EOD, Vet has prescribed Clopidogrel but owner never filled it.
SEX Spayed Female	Labwork Results: Labwork not attached, reported as: Today: Crea 4.0, BUN 108, Phos 8.8, Ca 12, K 5.3 CBC: WBC 3.58 (L), Neu 2.23 (L), RBC 3.98 (L), HGB 10.1 (L), HCT 29.5 (L). UA: SG 1.014, cocci present, no other significant.
AGE 14 years	Date of Previous IntraPet Ultrasound: No previous.
WEIGHT 29.2 kg	Sedation: Not required to complete full diagnostic ultrasound.
INTERPRETED BY Beth Johnson, DVM DACVIM	Stat Report: Approved. Imaging Performed by: Stephanie Warga RDCS, RVT.
HOSPITAL NAME Mason Dixon Animal Emergency Hospital	ULTRASONOGRAPHIC EXAMINATION OF THE ABDOMEN Urinary System The urinary bladder is adequately distended with anechoic contents. No masses, inflammatory changes, echogenic sediment or cystoliths are observed. The urinary bladder, trigone and visible pelvic urethra are normal in thickness with a smooth mucosal surface.
REFERRING VET Dr. Yolles	Kidneys are bilaterally normal in size (left kidney measures 6.07 cm) (right kidney measures 6.46 cm) irregular and diffusely echogenic with decreased corticomedullary distinction and poor visualization of internal architecture. There is mild to moderate pyelectasia noted bilaterally. There is no mineral is observed.
INVOICE 10850	Adrenal Glands Adrenal glands are small (flattened contour). Corticomedullary structure is unremarkable. Visible surrounding vasculature appears normal. Left adrenal measures 0.53 cm at the cranial pole and 0.61 cm at the caudal pole. Right adrenal measures 0.72 cm at the cranial pole and 0.52 cm at the caudal pole. Spleen

Spleen is subjectively normal in size with a normal smooth capsular contour. Parenchyma is appropriately finely textured and homogenous with normal echogenicity relative to surrounding tissue (hyperechoic to liver). Multifocal well-demarcated hyperechoic homogenous nodules are noted. Splenic vasculature appears normal.

Liver

Liver is subjectively enlarged with mildly irregular margins. Parenchyma is mildly heterogenous characterized by multiple poorly defined hypoechoic nodules within otherwise hyperechoic liver parenchyma. One representative nodule measures approximately 1.8 cm in diameter. Visible vasculature and biliary tree appear normal without distension or congestion.

Gallbladder is moderately distended with anechoic bile as well as suspended and gravity dependent echogenic debris. The wall is smooth without visible thickening. There is no evidence of cystic or CBD dilation. There is no evidence of effusion or inflammation.

Gastrointestinal

The visible stomach wall is normal in thickness and layering. The lumen of the stomach is empty with no evidence of obstruction, foreign material or infiltrative disease. Pyloric outflow tract appears patent.

The visible small intestines are normal in wall thickness and layering. Small intestinal motility appears adequate (1-3 contractions per min). The lumen of the small intestine is mildly distended with echogenic non-shadowing luminal contents and gas consistent with normal ingesta. There is no evidence of obstruction or foreign material noted.

The visible colon is normal in wall thickness (< 0.2 cm) and layering. Contents are consistent with normal formed feces and gas.

Pancreas

The pancreas that is observed appears appropriately isoechoic to surrounding omental fat. Visible capsule is smooth and normal in contour. Visible pancreatic parenchyma is homogenous and unremarkable. There is no visible pancreatic duct dilation. There is no evidence of active peripancreatic inflammation.

Free Abdomen

There is no visible free peritoneal effusion noted in these images.

Several cystic elongated densities are noted adjacent to the right kidney, towards the mid abdomen, that are consistent in appearance with cystic lymph nodes, potentially renal nodes versus mesenteric versus other.

PRIMARY FINDINGS

- Chronic kidney disease changes with bilateral mild to moderate pyelectasia.
- Suspect cystic, likely reactive renal lymph nodes. This can sometimes be seen with chronic infections. Other benign inflammatory disease and less likely infiltrative neoplasia, however, can't be ruled out.

- Flat adrenal glands – This can be a normal patient variant and/or a sign of exogenous cortisol administration. If exogenous steroids are not being administered, hypoadrenocorticism (either relative or absolute) should be considered.

SECONDARY FINDINGS

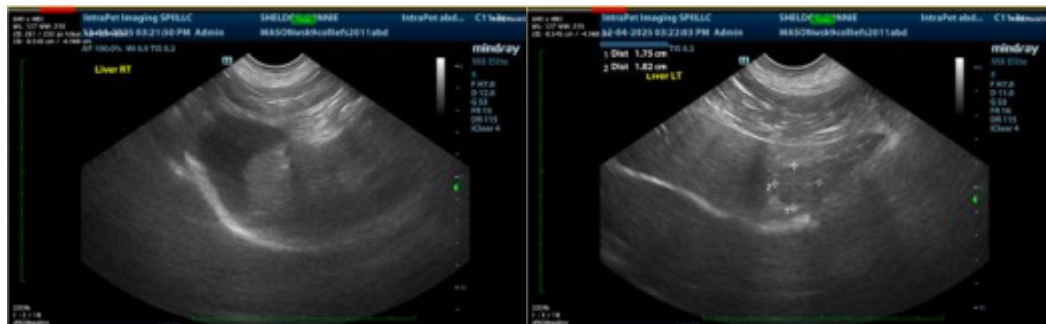
- Heterogenous Liver – These changes are most consistent with benign processes such as nodular hyperplasia, steroid (vacuolar) hepatopathy, extramedullary hematopoiesis or possibly chronic inflammatory disease and less commonly infiltrative round cell or metastatic neoplasia.
- Moderate gallbladder debris - Cholecystic debris is of unknown clinical significance. It can be seen with biliary stasis from fasting or illness. Cholecystic debris is not necessarily related to hepatobiliary disease. Echogenic bile is most commonly an incidental finding in dogs and should be interpreted in combination with clinical signs such as nausea, inappetence, cranial abdominal discomfort and/or laboratory changes such as increased ALP and/or increased Tbili.
- Hyperechoic splenic nodule(s) – most consistent with benign myelolipomas. Other differentials such as fibrosis or calcification caused by old hematomas or infarcts, chronic inflammation, granulomatous disease or metastatic disease cannot be ruled out, but are considered less likely.

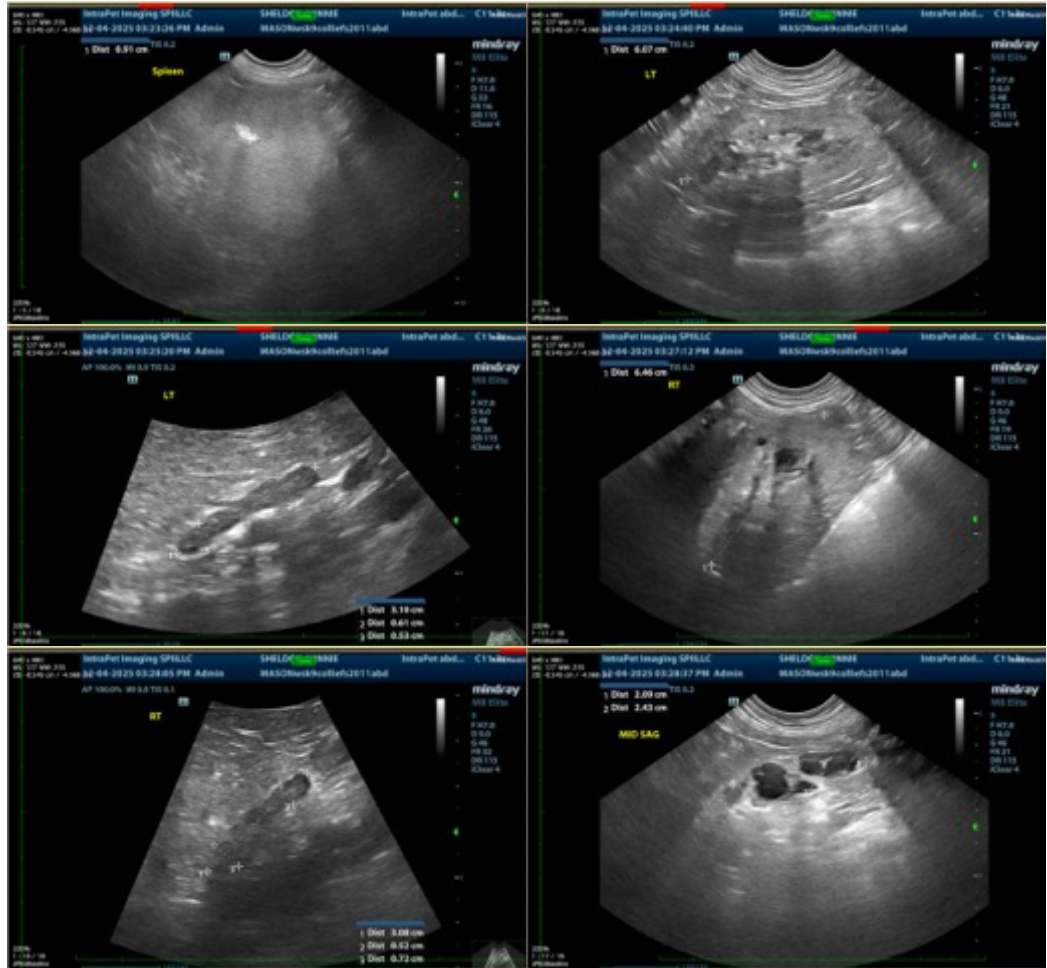
INTERPRETATION OF THE FINDINGS & FURTHER RECOMMENDATIONS

If not already pending, a urine culture is recommended.

A baseline cortisol is recommended. If baseline cortisol is less than 2, a full ACTH stimulation test is recommended to rule out hypoadrenocorticism.

Otherwise, the findings seen above are consistent with patient's reportedly known historical diagnoses which treatment is reportedly in place for. Therefore, if patient is not improving and/or continues to decline, consultation with or potentially referral to a veterinary internist if available could be considered.





The information and recommendations provided are based on the images presented by the referring veterinarian/sonographer. No evaluation can be communicated regarding pathology that was not visible in the image/video clips provided.

Thank you for this referral. If the clinical or image interpretation does not parallel your findings or if I can be of any further assistance please contact me.

Beth Johnson, DVM, DACVIM
info@sonopath.com