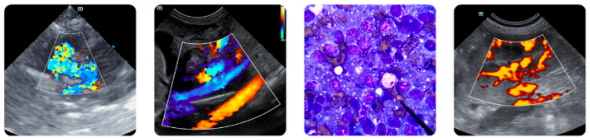

PATIENT
Riley Sackett

SPECIES
Canine

BREED
Boxer

SEX
Spayed Female

AGE
9 years 6 months

WEIGHT
72 lbs

INTERPRETED BY
Beth Johnson, DVM DACVIM

IMAGING PERFORMED BY
Dr. Cassie Quillen

HOSPITAL NAME
Zumbrota Veterinary Clinic

REFERRING VET
Dr. Cassie Quillen

INVOICE
10857

DATE
12/4/2025

PRESENTING CLINICAL SIGNS

Presented to rDVM on 12/1 for lethargy, pale gums, anorexia, breathing heavier. Blood work and x-rays were done. rDVM concerned with craniodorsal abdomen on x-rays and recommended ultrasound.

Abnormal PE/Chem/CBC/UA Results: 12/1/25 PE: mm slightly pale, mildly lethargic, mild abdominal breathing, mildly tense on abdominal palpation, mild edema on right inner thigh, vitals and rest of exam unremarkable. CBC: RBC low 4.77 x 10^12/l (5.5-8.5) HGB low 10.7 g/dL (12-18) HCT low 32.19% (37-55) lymph low 0.89 x 10^9/l (1.0-4.8) rest wnl Chem: BUN high 37 g/dL (7-25) glucose high 127 mg/dL (60-110) rest wnl Radiographs: Moderate spondylosis throughout the spine. Ventral/lateral deviation of intestinal loops.

ULTRASONOGRAPHIC EXAMINATION OF THE ABDOMEN

Urinary System

The urinary bladder is adequately distended with anechoic contents. No masses, inflammatory changes, echogenic sediment or cystoliths are observed. The urinary bladder, trigone and visible pelvic urethra are normal in thickness with a smooth mucosal surface.

The right kidney is normal is size (8.04 cm), shape and echogenicity. It has smooth peripheral margination. There is a normal 1:3 cortex to medulla ratio with appropriate corticomedullary distinction. There is no evidence of pyelectasia, mineral or infarcts observed.

The left kidney is normal is size (7.37 cm), shape and echogenicity. It has smooth peripheral margination. There is a normal 1:3 cortex to medulla ratio with appropriate corticomedullary distinction. There is no evidence of pyelectasia, mineral or infarcts observed.

Adrenal Glands

In the area of the right adrenal gland is a mass. *See Other*

The left adrenal gland is difficult to fully visualize in these images, but one pole is well visualized and measured at 0.55 cm in size with a largely normal to subjectively, mildly flat appearance.

Spleen

The spleen is subjectively normal in size with a normal smooth capsular contour. Parenchyma is appropriately finely textured and homogenous with normal echogenicity relative to surrounding tissue (hyperechoic to liver). No focal nodules or masses are observed. Splenic vasculature appears normal.

Liver

The liver is subjectively normal in size with normal smooth curvilinear peripheral contour. Parenchyma is appropriately hypoechoic to the spleen in echogenicity and appropriately mildly coarse and homogenous in echotexture. No focal lesions are observed. Visible vasculature and biliary tree appear normal without distension or congestion.

The gallbladder is non-distended in size. The wall is smooth without visible thickening. Luminal contents are primarily anechoic. There is no evidence of cystic or common bile duct dilation.

Gastrointestinal

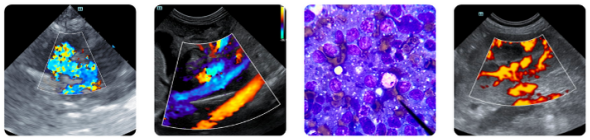

PATIENT
Riley Sackett

SPECIES
Canine

BREED
Boxer

SEX
Spayed Female

AGE
9 years 6 months

WEIGHT
72 lbs

INTERPRETED BY
Beth Johnson, DVM DACVIM

IMAGING PERFORMED BY
Dr. Cassie Quillen

HOSPITAL NAME
Zumbrota Veterinary Clinic

REFERRING VET
Dr. Cassie Quillen

INVOICE
10857

DATE
12/4/2025

The visible stomach wall is normal in thickness and layering. The lumen of the stomach is empty with no evidence of obstruction, foreign material or infiltrative disease. Pyloric outflow tract appears patent.

The visible small intestines are normal in wall thickness and layering. Small intestinal motility appears adequate (1-3 contractions per min). The lumen of the small intestine is empty with no evidence of obstruction, foreign material or infiltrative disease.

The visible colon is normal in wall thickness (< 0.2 cm) and layering. Contents are consistent with normal formed feces and gas.

Pancreas

The pancreas that is observed appears appropriately isoechoic to surrounding omental fat. Visible capsule is smooth and normal in contour. Visible pancreatic parenchyma is homogenous and unremarkable. There is no visible pancreatic duct dilation. There is no evidence of active peripancreatic inflammation.

Free Abdomen

There is no visible free peritoneal effusion noted in these images.

There is no apparent pathologic lymphadenopathy noted in these images.

In the right cranial abdomen, there is an approximately 6.2 cm x 5.4 cm mixed heterogenous, largely hypoechoic, partially cystic/cavitated mass.

ULTRASONOGRAPHIC FINDINGS

- A right cranial abdominal mass. Appears to potentially represent a right adrenal mass. Having said that, it's difficult to definitively identify the origin of the mass and other differentials include lymph node, pancreas, or even liver.

INTERPRETATION OF THE FINDINGS & FURTHER RECOMMENDATIONS

Given patient's reported lab work results, if not recently evaluated, urinalysis and, if indicated based on urinalysis results, urine culture is recommended. If protein is present in an otherwise quiet sediment, protein quantification with a urine protein to creatinine ration is recommended.

A blood pressure is recommended if not recently evaluated.

Three view thoracic radiographs are recommended for further assessment of cardio-pulmonary status as well as to further evaluate for any evidence of metastatic disease, if not recently evaluated.

Hormone testing could be considered beginning with a low dose dexamethasone suppression test.

Ultimately, however, tissue sampling such as a fine needle aspirate or ultimately excisional biopsy of the mass, will likely be warranted. A fine needle aspirate could be considered if patient's coagulation status is appropriate or given the concern that it might represent an adrenal mass, advanced imaging could be considered, such as an abdominal contrast CT scan for further staging with planned surgery to follow for probable right adrenalectomy pending the above workup.

SonoPath
FOSTERING THE ART OF VETERINARY MEDICINE™

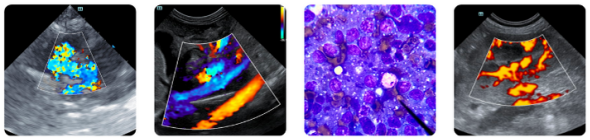

Clinical Sonography & Telecytology
Educational Teleconsultation Services™

SonoPath.com *info@sonopath.com* *1.800.838.4268*

PATIENT

Riley Sackett

SPECIES

Canine

BREED

Boxer

SEX

Spayed Female

AGE

9 years 6 months

WEIGHT

72 lbs

INTERPRETED BY

Beth Johnson, DVM DACVIM

IMAGING PERFORMED BY

Dr. Cassie Quillen

HOSPITAL NAME

Zumbrota Veterinary Clinic

REFERRING VET

Dr. Cassie Quillen

INVOICE

10857

DATE

12/4/2025

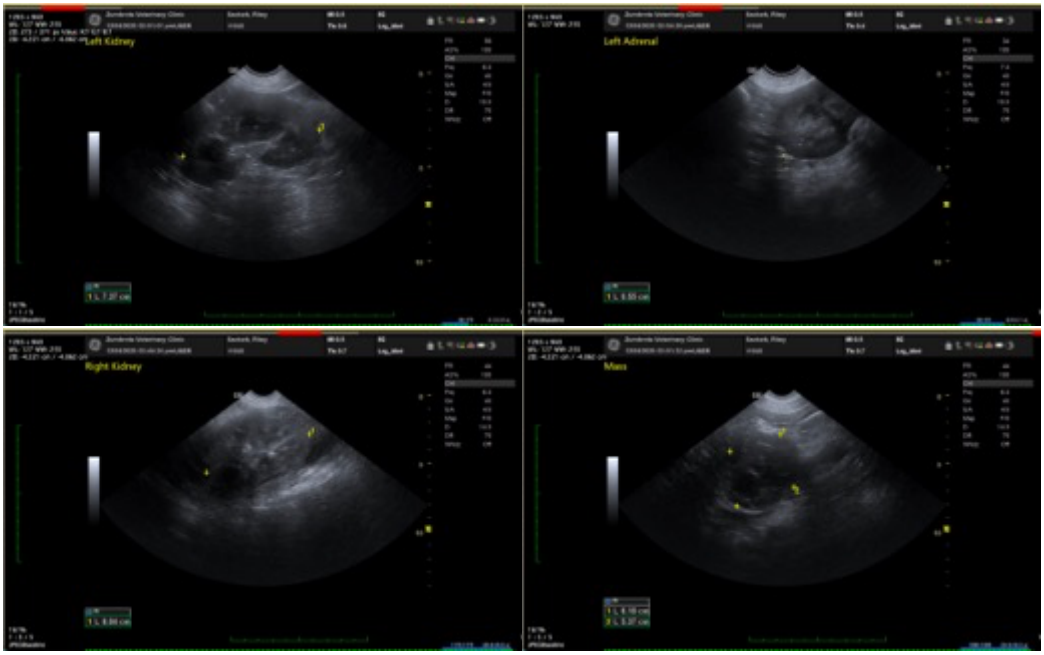

The information and recommendations provided are based on the images presented by the referring veterinarian/sonographer. No evaluation can be communicated regarding pathology that was not visible in the image/video clips provided.

Thank you for this referral. If the clinical or image interpretation does not parallel your findings or if I can be of any further assistance please contact me.

Beth Johnson, DVM, DACVIM
info@sonopath.com