



## PATIENT

Reese Nielsen

## SPECIES

Canine

## BREED

Golden

## SEX

Spayed Female

## AGE

12

## WEIGHT

73.8

## INTERPRETED BY

Beth Johnson, DVM  
DACVIM

## IMAGING PERFORMED BY

Dr. Betsy LaCroix

## HOSPITAL NAME

Inspire Animal  
Hospital- Highlands  
Ranch

## REFERRING VET

Dr. Betsy LaCroix

## INVOICE

12544

## DATE

12/03/25

## PRESENTING CLINICAL SIGNS

Patient presented for swelling on LH leg (pitting edema), does not appear painful, no wounds. Rectal exam-wnl BW performed in Sept was unremarkable except for UTI. Dog has been acting completely normal and rads of affected leg and pelvis show age related changes, but otherwise appear unremarkable

Abnormal PE/Chem/CBC/UA Results: Significant pitting edema on LH leg that extends all the way into inguinal region. Rectal exam had full anal glands, but no masses noted, new BW is pending. Leg shows no lesions and is the same temp as the other leg.

## ULTRASONOGRAPHIC EXAMINATION OF THE ABDOMEN

### Urinary System

Urinary bladder is only mildly distended. Visible contents are anechoic. Urinary bladder wall is unable to be fully assessed for pathology without further distension. No visible masses or definitive cystoliths are observed. The trigone and visible pelvic urethra are normal thickness with a smooth mucosal surface. In the face of urinary signs and/or suspected urinary bladder pathology, reassessment after complete filling is recommended.

Left kidney is normal in size (5.3 cm), shape and echogenicity. It has smooth peripheral margination. There is a normal 1:3 cortex to medulla ratio with appropriate corticomedullary distinction. There is no evidence of pyelectasia, mineral or infarcts observed.

Right kidney is normal in size (6.4 cm), shape and echogenicity. It has smooth peripheral margination. There is a normal 1:3 cortex to medulla ratio with appropriate corticomedullary distinction. There is no evidence of pyelectasia, mineral or infarcts observed.

### Adrenal Glands

Left adrenal gland is normal in size (1.0 cm at cranial pole and 0.80 cm at caudal pole), shape and overall architecture, echogenicity and echotexture. Visible surrounding vasculature appears normal.

Right adrenal gland is normal in size (0.80 cm at caudal pole), shape and overall architecture, echogenicity and echotexture. Visible surrounding vasculature appears normal. The cranial pole was unable to be well visualized in these images.

### Spleen

Spleen is subjectively large in size with normal smooth margins. Parenchyma is normal in echogenicity with a diffusely coarse/heterogenous echotexture. No masses are observed. Splenic vasculature appears normal. The spleen measures 2.5 cm thick at the hilus. In addition, there is an approximately 1.0 cm x 1.4 cm mildly heterogenous hypo- to anechoic noncapsule disrupting nodule/mass in the mid spleen.

### Liver

Liver is subjectively enlarged with mildly irregular margins. Parenchyma is mildly heterogenous characterized by multiple poorly defined hypoechoic nodules within otherwise hyperechoic liver parenchyma. Visible vasculature and biliary tree appear normal without distension or congestion.



## PATIENT

Reese Nielsen

Gallbladder is moderately distended with anechoic bile as well as suspended and gravity dependent echogenic debris. The wall is smooth without visible thickening. There is no evidence of cystic or CBD dilation. There is no evidence of effusion or inflammation.

## SPECIES

Canine

### *Gastrointestinal*

The visible stomach wall is normal in thickness and layering. The stomach is moderately distended with echogenic non-shadowing luminal contents and gas consistent with normal ingesta. There is no evidence of obstruction, foreign material or infiltrative disease. If patient was appropriately fasted, delayed gastric emptying could be considered. Non-shadowing foreign material is considered less likely but cannot be definitively ruled out. If clinical signs are consistent (vomiting, etc.), recommendations include supportive medical care, 24 hours fasting and re-image.

## BREED

Golden

## SEX

Spayed Female

The visible small intestines are normal in wall thickness and layering. Small intestinal motility appears adequate (1-3 contractions per min). The lumen of the small intestine is mildly distended with echogenic non-shadowing luminal contents and gas consistent with normal ingesta/chyme. There is no evidence of obstruction, foreign material or infiltrative disease.

## AGE

12

The visible colon is normal in wall thickness (< 0.2 cm) and layering. Contents are consistent with normal formed feces and gas.

## WEIGHT

73.8

### *Pancreas*

There is some mildly prominent coarse hypoechoic pancreatic parenchyma appreciated in the right cranial abdomen, however, the parenchymal changes are difficult to fully assess in the face of a large amount of enhanced hyperechoic mesentery and fat throughout the cranial and mid abdomen.

## INTERPRETED BY

Beth Johnson, DVM  
DACVIM

### *Free Abdomen*

There is no visible free peritoneal effusion noted in these images.

## IMAGING PERFORMED BY

Dr. Betsy LaCroix

There is no apparent pathologic lymphadenopathy noted in these images.

As described above, there is nonspecific ill-defined enhanced hyperechoic fat throughout the cranial and mid abdomen including adjacent to both kidneys that could be secondary to pancreatitis or steatitis from other cause. Additionally, subq edema is noted in some images.

## HOSPITAL NAME

Inspire Animal  
Hospital- Highlands  
Ranch

### ULTRASONOGRAPHIC FINDINGS

## REFERRING VET

Dr. Betsy LaCroix

- Suspect mild to moderate acute pancreatitis versus steatitis from a second inflammatory nidus.
- Coarse splenomegaly – can be associated with congestion caused by sedation (if sedated) but can also be associated with diffuse infiltrative disease. Both benign conditions such as extramedullary hematopoiesis, lymphoid hyperplasia, as well as infiltrative neoplastic diseases such as round cell neoplasia should be considered.
- Hypo to anechoic splenic nodule – likely represents a benign lesion such as a cyst, hematoma, nodular hyperplasia, extramedullary hematopoiesis, etc., however while considered less likely, infiltrative neoplasia can mimic benign lesions and cannot be ruled out.
- Mildly heterogenous Liver – These changes are most consistent with benign processes such as nodular hyperplasia, steroid (vacuolar) hepatopathy, extramedullary hematopoiesis or

## INVOICE

12544

## DATE

12/03/25



**PATIENT**

Reese Nielsen

**SPECIES**

Canine

**BREED**

Golden

**SEX**

Spayed Female

**AGE**

12

**WEIGHT**

73.8

**INTERPRETED BY**

Beth Johnson, DVM  
DACVIM

**IMAGING PERFORMED BY**

Dr. Betsy LaCroix

**HOSPITAL NAME**

Inspire Animal  
Hospital- Highlands  
Ranch

**REFERRING VET**

Dr. Betsy LaCroix

**INVOICE**

12544

**DATE**

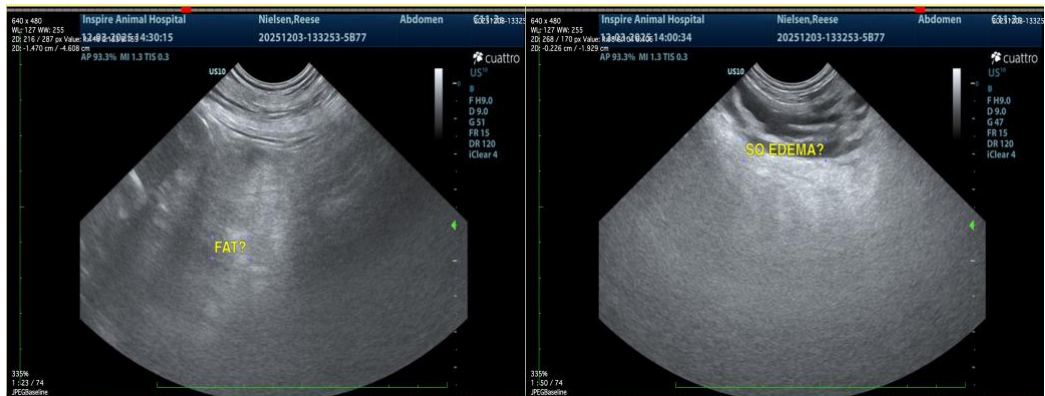12/03/25

possibly chronic inflammatory disease and less commonly infiltrative round cell or metastatic neoplasia.

- Moderate gallbladder debris- Cholecystic debris is of unknown clinical significance. It can be seen with biliary stasis from fasting or illness. Cholecystic debris is not necessarily related to hepatobiliary disease. Echogenic bile is most commonly an incidental finding in dogs and should be interpreted in combination with clinical signs such as nausea, inappetence, cranial abdominal discomfort and/or laboratory changes such as increased ALP and/or increased Tbili.

**INTERPRETATION OF THE FINDINGS & FURTHER RECOMMENDATIONS**

- If not recently evaluated, urinalysis and, if indicated based on urinalysis results, urine culture is recommended. If protein is present in an otherwise quiet sediment, protein quantification with a urine protein to creatinine ration is recommended.
- A quantitative PLI is recommended if not already evaluated.
- As is reportedly already pending, fine needle aspirates of the spleen can be considered if patient's coagulation status is appropriate.
- Comprehensive infectious disease including tickborne disease evaluation can be considered.
- Ultimately, tissue sampling or advanced imaging of the swollen limb may be necessary for a definitive diagnosis and to therefore further guide medical management.
- Other than supportive/symptomatic medical management of clinical signs, further treatment recommendations are largely dependent on results of the above.





**PATIENT**

Reese Nielsen

**SPECIES**

Canine

**BREED**

Golden

**SEX**

Spayed Female

**AGE**

12

**WEIGHT**

73.8

**INTERPRETED BY**

Beth Johnson, DVM  
DACVIM

**IMAGING PERFORMED BY**

Dr. Betsy LaCroix

**HOSPITAL NAME**

Inspire Animal Hospital- Highlands Ranch

**REFERRING VET**

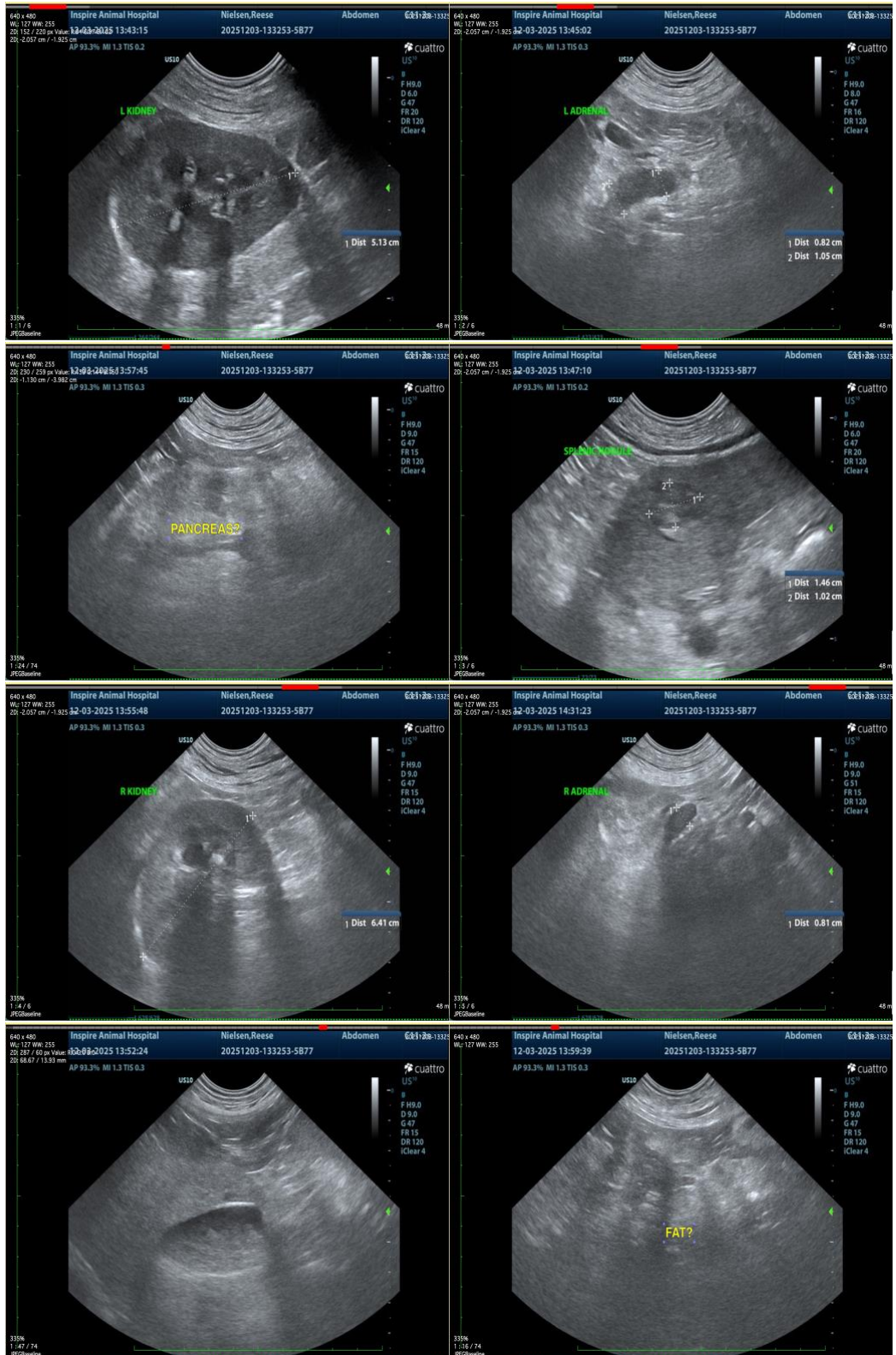
Dr. Betsy LaCroix

**INVOICE**

12544

**DATE**

12/03/25





## PATIENT

Reese Nielsen

## SPECIES

Canine

## BREED

Golden

## SEX

Spayed Female

## AGE

12

## WEIGHT

73.8

## INTERPRETED BY

Beth Johnson, DVM  
DACVIM

## IMAGING PERFORMED BY

Dr. Betsy LaCroix

## HOSPITAL NAME

Inspire Animal  
Hospital- Highlands  
Ranch

## REFERRING VET

Dr. Betsy LaCroix

## INVOICE

12544

## DATE

12/03/25

The information and recommendations provided are based on the images presented by the referring veterinarian/sonographer. No evaluation can be communicated regarding pathology that was not visible in the image/video clips provided.

Thank you for this referral. If the clinical or image interpretation does not parallel your findings or if I can be of any further assistance, please contact me.

**Beth Johnson, DVM DACVIM**

info@sonopath.com