



PATIENT

Max Hengeveld

SPECIES

Feline

BREED

Domestic Shorthair

SEX

Neutered Male

AGE

10 Years 8 Months

WEIGHT

8.6

INTERPRETED BY

Beth Johnson, DVM
DACVIM

IMAGING PERFORMED BY

Jessica Green

HOSPITAL NAME

Stanglein Veterinary
Clinic

REFERRING VET

Dr. Erin Rothrock

INVOICE

72298

DATE

12/4/25

PRESENTING CLINICAL SIGNS

Patient was presented for routine annual exam with complaint of mild weight loss and intermittent vomiting (~1x a month). There was mild epaxial cachexia bilaterally. Patient has fairly significant dental tartar, but otherwise patients exam appeared fairly unremarkable.

Abnormal PE/Chem/CBC/UA Results: Elevation of all liver values (ALT 398, AST 116, ALKP 131); T4 was in the great zone, FreeT4 not consistent with hyperthyroidism; remainder of bloodwork is unremarkable

ULTRASONOGRAPHIC EXAMINATION OF THE ABDOMEN

Urinary System

Urinary bladder is adequately distended. It has a normal uniform wall thickness. Contents include primarily anechoic fluid with a large amount of echogenic non-shadowing debris, most consistent with exfoliated cells, crystals, mucous and/or small blood clots likely combined with incidental suspended lipid. Both sterile inflammation as well as urinary tract infection can present with echogenic debris. No masses or definitive cystoliths are observed. The trigone and visible pelvic urethra are normal in thickness with a smooth mucosal surface.

The right kidney is normal is size (4.1 cm), shape and echogenicity. It has smooth peripheral margination. There is a normal 1:3 cortex to medulla ratio with appropriate corticomedullary distinction. There is no evidence of pyelectasia, mineral or infarcts observed.

The left kidney is normal is size (3.6 cm), shape and echogenicity. It has smooth peripheral margination. There is a normal 1:3 cortex to medulla ratio with appropriate corticomedullary distinction. There is no evidence of pyelectasia, mineral or infarcts observed.

Adrenal Glands

The right adrenal gland is normal in size (0.31 cm), shape and overall architecture, echogenicity and echotexture. Visible surrounding vasculature appears normal.

The left adrenal gland is normal in size (0.36 cm), shape and overall architecture, echogenicity and echotexture. Visible surrounding vasculature appears normal.

Spleen

The spleen is subjectively normal in size with a normal smooth capsular contour. Parenchyma is appropriately finely textured and homogenous with normal echogenicity relative to surrounding tissue (hyperechoic to liver). No focal nodules or masses are observed. Splenic vasculature appears normal.

Liver

Liver is subjectively enlarged (swollen contour) without disruption of architecture. It has a normal homogenous echotexture. Parenchyma is diffusely hyperechoic characterized by less prominent than normal portal vein walls and increased echogenicity relative to the spleen and falciform fat. No focal lesions are observed. Visible vasculature and biliary tree appear normal without distension or congestion.

The gallbladder is non-distended in size. The wall is smooth without visible thickening. Luminal contents are primarily anechoic. There is no evidence of cystic or common bile duct dilation.



PATIENT

Max Hengeveld

SPECIES

Feline

BREED

Domestic Shorthair

SEX

Neutered Male

AGE

10 Years 8 Months

WEIGHT

8.6

INTERPRETED BY

Beth Johnson, DVM
DACVIM

IMAGING PERFORMED BY

Jessica Green

HOSPITAL NAME

Stanglein Veterinary
Clinic

REFERRING VET

Dr. Erin Rothrock

INVOICE

72298

DATE

12/4/25

Gastrointestinal

The visible stomach wall is normal in thickness and layering. The lumen of the stomach is empty with no evidence of obstruction, foreign material or infiltrative disease. Pyloric outflow tract appears patent.

The visible small intestine demonstrates areas of mildly thick muscularis layer relative to mucosa (disruption of the normal 1:3 muscularis:mucosa ratio). Small intestinal submucosa is slightly irregular, thick and hyperechoic, without evident loss of layering appreciated. The lumen of the small intestine is empty with no evidence of obstruction or foreign material.

The visible colon is normal in wall thickness (< 0.2 cm) and layering. Contents are consistent with normal formed feces and gas.

Pancreas

The pancreas that is observed appears appropriately isoechoic to surrounding omental fat. Visible capsule is smooth and normal in contour. Visible pancreatic parenchyma is homogenous and unremarkable. There is no visible pancreatic duct dilation. There is no evidence of active peripancreatic inflammation.

Free Abdomen

There is no visible free peritoneal effusion noted in these images.

Mesenteric lymph nodes are prominent in size with swollen capsular contour. Normal elongated shape (length to width ratio) is maintained. There is no loss of parenchymal detail.

ULTRASONOGRAPHIC FINDINGS

- Hyperechoic hepatomegaly – This appearance is most consistent with benign hepatic lipidosis or endocrine/DM hepatopathy. Infiltrative disease such as amyloidosis or round cell neoplasia, such as mast cell tumor or less likely, lymphoma, is also possible.
- Mild/emerging inflammatory bowel disease (IBD) pattern – Thick muscularis has been reported with infiltrative bowel disease including both benign inflammatory disease as well as infiltrative neoplasia such as lymphoma. No loss of layering, etc. is noted to make lymphoma more probable, but lymphoma cannot be definitively ruled out without tissue sampling.
- Moderate amount of echogenic urinary bladder debris.
- Mildly reactive mesenteric lymph nodes – infiltrative neoplastic disease cannot be ruled out but is considered less likely.

INTERPRETATION OF THE FINDINGS & FURTHER RECOMMENDATIONS

If not recently evaluated, a urinalysis and, if indicated based on urinalysis results, urine culture is recommended. If protein is present in an otherwise quiet sediment, protein quantification with a urine protein to creatinine ratio is recommended.

A gastrointestinal malabsorption panel (including cobalamin, folate, TLI and PLI) to Texas A&M GI Laboratory is recommended for further evaluation of GI and pancreatic function.



PATIENT

Max Hengeveld

SPECIES

Feline

BREED

Domestic Shorthair

SEX

Neutered Male

AGE

10 Years 8 Months

WEIGHT

8.6

INTERPRETED BY

Beth Johnson, DVM
DACVIM

IMAGING PERFORMED BY

Jessica Green

HOSPITAL NAME

Stanglein Veterinary
Clinic

REFERRING VET

Dr. Erin Rothrock

INVOICE

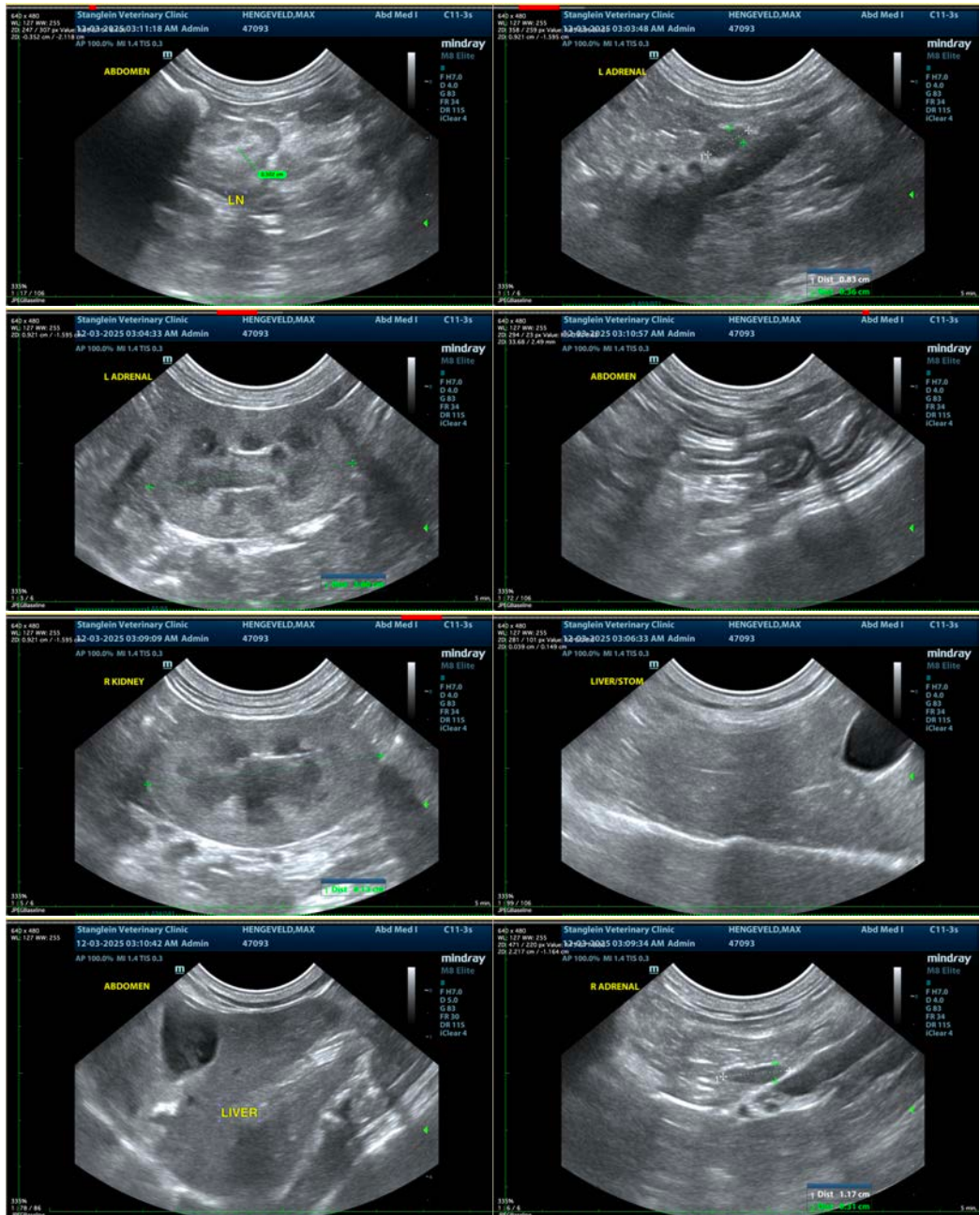
72298

DATE

12/4/25

Fine needle aspirates of the liver are recommended if patient's coagulation status is appropriate.

In the meantime, treatment recommendations include fluid therapy, anti-emetics, gastroprotectants, hepatic nutraceuticals such as ursodiol and/or Denamarin, and broad-spectrum antibiotics. Nutritional support is critical to prevent/manage concurrent hepatic lipidosis, so appetite stimulants and/or, if indicated, feeding tube placement is also recommended.





PATIENT

Max Hengeveld

SPECIES

Feline

BREED

Domestic Shorthair

SEX

Neutered Male

AGE

10 Years 8 Months

WEIGHT

8.6

INTERPRETED BY

Beth Johnson, DVM
DACVIM

IMAGING PERFORMED BY

Jessica Green

HOSPITAL NAME

Stanglein Veterinary
Clinic

REFERRING VET

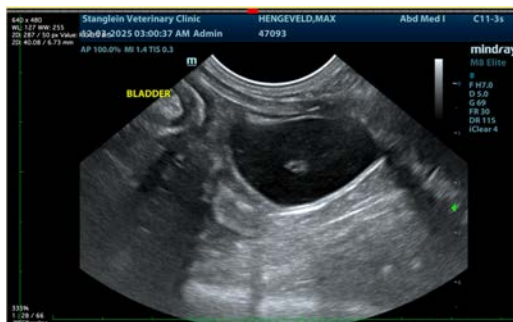Dr. Erin Rothrock

INVOICE

72298

DATE

12/4/25



The information and recommendations provided are based on the images presented by the referring veterinarian/sonographer. No evaluation can be communicated regarding pathology that was not visible in the image/video clips provided.

Thank you for this referral. If the clinical or image interpretation does not parallel your findings or if I can be of any further assistance please contact me.

Beth Johnson, DVM, DACVIM
info@sonopath.com