



PATIENT

Gretchen Anderson

SPECIES

Canine

BREED

German Hunting
Terrier

SEX

Spayed Female

AGE

9 Years 7 Months

WEIGHT

20

INTERPRETED BY

Beth Johnson, DVM
DACVIM

IMAGING PERFORMED BY

Carissa Hayden

HOSPITAL NAME

Elizabeth Animal
Hospital

REFERRING VET

Leon Anderson, DVM

INVOICE

72317

DATE

12/3/25

PRESENTING CLINICAL SIGNS

CPL was high.

Abnormal PE/Chem/CBC/UA Results: PE: Healthy CBC: RBC 9.04 M/ μ L, Hematocrit 61.6%, Hemoglobin 22.6 g/dL, WBC 4.6 K/uL, Lymphocytes 0.699 K/ μ L CHEM: Lipase 870U/L, Spec cPL 998 μ g/L

ULTRASONOGRAPHIC EXAMINATION OF THE ABDOMEN

Urinary System

The urinary bladder is adequately distended with anechoic contents. No masses, inflammatory changes, echogenic sediment or cystoliths are observed. The urinary bladder, trigone and visible pelvic urethra are normal in thickness with a smooth mucosal surface.

The right kidney is normal is size (3.99 cm), shape and echogenicity. It has smooth peripheral margination. There is a normal 1:3 cortex to medulla ratio with appropriate corticomedullary distinction. There is no evidence of pyelectasia, mineral or infarcts observed. A subtle hyperechoic band parallel to the corticomedullary border is present.

The left kidney is normal is size (4.75 cm), shape and echogenicity. It has smooth peripheral margination. There is a normal 1:3 cortex to medulla ratio with appropriate corticomedullary distinction. There is no evidence of pyelectasia, mineral or infarcts observed. A subtle hyperechoic band parallel to the corticomedullary border is present.

Adrenal Glands

The right adrenal gland is normal in size (0.59 cm at cranial pole and 0.46 cm at caudal pole), shape and overall architecture, echogenicity and echotexture. Visible surrounding vasculature appears normal.

The left adrenal gland is normal in size (0.58 cm at cranial pole and 0.55 cm at caudal pole), shape and overall architecture, echogenicity and echotexture. Visible surrounding vasculature appears normal.

Spleen

The spleen is subjectively normal in size with a normal smooth capsular contour. Parenchyma is appropriately finely textured and homogenous with normal echogenicity relative to surrounding tissue (hyperechoic to liver). No focal nodules or masses are observed. Splenic vasculature appears normal.

Liver

The liver is subjectively normal in size with normal smooth curvilinear peripheral contour. Parenchyma is appropriately hypoechoic to the spleen in echogenicity and appropriately mildly coarse and homogenous in echotexture. No focal lesions are observed. Visible vasculature and biliary tree appear normal without distension or congestion.

The gallbladder is non-distended in size. The wall is smooth without visible thickening. Luminal contents are primarily anechoic. There is no evidence of cystic or common bile duct dilation.

Gastrointestinal

The visible stomach wall is normal in thickness and layering. The lumen of the stomach is empty with no evidence of obstruction, foreign material or infiltrative disease. Pyloric outflow tract appears patent.



PATIENT

Gretchen Anderson

SPECIES

Canine

BREED

German Hunting
Terrier

SEX

Spayed Female

AGE

9 Years 7 Months

WEIGHT

20

INTERPRETED BY

Beth Johnson, DVM
DACVIM

IMAGING PERFORMED BY

Carissa Hayden

HOSPITAL NAME

Elizabeth Animal
Hospital

REFERRING VET

Leon Anderson, DVM

INVOICE

72317

DATE

12/3/25

The visible small intestines are normal in wall thickness and layering. Small intestinal motility appears adequate (1-3 contractions per min). The lumen of the small intestine is empty with no evidence of obstruction, foreign material or infiltrative disease.

The visible colon is normal in wall thickness (< 0.2 cm) and layering. Contents are consistent with normal formed feces and gas.

Pancreas

The pancreas that is observed appears appropriately isoechoic to surrounding omental fat. Visible capsule is smooth and normal in contour. Visible pancreatic parenchyma is homogenous and unremarkable. There is no visible pancreatic duct dilation. There is no evidence of active peripancreatic inflammation.

Free Abdomen

There is no visible free peritoneal effusion noted in these images.

There is no apparent pathologic lymphadenopathy noted in these images.

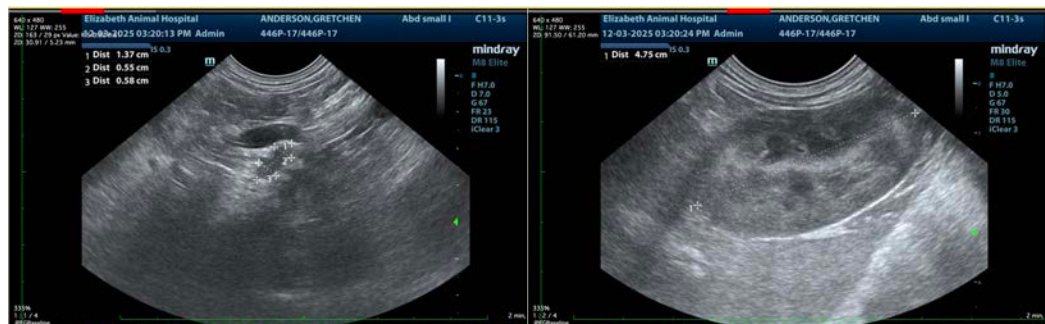
Assessment of heart base images is included when/if a splenic nodule/mass is present (as a complimentary add on). They are also assessed when a specific request is made for assessment of a limited second cavity (heart base and/or thorax) for an additional charge. Images of the heart (and/or thorax) were not assessed for this study. Please contact us if you would like a second cavity.

ULTRASONOGRAPHIC FINDINGS

- Subtle bilateral medullary rim sign - This finding is of unknown clinical significance and can be a normal variant, often idiopathic. Medullary rim sign can be present with renal disease including lymphoma, hypercalcemic nephropathy, Leptospirosis, tubular disease, other and should be interpreted in combination with other more specific indications of kidney disease such as isosthenuria, proteinuria, azotemia, etc. This is a common incidental finding in patients with diabetes mellitus.

INTERPRETATION OF THE FINDINGS & FURTHER RECOMMENDATIONS

The pancreas is visible and potentially subjectively mildly prominent, but no definitive ultrasonographically visible evidence or concern for pancreatitis in these images at this time. Having said that, chronic low-grade smoldering pancreatitis can't be ruled out. Further recommendations are largely dependent on patient's clinical history, etc.





PATIENT

Gretchen Anderson

SPECIES

Canine

BREED

German Hunting
Terrier

SEX

Spayed Female

AGE

9 Years 7 Months

WEIGHT

20

INTERPRETED BY

Beth Johnson, DVM
DACVIM

IMAGING PERFORMED BY

Carissa Hayden

HOSPITAL NAME

Elizabeth Animal
Hospital

REFERRING VET

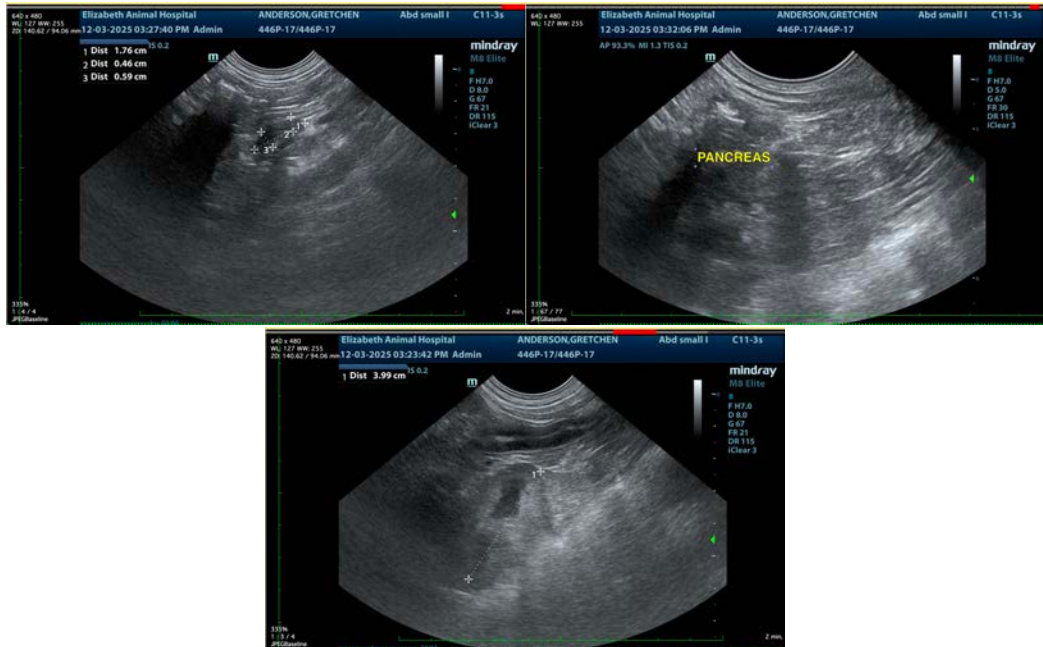
Leon Anderson, DVM

INVOICE

72317

DATE

12/3/25



The information and recommendations provided are based on the images presented by the referring veterinarian/sonographer. No evaluation can be communicated regarding pathology that was not visible in the image/video clips provided.

Thank you for this referral. If the clinical or image interpretation does not parallel your findings or if I can be of any further assistance please contact me.

Beth Johnson, DVM, DACVIM
info@sonopath.com