



## PATIENT

Dobby Wagner

## SPECIES

Canine

## BREED

Golden Retriever

## SEX

Neutered Male

## AGE

6

## WEIGHT

80

## INTERPRETED BY

Beth Johnson, DVM  
DACVIM

## IMAGING PERFORMED BY

Tasha

## HOSPITAL NAME

Dillsburg Veterinary  
Center

## REFERRING VET

Dr. Amber

## INVOICE

72279

## DATE

12/3/25

## PRESENTING CLINICAL SIGNS

Littermate recently passed away from lymphoma. O doing wellness everything as baseline  
Abnormal PE/Chem/CBC/UA Results: All WNL

## ULTRASONOGRAPHIC EXAMINATION OF THE ABDOMEN

### Urinary System

The urinary bladder is adequately distended with anechoic contents. No masses, inflammatory changes, echogenic sediment or cystoliths are observed. The urinary bladder, trigone and visible pelvic urethra are normal in thickness with a smooth mucosal surface.

Prostate is normal in size, echotexture and echogenicity for a neutered male.

The right kidney is normal is size (5.67 cm), shape and echogenicity. It has smooth peripheral margination. There is a normal 1:3 cortex to medulla ratio with appropriate corticomedullary distinction. There is no evidence of pyelectasia or infarcts observed. Subtle pinpoint non-obstructive nephroliths are noted.

The left kidney is normal is size (5.63 cm), shape and echogenicity. It has smooth peripheral margination. There is a normal 1:3 cortex to medulla ratio with appropriate corticomedullary distinction. There is no evidence of pyelectasia or infarcts observed. Subtle pinpoint non-obstructive nephroliths are noted.

### Adrenal Glands

The right adrenal gland is normal in size (0.39 cm at cranial pole and 0.41 cm at caudal pole), shape and overall architecture, echogenicity and echotexture. Visible surrounding vasculature appears normal.

The left adrenal gland is normal in size (0.69 cm at cranial pole and 0.89 cm at caudal pole), shape and overall architecture, echogenicity and echotexture. Visible surrounding vasculature appears normal.

### Spleen

The spleen is subjectively normal in size (2.0 cm thick at the hilus) with a normal smooth capsular contour. Parenchyma is appropriately finely textured and homogenous with normal echogenicity relative to surrounding tissue (hyperechoic to liver). No focal nodules or masses are observed. Splenic vasculature appears normal.

### Liver

The liver is subjectively normal in size with normal smooth curvilinear peripheral contour. Parenchyma is appropriately hypoechoic to the spleen in echogenicity and appropriately mildly coarse and homogenous in echotexture. No focal lesions are observed. Visible vasculature and biliary tree appear normal without distension or congestion.

The gallbladder is non-distended in size. The wall is smooth without visible thickening. Luminal contents are primarily anechoic. There is no evidence of cystic or common bile duct dilation.

### Gastrointestinal

The visible stomach wall is normal in thickness and layering. The lumen is mildly distended with primarily fluid as well as some echogenic non-shadowing luminal contents and gas consistent with



**PATIENT**

Dobby Wagner

**SPECIES**

Canine

**BREED**

Golden Retriever

**SEX**

Neutered Male

**AGE**

6

**WEIGHT**

80

**INTERPRETED BY**

Beth Johnson, DVM  
DACVIM

**IMAGING PERFORMED BY**

Tasha

**HOSPITAL NAME**

Dillsburg Veterinary Center

**REFERRING VET**

Dr. Amber

**INVOICE**

72279

**DATE**

12/3/25

normal chyme. There is no evidence of obstruction, foreign material, or infiltrative disease. Pyloric outflow tract appears patent.

The visible small intestines are normal in wall thickness and layering. Small intestinal motility appears adequate (1-3 contractions per min). The lumen of the small intestine is empty with no evidence of obstruction, foreign material or infiltrative disease.

The visible colon is normal in wall thickness (< 0.2 cm) and layering. Contents are consistent with normal formed feces and gas.

**Pancreas**

The pancreas that is observed appears appropriately isoechoic to surrounding omental fat. Visible capsule is smooth and normal in contour. Visible pancreatic parenchyma is homogenous and unremarkable. There is no visible pancreatic duct dilation. There is no evidence of active peripancreatic inflammation.

**Free Abdomen**

There is no visible free peritoneal effusion noted in these images.

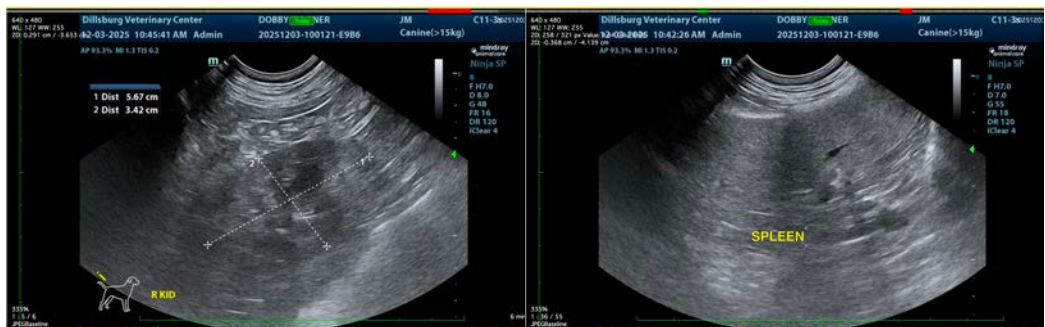
There is no apparent pathologic lymphadenopathy noted in these images.

**ULTRASONOGRAPHIC FINDINGS**

- Suspect pinpoint non-obstructive mineral densities in the kidneys bilaterally, most notable on the left.
- Otherwise, this is a largely unremarkable/normal structural abdomen with no definitive ultrasonographically visible evidence of intraabdominal neoplasia in these images at this time.

**INTERPRETATION OF THE FINDINGS & FURTHER RECOMMENDATIONS**

Routine wellness monitoring, as is reportedly in place, is recommended.





**PATIENT**

Dobby Wagner

**SPECIES**

Canine

**BREED**

Golden Retriever

**SEX**

Neutered Male

**AGE**

6

**WEIGHT**

80

**INTERPRETED BY**

Beth Johnson, DVM  
DACVIM

**IMAGING PERFORMED BY**

Tasha

**HOSPITAL NAME**

Dillsburg Veterinary  
Center

**REFERRING VET**

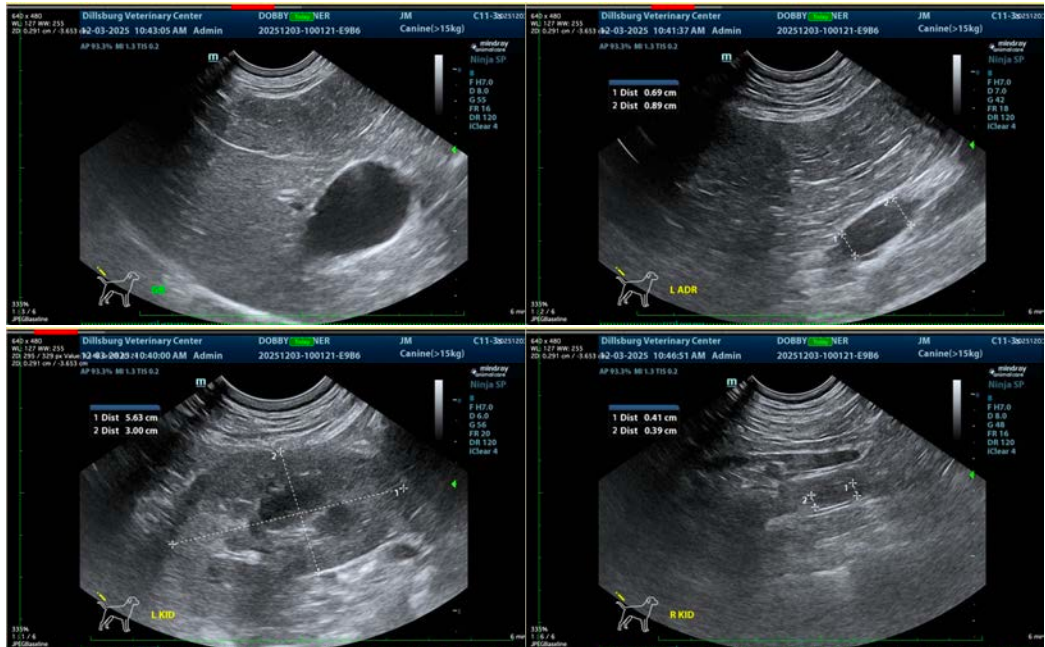
Dr. Amber

**INVOICE**

72279

**DATE**

12/3/25



The information and recommendations provided are based on the images presented by the referring veterinarian/sonographer. No evaluation can be communicated regarding pathology that was not visible in the image/video clips provided.

Thank you for this referral. If the clinical or image interpretation does not parallel your findings or if I can be of any further assistance please contact me.

**Beth Johnson, DVM, DACVIM**  
info@sonopath.com