



PATIENT	PRESENTING CLINICAL SIGNS
Max Anderson	Pet is having a history of hematuria/Incontinence and an increase in water consumption. Last ultrasound done 4/27/22. Pet is currently taking thyro tabs 0.1mg 1/2 tab SID
SPECIES	Abnormal PE/Chem/CBC/UA Results: WBC 2-3 RBC >50 and BLOOD 2+ with a urine specific gravity at 1.037
Feline	
BREED	ULTRASONOGRAPHIC EXAMINATION OF THE ABDOMEN
Siamese	Urinary System
SEX	The urinary bladder is adequately distended with both anechoic contents and a large amount of both suspended and dependent echogenic, some mineral/sand debris. No masses or other inflammatory changes observed. The urinary bladder, trigone and visible pelvic urethra are normal in thickness with a smooth mucosal surface.
Neutered Male	The right kidney is normal in size (4.03 cm), shape and echogenicity. It has smooth peripheral margination. There is a normal 1:3 cortex to medulla ratio with appropriate corticomedullary distinction. There is no evidence of pyelectasia, mineral or infarcts observed.
AGE	The left kidney is normal in size (4.15 cm), shape and echogenicity. It has smooth peripheral margination. There is a normal 1:3 cortex to medulla ratio with appropriate corticomedullary distinction. There is no evidence of pyelectasia, mineral or infarcts observed.
13 Years	
WEIGHT	Adrenal Glands
10.4 Pounds	The right adrenal gland is normal in size (0.36 cm at the cranial pole and 0.34 cm at the caudal pole), shape and contour. Corticomedullary structure is unremarkable. Visible surrounding vasculature appears normal.
INTERPRETED BY	The left adrenal gland is normal in size (0.30 cm at the cranial pole and 0.37 cm at the caudal pole), shape and contour. Corticomedullary structure is unremarkable. Visible surrounding vasculature appears normal.
Beth Johnson, DVM DACVIM	
IMAGING PERFORMED BY	Spleen
Marco Lichfield	Spleen is subjectively normal in size with a normal smooth capsular contour. Parenchyma is appropriately finely textured and homogenous with normal echogenicity relative to surrounding tissue (hyperechoic to liver). Multifocal well-demarcated hyperechoic homogenous nodules are noted. Splenic vasculature appears normal.
HOSPITAL NAME	Liver
Dr. Robert Sova	The liver is subjectively normal in size with normal smooth curvilinear peripheral contour. Parenchyma is appropriately hypoechoic to the spleen in echogenicity and appropriately mildly coarse and homogenous in echotexture. No focal lesions are observed. Visible vasculature and biliary tree appear normal without distension or congestion.
REFERRING VET	
Dr. Robert Sova	
INVOICE	Gallbladder is moderately distended with anechoic bile as well as mild to moderate suspended and gravity dependent echogenic debris. The wall is smooth without visible thickening. There is no evidence of cystic or CBD dilation. There is no evidence of effusion or inflammation.
43699	
DATE	Gastrointestinal
12/22/22	



PATIENT	The stomach wall is normal in thickness (canine < 0.5 cm and feline < 0.4 cm) and layering. The lumen of the stomach is empty with no evidence of obstruction, foreign material or infiltrative disease. Pyloric outflow tract appears patent.
Max Anderson	
SPECIES	The visible small intestines are normal in wall thickness and layering (canine duodenum < 0.5 cm and feline duodenum < 0.4 cm; other < 0.3 cm). Small intestinal motility appears adequate (1-3 contractions per min). The lumen of the small intestine is empty with no evidence of obstruction, foreign material or infiltrative disease.
Feline	
BREED	The visible colon is normal in wall thickness (< 0.2 cm) and layering. Contents are consistent with normal formed feces and gas.
Siamese	
SEX	Pancreas
Neutered Male	The pancreatic parenchyma is appropriately isoechoic to surrounding tissue. Visible capsule is smooth and normal in contour. There is no visible pancreatic duct dilation. There is no evidence of active peripancreatic inflammation.
AGE	Free Abdomen
13 Years	There is no evidence of free peritoneal effusion noted in these images.
WEIGHT	There is no apparent lymphadenopathy noted in these images.
10.4 Pounds	
INTERPRETED BY	PRIMARY FINDINGS
Beth Johnson, DVM DACVIM	<ul style="list-style-type: none"> Urinary bladder mineral/sand debris and sediment Mild to moderate gallbladder debris - Cholecystic debris is of unknown clinical significance. It can be seen with biliary stasis from fasting or illness, however, it can also be associated with hepatobiliary disease in cats and should be interpreted in combination with clinical signs such as nausea, inappetence, cranial abdominal discomfort and/or laboratory changes such as increased ALP and/or increased Tbili.
IMAGING PERFORMED BY	SECONDARY FINDINGS
Marco Lichfield	<ul style="list-style-type: none"> Hyperechoic splenic nodules – most consistent with benign myelolipomas. Other differentials such as fibrosis or calcification caused by old hematomas or infarcts, chronic inflammation, granulomatous disease or metastatic disease cannot be ruled out, but are considered less likely.
HOSPITAL NAME	INTERPRETATION OF THE FINDINGS & FURTHER RECOMMENDATIONS
Dr. Robert Sova	If not recently evaluated, a urine culture is recommended.
REFERRING VET	In the face of negative urine culture(s) and no cystoliths, masses, etc., these urinary signs are most consistent with sterile cystitis or feline lower urinary tract disease (FLUTD).
Dr. Robert Sova	Recommendations include maximizing water consumption (water fountains, canned food, etc) as well as reducing stress (recommendations can be found at Indoor Cat Initiative out of The Ohio State University CVM). Transition to a urinary health diet such as Royal Canin Urinary SO (or similar) could also be considered.
INVOICE	
43699	
DATE	
12/22/22	



PATIENT

Max Anderson

SPECIES

Feline

BREED

Siamese

SEX

Neutered Male

AGE

13 Years

WEIGHT

10.4 Pounds

INTERPRETED BY

Beth Johnson, DVM
DACVIM

IMAGING PERFORMED BY

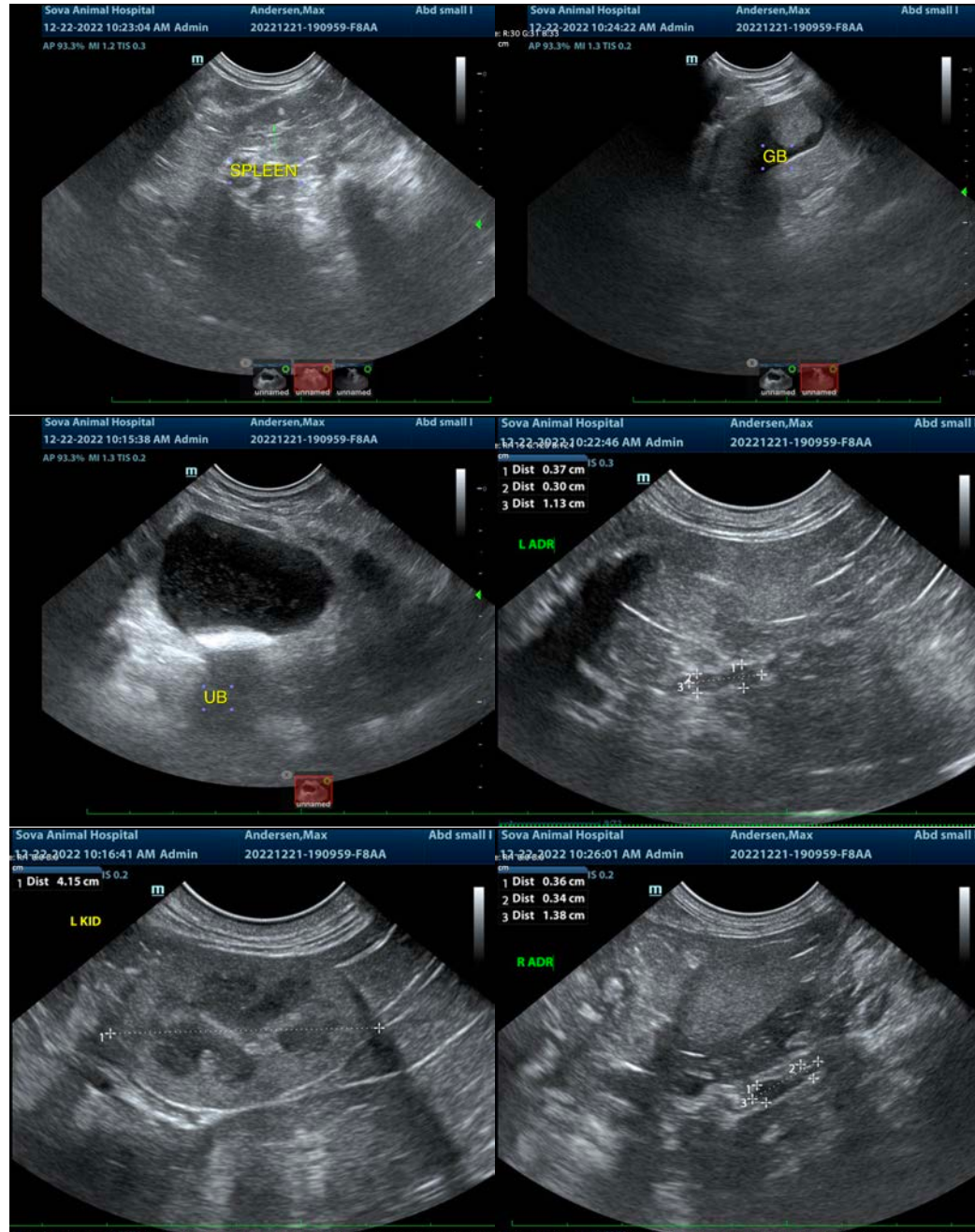
Marco Lichfield

HOSPITAL NAME

Dr. Robert Sova

REFERRING VET

Dr. Robert Sova



INVOICE

43699

DATE

12/22/22



PATIENT

Max Anderson

SPECIES

Feline

BREED

Siamese

SEX

Neutered Male

AGE

13 Years

WEIGHT

10.4 Pounds

INTERPRETED BY

Beth Johnson, DVM
DACVIM

**IMAGING
PERFORMED BY**

Marco Lichfield

HOSPITAL NAME

Dr. Robert Sova

REFERRING VET

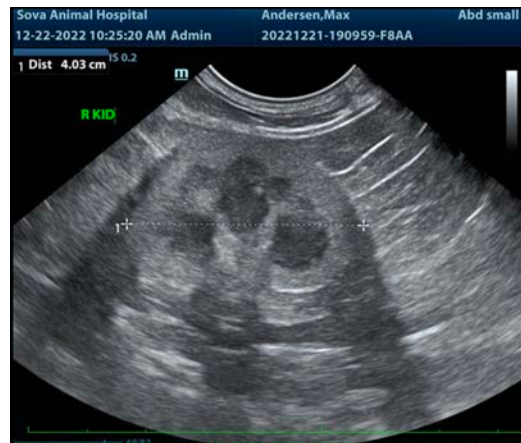Dr. Robert Sova

INVOICE

43699

DATE

12/22/22



The information and recommendations provided are based on the images presented by the referring veterinarian/sonographer. No evaluation can be communicated regarding pathology that was not visible in the image/video clips provided.

Thank you for this referral. If the clinical or image interpretation does not parallel your findings or if I can be of any further assistance please contact me.

Beth Johnson, DVM, DACVIM
Beth.Johnson@sonopath.com