



PATIENT

Ivan Miller-Dick

SPECIES

Canine

BREED

Labrador Retriever

SEX

Neutered Male

AGE

7 Years

WEIGHT

58 Pounds

INTERPRETED BY

Beth Johnson, DVM
DACVIM

IMAGING PERFORMED BY

Dr. Susan Lincoski

HOSPITAL NAME

University Drive VH

REFERRING VET

Dr. Susan Lincoski

INVOICE

43624

DATE

12/22/22

PRESENTING CLINICAL SIGNS

Ivan was scanned previously. He is an OSA patient, limb amputation LF performed 12/2021, chemotherapy done. Diagnosed with FCE (had MRI) left hind 1 month ago, recovered from that but has had some diarrhea off and on. Last night, coughed then brought up some blood. 3 view chest rads results from specialist pending but no new mets (has one primary mass noted several months ago that is actually less visible). Ivan is otherwise BAR

Abnormal PE/Chem/CBC/UA Results: ALT=149, ALKP 288, last done 10/31 and values were ALT=119, ALP=194. All else WNL.

ULTRASONOGRAPHIC EXAMINATION OF THE ABDOMEN

Urinary System

The urinary bladder is moderately distended with anechoic contents. No masses, inflammatory changes, echogenic sediment or cystoliths are observed. The urinary bladder, trigone and visible pelvic urethra are normal in thickness with a smooth mucosal surface.

The area of the prostate is examined without evident pathology.

The right kidney is normal in size (8.19 cm), shape and echogenicity. It has smooth peripheral margination. There is a normal 1:3 cortex to medulla ratio with appropriate corticomedullary distinction. There is no evidence of pyelectasia, mineral or infarcts observed.

This patient does not have a left kidney.

Adrenal Glands

The right adrenal gland is normal in size (1.27 cm long x 0.37 cm), shape and contour. Corticomedullary structure is unremarkable. Visible surrounding vasculature appears normal.

The left adrenal gland is normal in size (1.92 cm long x 0.53 cm), shape and contour. Corticomedullary structure is unremarkable. Visible surrounding vasculature appears normal.

Spleen

The spleen is subjectively normal in size with a normal smooth capsular contour. Parenchyma is appropriately finely textured and homogenous with normal echogenicity relative to surrounding tissue (hyperechoic to liver). No focal nodules or masses are observed. Splenic vasculature appears normal.

Liver

The liver is subjectively normal in size with normal smooth curvilinear peripheral contour. Parenchyma is appropriately hypoechoic to the spleen in echogenicity and appropriately mildly coarse and homogenous in echotexture. No focal lesions are observed. Visible vasculature and biliary tree appear normal without distension or congestion.

The gallbladder is non-distended in size. The wall is smooth without visible thickening. Luminal contents are primarily anechoic. There is no evidence of cystic or common bile duct dilation.

Gastrointestinal

The visible stomach wall is normal in thickness and layering. The lumen of the stomach is mildly distended with very echogenic reverberation artifact from intraluminal gas. There is no evidence of obstruction, foreign material or infiltrative disease; however, complete visualization of far wall is partially inhibited by gas. Pyloric outflow tract appears patent.



PATIENT

Ivan Miller-Dick

The visible small intestines are normal in wall thickness and layering (canine duodenum < 0.5 cm and feline duodenum < 0.4 cm; other < 0.3 cm). Small intestinal motility appears adequate (1-3 contractions per min). The lumen of the small intestine is empty with no evidence of obstruction, foreign material or infiltrative disease.

SPECIES

Canine

The visible colon is normal in wall thickness (< 0.2 cm) and layering. The colon contains soft stool.

Pancreas

BREED

Labrador Retriever

The pancreatic parenchyma is appropriately isoechoic to surrounding tissue. Visible capsule is smooth and normal in contour. There is no visible pancreatic duct dilation. There is no evidence of active peripancreatic inflammation.

Free Abdomen

SEX

Neutered Male

There is no evidence of free peritoneal effusion noted in these images.

The mesenteric lymph nodes are prominent in size with swollen capsular contour. Normal elongated shape (length to width ratio) is maintained. There is no loss of parenchymal detail.

AGE

7 Years

ULTRASONOGRAPHIC FINDINGS

- **Reactive mesenteric lymph nodes** – infiltrative neoplastic disease cannot be ruled out but is considered less likely.
- **Soft stool** – Consistent with this patient’s reported history of diarrhea.
- An obvious cause for the reported increased liver enzymes is not identified in these images. Microscopic disease such as Leptospirosis, bacterial cholangiohepatitis, chronic active hepatitis, copper-associated hepatotoxicity, other hepatotoxicity, infiltrative neoplasia (considered unlikely), etc. cannot be definitively ruled out.
- There is no left kidney.

WEIGHT

58 Pounds

INTERPRETED BY

Beth Johnson, DVM
DACVIM

INTERPRETATION OF THE FINDINGS & FURTHER RECOMMENDATIONS

Given this patient’s reported diarrhea, further evaluation of the GI tract could be considered, beginning with a gastrointestinal malabsorption panel (including cobalamin, folate, TLI and PLI) to Texas A&M GI Laboratory.

A fecal exam is recommended if not recently evaluated.

A fecal enteropathogen PCR panel to Texas A&M GI Laboratory could be considered for further evaluation of possible infectious disease.

In the meantime, empirical deworming with a 5-day course of Panacur is recommended, as is a probiotic such as Visbiome or Provable, as well as potentially (based on trial and error response) a diet transition to a bland, easy to digest diet, or potentially even hypoallergenic hydrolyzed diet, etc.

INVOICE

43624

Given this patient’s reported coughing that contained blood, further evaluation of coagulation status is recommended if not recently evaluated, including PT, PTT, and platelet count. If coughing persists and thoracic radiographs do not reveal a cause, given this patient’s reported historical pulmonary mass, a thoracic CT could be considered.

DATE

12/22/22



PATIENT

Ivan Miller-Dick

SPECIES

Canine

BREED

Labrador Retriever

SEX

Neutered Male

AGE

7 Years

WEIGHT

58 Pounds

INTERPRETED BY

Beth Johnson, DVM
DACVIM

IMAGING PERFORMED BY

Dr. Susan Lincoski

HOSPITAL NAME

University Drive VH

REFERRING VET

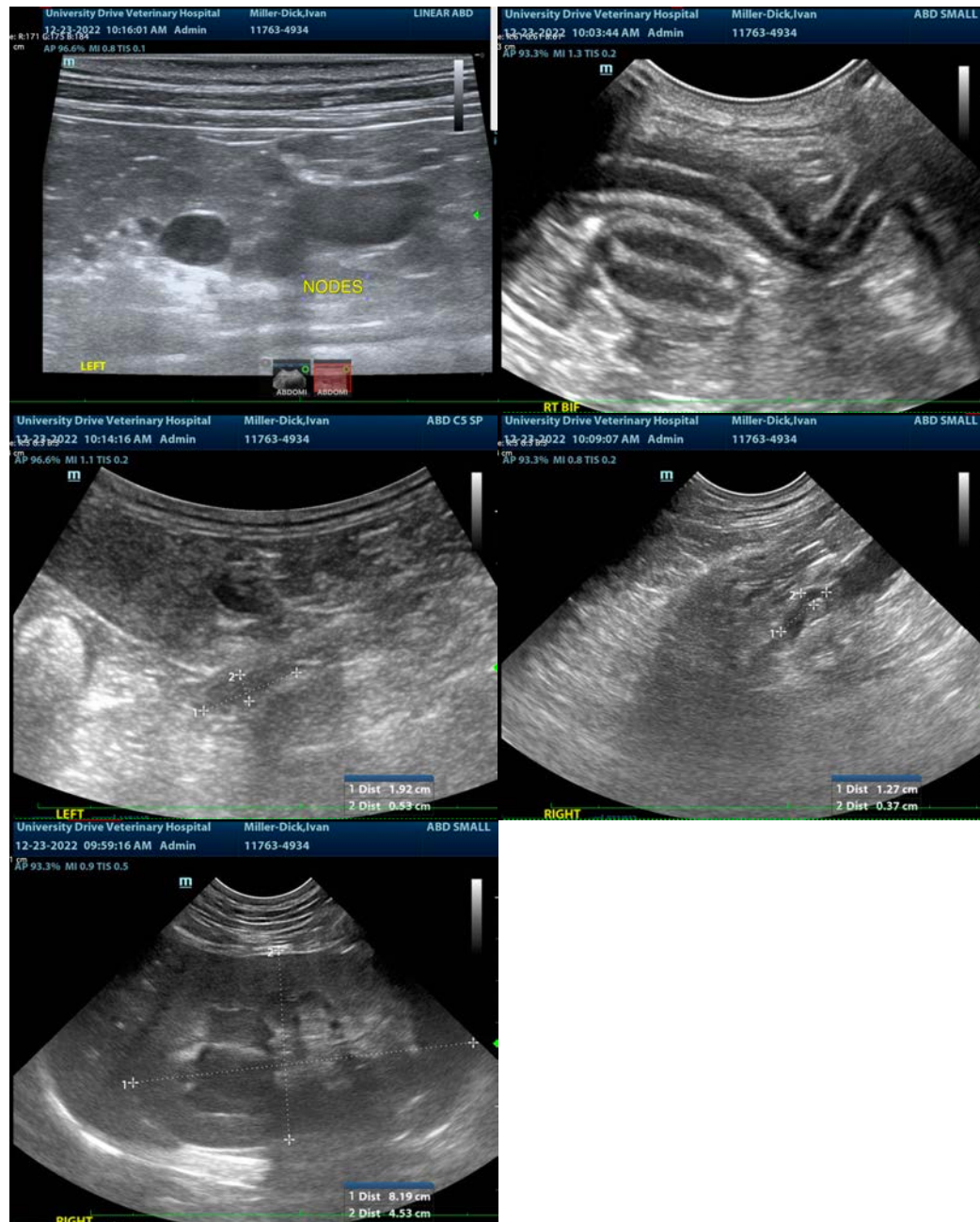
Dr. Susan Lincoski

INVOICE

43624

DATE

12/22/22



The information and recommendations provided are based on the images presented by the referring veterinarian/sonographer. No evaluation can be communicated regarding pathology that was not visible in the image/video clips provided.

Thank you for this referral. If the clinical or image interpretation does not parallel your findings or if I can be of any further assistance please contact me.

Beth Johnson, DVM, DACVIM
Beth.Johnson@sonopath.com