



PATIENT PRESENTING CLINICAL SIGNS

Cooper Esther Multifocal variable sized SQ masses. Mild truncal hair thinning BCS 7/9 Grade 2/3 dental calculous accumulation, gingivitis 2/4

SPECIES

Canine

Abnormal PE/Chem/CBC/UA Results: Mild elevated ALP (214) WNL

BREED

English Springer
Spaniel

ULTRASONOGRAPHIC EXAMINATION OF THE ABDOMEN

Urinary System

The urinary bladder is moderately distended with anechoic contents. No masses, inflammatory changes, echogenic sediment or cystoliths are observed. The urinary bladder, trigone and visible pelvic urethra are normal in thickness with a smooth mucosal surface.

SEX

Neutered Male

Prostate is normal in size, echotexture and echogenicity for a neutered male.

AGE

12 Years

Kidneys are overall normal in size and shape with smooth peripheral margination. A normal 1:3 cortex to medulla ratio is maintained. The medulla and cortices are uniform in texture with some mild increased cortical echogenicity and mild loss of corticomedullary distinction, expected in this age patient. There is no evidence of pyelectasia, mineral or infarcts observed. Small bilateral cortical cysts are present. The right kidney measures 5.92 cm. The left kidney measures 5.67 cm.

WEIGHT

48 Pounds

Adrenal Glands

Adrenal glands are plump/swollen in size. Normal shape and contour are maintained without evidence of capsular invasion. Corticomedullary structure is unremarkable. Visible surrounding vasculature appears normal. The right adrenal gland measures 2.67 cm long x 1.46 cm at the cranial pole and 1.01 cm at the caudal pole. The left adrenal gland measures 2.78 cm long x 1.04 cm at the cranial pole and 0.87 cm at the caudal pole.

INTERPRETED BY

Beth Johnson, DVM
DACVIM

Spleen

The spleen is subjectively normal in size with a normal smooth capsular contour. Parenchyma is appropriately finely textured and homogenous with normal echogenicity relative to surrounding tissue (hyperechoic to liver). No focal nodules or masses are observed. Splenic vasculature appears normal.

IMAGING PERFORMED BY

Sara Hansen

Liver

The liver is subjectively normal in size with normal smooth curvilinear peripheral contour. Parenchyma is appropriately hypoechoic to the spleen in echogenicity and appropriately mildly coarse and homogenous in echotexture. No focal lesions are observed. Visible vasculature and biliary tree appear normal without distension or congestion.

HOSPITAL NAME

VCA Salem AH

REFERRING VET

Dr. Reed

The gallbladder is non-distended in size. The wall is smooth without visible thickening. Luminal contents are primarily anechoic. There is no evidence of cystic or common bile duct dilation.

INVOICE

43679

Gastrointestinal

DATE

12/22/22

The stomach wall is normal in thickness (canine < 0.5 cm and feline < 0.4 cm) and layering. The lumen of the stomach is empty with no evidence of obstruction, foreign material or infiltrative disease. Pyloric outflow tract appears patent.



PATIENT

Cooper Esther

The visible small intestines are normal in wall thickness and layering (canine duodenum < 0.5 cm and feline duodenum < 0.4 cm; other < 0.3 cm). Small intestinal motility appears adequate (1-3 contractions per min). The lumen of the small intestine is empty with no evidence of obstruction, foreign material or infiltrative disease.

SPECIES

Canine

The visible colon is normal in wall thickness (< 0.2 cm) and layering. Contents are consistent with normal formed feces and gas.

BREED

English Springer
Spaniel

Pancreas

The pancreatic parenchyma is appropriately isoechoic to surrounding tissue. Visible capsule is smooth and normal in contour. There is no visible pancreatic duct dilation. There is no evidence of active peripancreatic inflammation.

SEX

Neutered Male

Free Abdomen

There is no evidence of free peritoneal effusion noted in these images.

AGE

12 Years

There is no apparent lymphadenopathy noted in these images.

WEIGHT

48 Pounds

- **Bilateral adrenomegaly** – consistent with adrenal hyperplasia secondary to pituitary dependent hyperadrenocorticism vs stress or normal variant. Interpret in combination with clinical signs of hyperadrenocorticism.

INTERPRETED BY

Beth Johnson, DVM
DACVIM

SECONDARY FINDINGS

- Age related kidneys with multifocal bilateral small cortical cysts

INTERPRETATION OF THE FINDINGS & FURTHER RECOMMENDATIONS

IMAGING PERFORMED BY

Sara Hansen

The described adrenal gland changes combined with this patient's history of increased ALP could be suggestive of hyperadrenocorticism. If clinical signs of hyperadrenocorticism, such as polyuria, polydipsia, polyphagia, panting, hair loss, hypertension, etc. are present, testing for hyperadrenocorticism with a LDDS test is warranted. If a LDDS test has been evaluated with a normal result, investigation of possible atypical hyperadrenocorticism with a full ACTH stimulation adrenal panel to the University of Tennessee could be considered. If clinical signs are not present, monitoring is recommended with testing pursued when/if clinical signs develop. Regardless of clinical signs, if not recently evaluated, blood pressure is recommended. If not recently evaluated, a urinalysis and, if indicated based on urinalysis results, urine culture are also recommended. If protein is present in an otherwise quiet sediment, protein quantification with a urine protein to creatinine ratio is recommended.

HOSPITAL NAME

VCA Salem AH

REFERRING VET

Dr. Reed

INVOICE

43679

DATE

12/22/22



PATIENT

Cooper Esther

SPECIES

Canine

BREED

English Springer
Spaniel

SEX

Neutered Male

AGE

12 Years

WEIGHT

48 Pounds

INTERPRETED BY

Beth Johnson, DVM
DACVIM

IMAGING PERFORMED BY

Sara Hansen

HOSPITAL NAME

VCA Salem AH

REFERRING VET

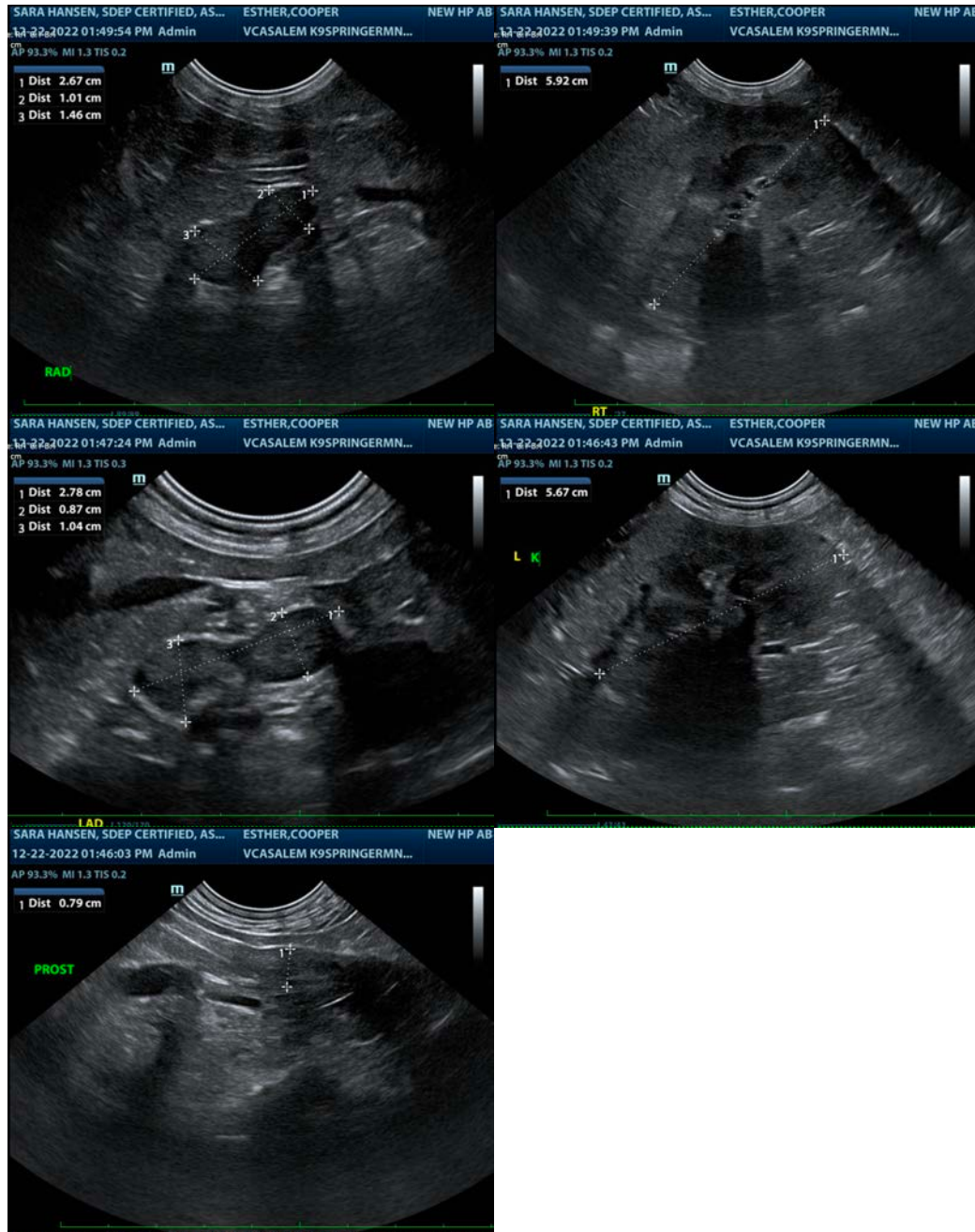
Dr. Reed

INVOICE

43679

DATE

12/22/22



The information and recommendations provided are based on the images presented by the referring veterinarian/sonographer. No evaluation can be communicated regarding pathology that was not visible in the image/video clips provided.

Thank you for this referral. If the clinical or image interpretation does not parallel your findings or if I can be of any further assistance please contact me.

Beth Johnson, DVM, DACVIM
 Beth.Johnson@sonopath.com