

IMAGING PERFORMED BY

IntraPet.com



SonoPath

Clinical Sonography & Telectology

EDUCATIONAL TELECONSULTATION SERVICES™

1-800-838-4268 info@sonopath.com SonoPath.com

DATE PRESENTING CLINICAL SIGNS

12/21/22

Pet presented on 10/14/22 for routine senior exam and bloodwork. On PE pet was BAR and relatively healthy. Only abnormality was a small SQ mass noted right ventrolateral mid thorax. Senior bloodwork was completed and found an elevated ALP. Pet was started on Denamarin Advanced and recheck liver values one month later revealed worsening ALP value.

PATIENT

Denver Bandell

SPECIES

Canine

BREED

Labrador X

SEX

Neutered Male

AGE

5/5/15

WEIGHT

81 Pounds

INTERPRETED BY

Beth Johnson, DVM
DACVIM

IMAGING PERFORMED BY

Rachel Brilhart RDMS

HOSPITAL NAME

Wetminster VH

REFERRING VET

Dr. Hall

INVOICE

43637

Current Medications: None.

Lab Results: 10/14/22: CBC: Normal; Chemistry: ALP: 654U/L (5-160); UA: Protein: 1+; Ketones: 1+; Bilirubin: 1+; Epi Cells: 1+; 3+ ammonium mg phosphate. 12/2/22: ALP: 1029U/L (5-160)

Date of Previous IntraPet Ultrasound: No previous.

Sedation: Butorphanol 0.2mg/kg IV (0.74mL).

Stat Report: Not requested.

ULTRASONOGRAPHIC EXAMINATION OF THE ABDOMEN

Urinary System

The urinary bladder is moderately distended with anechoic contents. No masses, inflammatory changes, echogenic sediment or cystoliths are observed. The urinary bladder, trigone and visible pelvic urethra are normal in thickness with a smooth mucosal surface.

Prostate is normal in size, echotexture and echogenicity for a neutered male.

The right kidney is normal in size (5.72 cm), shape and echogenicity. It has smooth peripheral margination. There is a normal 1:3 cortex to medulla ratio with appropriate corticomedullary distinction. There is no evidence of pyelectasia, mineral or infarcts observed.

The left kidney is normal in size (7.1 cm), shape and echogenicity. It has smooth peripheral margination. There is a normal 1:3 cortex to medulla ratio with appropriate corticomedullary distinction. There is no evidence of pyelectasia, mineral or infarcts observed.

Adrenal Glands

The right adrenal gland is normal in size (2.95 cm long x 0.82 cm at the cranial pole and 0.77 cm at the caudal pole), shape and contour. Corticomedullary structure is unremarkable. Visible surrounding vasculature appears normal.

The left adrenal gland is normal in size (3.56 cm long x 0.73 cm at the cranial pole and 0.81 cm at the caudal pole), shape and contour. Corticomedullary structure is unremarkable. Visible surrounding vasculature appears normal.

Spleen

The spleen is subjectively normal in size with a normal smooth capsular contour. Parenchyma is appropriately finely textured and homogenous with normal echogenicity relative to surrounding tissue (hyperechoic to liver). No focal nodules or masses are observed. Splenic vasculature appears normal.

Liver

Liver is subjectively enlarged with mildly irregular margins. Parenchyma is heterogenous characterized by multiple poorly defined hypoechoic nodules within otherwise hyperechoic liver parenchyma. Visible vasculature and biliary tree appear normal without distension or congestion.

The gallbladder is non-distended in size. The wall is smooth without visible thickening. Luminal contents are primarily anechoic. There is no evidence of cystic or common bile duct dilation.

Gastrointestinal

The stomach wall is normal in thickness (canine < 0.5 cm and feline < 0.4 cm) and layering. The lumen of the stomach is empty with no evidence of obstruction, foreign material or infiltrative disease. Pyloric outflow tract appears patent.

The visible small intestines are normal in wall thickness and layering (canine duodenum < 0.5 cm and feline duodenum < 0.4 cm; other < 0.3 cm). Small intestinal motility appears adequate (1-3 contractions per min). The lumen of the small intestine is empty with no evidence of obstruction, foreign material or infiltrative disease.

The visible colon is normal in wall thickness (< 0.2 cm) and layering. Contents are consistent with normal formed feces and gas.

Pancreas

The pancreatic parenchyma is appropriately isoechoic to surrounding tissue. Visible capsule is smooth and normal in contour. There is no visible pancreatic duct dilation. There is no evidence of active peripancreatic inflammation.

Free Abdomen

There is no evidence of free peritoneal effusion noted in these images.

The mesenteric lymph nodes are prominent in size with swollen capsular contour. Normal elongated shape (length to width ratio) is maintained. There is no loss of parenchymal detail.

ULTRASONOGRAPHIC FINDINGS

- **Heterogenous Liver** – These changes are most consistent with benign processes such as nodular hyperplasia, steroid (vacuolar) hepatopathy, extramedullary hematopoiesis or possibly chronic inflammatory disease and less commonly infiltrative round cell or metastatic neoplasia.
- **Reactive mesenteric lymph nodes** – infiltrative neoplastic disease cannot be ruled out but is considered less likely.

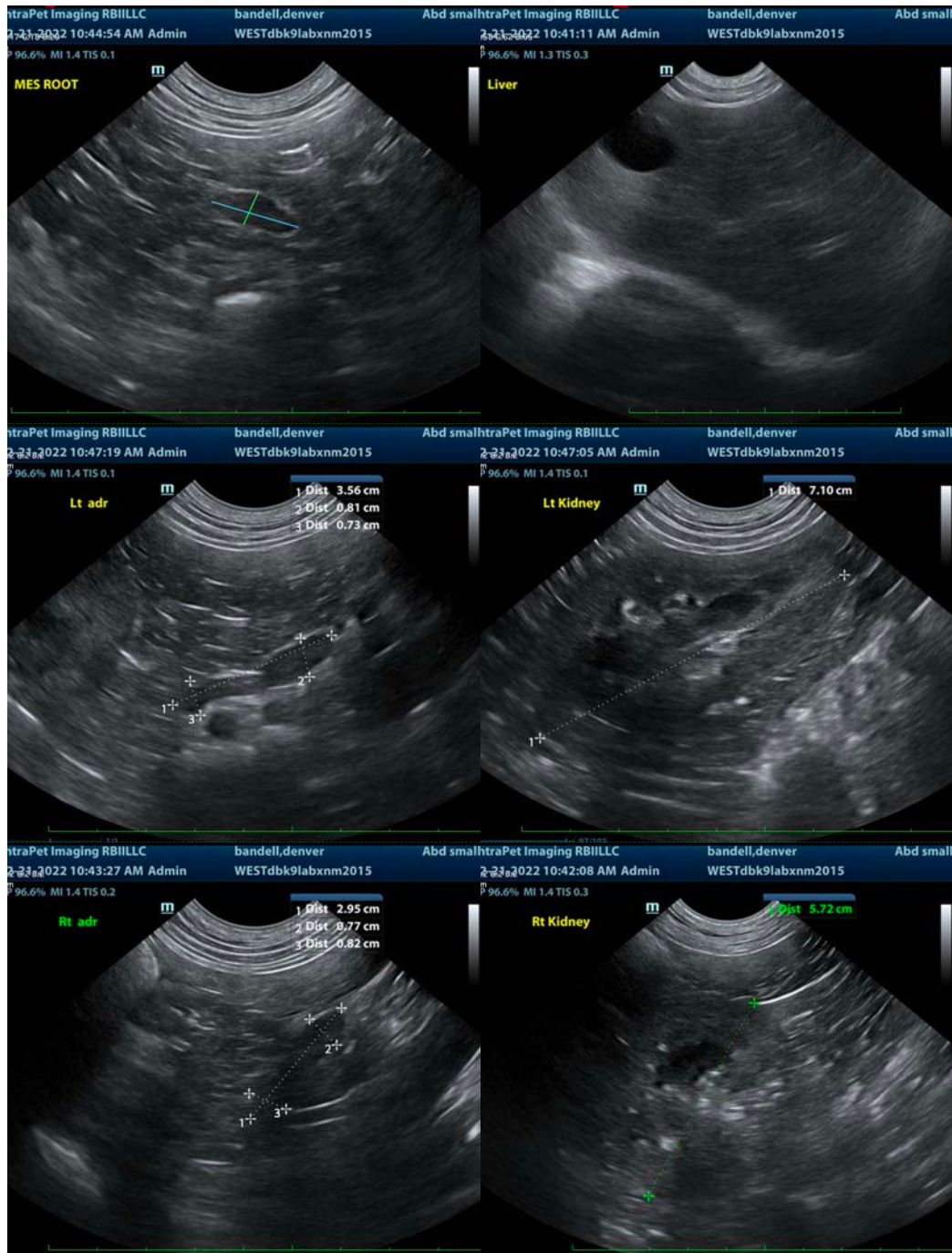
INTERPRETATION OF THE FINDINGS & FURTHER RECOMMENDATIONS

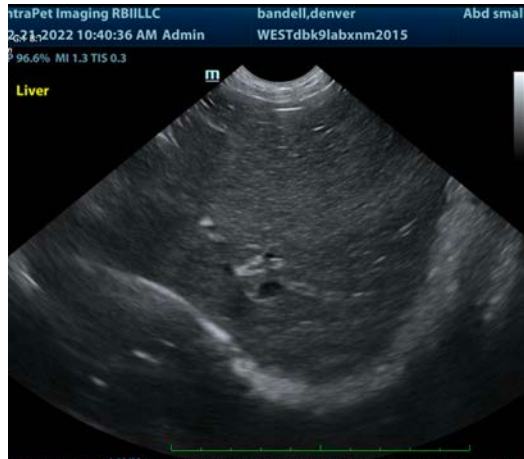Differentials for increased ALP are vast and non-specific. Differentials include, but are not limited to, benign nodular hyperplasia which occurs in 70% of older dogs and often does not result in an abnormal ultrasound, reactive or idiopathic/vacuolar hepatopathy, cholestasis and/or hyperadrenocorticism as well as many chronic non-hepatobiliary diseases such as chronic infections/inflammation from dental disease, IBD, neoplasia, hyperlipidemia, hypothyroidism, chronic pancreatitis, chronic stress, etc.

There is no ultrasonographic evidence of cholestasis. Adrenocortical testing such as a low dose dexamethasone suppression test could be considered if clinical signs of hyperadrenocorticism are present. Ursodiol could be considered if gallbladder sludge is noted. A fine needle aspirate of the liver could be considered if patient's coagulation status is appropriate. Otherwise, recommendations include addressing any other concurrent disease and monitoring. If values are progressive, recheck imaging is recommended.

Specifically for this patient, given the reactive mesenteric lymph nodes, empirical deworming with a 5-day course of Panacur is recommended.

If gastrointestinal signs are present, further evaluation of the GI tract and pancreas may be warranted with a gastrointestinal malabsorption panel (including cobalamin, folate, TLI and PLI) to Texas A&M GI Laboratory.





The information and recommendations provided are based on the images presented by the referring veterinarian/sonographer. No evaluation can be communicated regarding pathology that was not visible in the image/video clips provided.

Thank you for this referral. If the clinical or image interpretation does not parallel your findings or if I can be of any further assistance please contact me.

Beth Johnson, DVM, DACVIM
Beth.Johnson@sonopath.com