

**DATE PRESENTING CLINICAL SIGNS**

12/20/22

Persistent vomiting and weight loss, vomiting daily for months. Activity level WNL. Treated with Famotidine, Cerenia - Cerenia effective, RC HP not effective. PE WNL -no masses.

**PATIENT**

Trace Burke

Current Medications: Cerenia inj,

Lab Results: NSF.

Radiographs: See attached.

Date of Previous IntraPet Ultrasound: No previous.

Sedation: Not required to complete full diagnostic ultrasound.

Stat Report: Not requested.

**SPECIES**

Feline

**BREED**

DSH

**SEX**

Neutered Male

**AGE**

5/1/09

**WEIGHT**

10.25 Pounds

**INTERPRETED BY**

Beth Johnson, DVM  
DACVIM

**IMAGING PERFORMED BY**

Andi Parkinson RDMS

**HOSPITAL NAME**

Festival Vet Clinic

**REFERRING VET**

Dr. Prange

**INVOICE**

43586

**ULTRASONOGRAPHIC EXAMINATION OF THE ABDOMEN****Urinary System**

Urinary bladder is adequately distended. It has a normal uniform wall thickness. Contents include primarily anechoic fluid with occasional echogenic non-shadowing debris, most consistent with incidental suspended lipid in a cat, possibly combined with exfoliated cells, mucous and/or small blood clots. Both sterile inflammation as well as urinary tract infection can also present with echogenic debris. No masses or cystoliths are observed. The trigone and visible pelvic urethra are normal in thickness with a smooth mucosal surface.

The right kidney is normal in size (3.69 cm), shape and echogenicity. It has smooth peripheral margination. There is a normal 1:3 cortex to medulla ratio with appropriate corticomedullary distinction. There is no evidence of pyelectasia, mineral or infarcts observed.

The left kidney is normal in size (3.67 cm), shape and echogenicity. It has smooth peripheral margination. There is a normal 1:3 cortex to medulla ratio with appropriate corticomedullary distinction. There is no evidence of pyelectasia, mineral or infarcts observed.

**Adrenal Glands**

The right adrenal gland is normal in size (0.45 cm), shape and contour. Corticomedullary structure is unremarkable. Visible surrounding vasculature appears normal.

The area of the left adrenal gland is examined without evident adrenal gland pathology.

**Spleen**

The spleen is subjectively normal in size with a normal smooth capsular contour. Parenchyma is appropriately finely textured and homogenous with normal echogenicity relative to surrounding tissue (hyperechoic to liver). No focal nodules or masses are observed. Splenic vasculature appears normal.

**Liver**

The liver is subjectively normal in size with normal smooth curvilinear peripheral contour. Parenchyma is appropriately hypoechoic to the spleen in echogenicity and appropriately mildly coarse and homogenous in echotexture. In the right liver, a 4.3 cm x 4.0 cm mass of mixed echogenicity is noted, primarily hyperechoic but containing multiple cysts of varying size. Visible vasculature and biliary tree appear normal without distension or congestion.

The gallbladder is non-distended in size. The wall is smooth without visible thickening. Luminal contents are primarily anechoic. There is no evidence of cystic or common bile duct dilation.

### ***Gastrointestinal***

Diffusely, the stomach wall is normal in thickness (canine < 0.5 cm and feline < 0.4 cm) and layering. However, focally, approaching the pylorus, the wall is diffusely thick measuring 0.94 cm thick with hypoechoic appearance and loss of layering. The lumen of the stomach is empty with no evidence of obstruction, foreign material or infiltrative disease. Pyloric outflow tract appears patent.

The visible small intestines are normal in wall thickness and layering (canine duodenum < 0.5 cm and feline duodenum < 0.4 cm; other < 0.3 cm). Small intestinal motility appears adequate (1-3 contractions per min). The lumen of the small intestine is empty with no evidence of obstruction, foreign material or infiltrative disease.

The visible colon is normal in wall thickness (< 0.2 cm) and layering. Contents are consistent with normal formed feces and gas.

### ***Pancreas***

The pancreatic parenchyma is appropriately isoechoic to surrounding tissue. Visible capsule is smooth and normal in contour. There is no visible pancreatic duct dilation. There is no evidence of active peripancreatic inflammation.

### ***Free Abdomen***

There is no evidence of free peritoneal effusion noted in these images.

There is no apparent lymphadenopathy noted in these images.

## **PRIMARY FINDINGS**

- **Gastric wall/pyloric thickening with loss of layering** – concerning for infiltrative neoplasia such as lymphoma. A benign inflammatory change is possible but considered less likely.
- **Feline biliary cystadenoma** – In a senior cat, this liver lesion is most consistent with a/multiple benign biliary cystadenoma(s). Malignancy cannot be ruled out but is considered less likely give lack of clinical signs and/or laboratory changes.

## **SECONDARY FINDINGS**

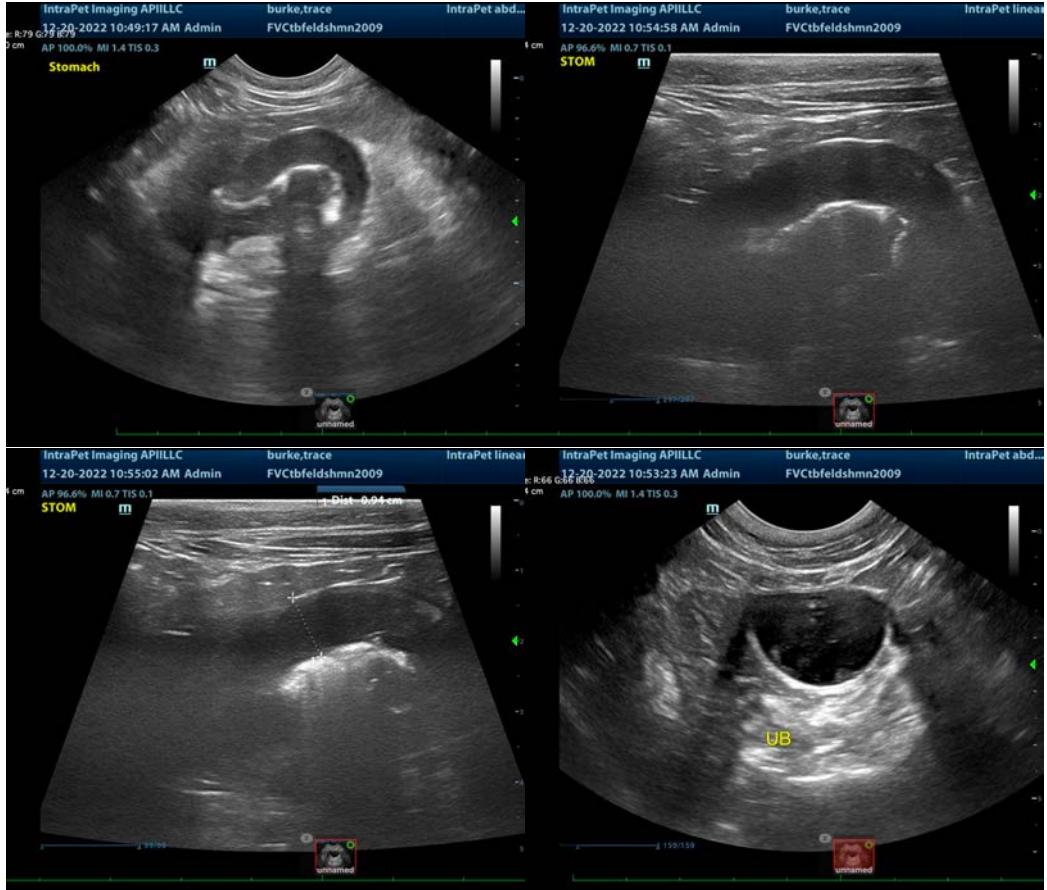
- Urinary bladder debris

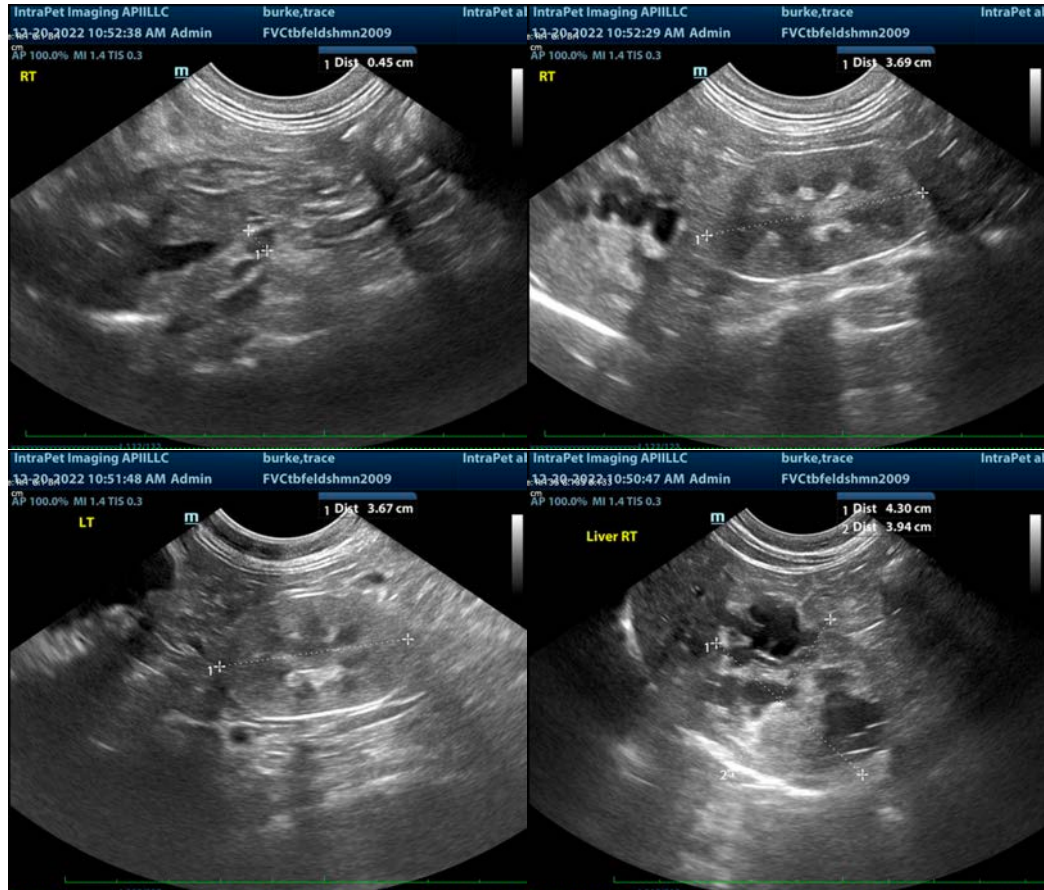
## **INTERPRETATION OF THE FINDINGS & FURTHER RECOMMENDATIONS**

Three view thoracic radiographs are recommended for further assessment of cardio-pulmonary status as well as to further evaluate for any evidence of metastatic disease, if not recently evaluated.

Urinalysis and, if indicated based on urinalysis results, urine culture are recommended. If protein is present in an otherwise quiet sediment, protein quantification with a urine protein to creatinine ration is recommended.

A fine needle aspirate of the gastric wall/pylorus thickening is recommended, if possible to safely reach and if patient's coagulation status is appropriate. Alternatively, or if a cytologic diagnosis cannot be obtained, gastroscopy could be considered for endoscopic biopsies.





The information and recommendations provided are based on the images presented by the referring veterinarian/sonographer. No evaluation can be communicated regarding pathology that was not visible in the image/video clips provided.

Thank you for this referral. If the clinical or image interpretation does not parallel your findings or if I can be of any further assistance please contact me.

**Beth Johnson, DVM, DACVIM**  
Beth.Johnson@sonopath.com