



## PATIENT

Zoey Geroulo

## SPECIES

Canine

## BREED

Pit Bull

## SEX

Spayed Female

## AGE

4 Years 2 Months

## WEIGHT

64

## INTERPRETED BY

Beth Johnson, DVM  
DACVIM

## IMAGING PERFORMED BY

Jessica Green

## HOSPITAL NAME

Stanglein Veterinary  
Clinic

## REFERRING VET

Dr. Katrina Lobst

## INVOICE

72256

## DATE

12/2/25

## PRESENTING CLINICAL SIGNS

4yo FS Pitbull with persistent vomiting in the morning for about 1 month - often clear foam, occasionally bile, occasionally kibble +/- grass. Non-responsive to bland diet and addition of Famotidine (Pepcid) 10mg 1.5t (15mg = 0.52mg/kg) PO q24h in the evening. Mildly decreased energy but good appetite, normal otherwise.

Abnormal PE/Chem/CBC/UA Results: All CBC/Chem/UA values WNL except CK 279 (N = 10-200). T4 normal @ 2.6 (N = 1.0-4.0). RADS: unremarkable

## ULTRASONOGRAPHIC EXAMINATION OF THE ABDOMEN

### Urinary System

The urinary bladder is adequately distended with anechoic contents. No masses, inflammatory changes, echogenic sediment or cystoliths are observed. The urinary bladder, trigone and visible pelvic urethra are normal in thickness with a smooth mucosal surface.

The right kidney is normal is size (6.6 cm), shape and echogenicity. It has smooth peripheral margination. There is a normal 1:3 cortex to medulla ratio with appropriate corticomedullary distinction. There is no evidence of pyelectasia, mineral or infarcts observed.

The left kidney is normal is size (6.6 cm), shape and echogenicity. It has smooth peripheral margination. There is a normal 1:3 cortex to medulla ratio with appropriate corticomedullary distinction. There is no evidence of pyelectasia, mineral or infarcts observed.

### Adrenal Glands

The right adrenal gland is normal in size (0.60 cm at cranial pole and 0.56 cm at caudal pole), shape and overall architecture, echogenicity and echotexture. Visible surrounding vasculature appears normal.

The left adrenal gland is normal in size (0.57 cm at cranial pole and 0.62 cm at caudal pole), shape and overall architecture, echogenicity and echotexture. Visible surrounding vasculature appears normal.

### Spleen

Spleen is subjectively large in size (2.9 cm thick at the hilus) with a mildly swollen but smooth capsule. Parenchyma is normal and homogenous in echogenicity and echotexture. No focal nodules or masses are observed. Splenic vasculature appears normal.

### Liver

The liver is subjectively very mildly small in size with normal smooth curvilinear peripheral contour. Parenchyma is appropriately hypoechoic to the spleen in echogenicity and appropriately mildly coarse and homogenous in echotexture. No focal lesions are observed. Visible vasculature and biliary tree appear normal without distension or congestion.

The gallbladder is non-distended in size. The wall is smooth without visible thickening. Luminal contents are primarily anechoic. There is no evidence of cystic or common bile duct dilation.

### Gastrointestinal

The visible stomach wall is normal in thickness and layering. The lumen of the stomach is empty with no evidence of obstruction, foreign material or infiltrative disease. Pyloric outflow tract appears patent.



## PATIENT

Zoey Geroulo

## SPECIES

Canine

## BREED

Pit Bull

## SEX

Spayed Female

## AGE

4 Years 2 Months

## WEIGHT

64

## INTERPRETED BY

Beth Johnson, DVM  
DACVIM

## IMAGING PERFORMED BY

Jessica Green

## HOSPITAL NAME

Stanglein Veterinary  
Clinic

## REFERRING VET

Dr. Katrina Lobst

## INVOICE

72256

## DATE

12/2/25

The visible small intestines are normal in wall thickness and layering. Small intestinal motility appears adequate (1-3 contractions per min). The lumen of the small intestine is empty with no evidence of obstruction, foreign material or infiltrative disease.

The visible colon is normal in wall thickness (< 0.2 cm) and layering. Contents are consistent with normal formed feces and gas.

### **Pancreas**

The pancreas that is observed appears appropriately isoechoic to surrounding omental fat. Visible capsule is smooth and normal in contour. Visible pancreatic parenchyma is homogenous and unremarkable. There is no visible pancreatic duct dilation. There is no evidence of active peripancreatic inflammation.

### **Free Abdomen**

There is no visible free peritoneal effusion noted in these images.

There is no apparent pathologic lymphadenopathy noted in these images.

## **ULTRASONOGRAPHIC FINDINGS**

- Mild splenomegaly – can be associated with congestion caused by sedation (if sedated) but can also be associated with diffuse infiltrative disease. Both benign conditions such as extramedullary hematopoiesis, lymphoid hyperplasia, as well as infiltrative neoplastic diseases such as round cell neoplasia should be considered.
- Subjective/possible microhepatica – Could be normal patient variant, as ultrasound is not the most specific diagnostic for liver size, but liver disease including vascular anomaly can't be definitively ruled out.

## **INTERPRETATION OF THE FINDINGS & FURTHER RECOMMENDATIONS**

Given patient's history, a baseline cortisol is recommended. If baseline cortisol is less than 2, a full ACTH stimulation test is recommended to rule out hypoadrenocorticism.

A gastrointestinal malabsorption panel (including cobalamin, folate, TLI and PLI) to Texas A&M GI Laboratory is recommended for further evaluation of GI and pancreatic function.

Routine fecal/giardia exam is recommended.

Bile acids could be considered if patient's total bilirubin is not increased.

In the meantime, supportive/symptomatic medical management of clinical signs is recommended, including anti-emetics, gastroprotectants (+/- sucralfate, especially with any history of hematemesis), an appetite stimulant and fluid therapy if indicated, etc.

Additionally, empirical deworming with a 5-day course of Panacur is recommended as is a full course of empirical Helicobacter triple therapy.

Finally, if tolerated, a transition in diet could be considered, based on trial-and-error response with some options to consider including a gastrointestinal biome diet vs a hydrolyzed protein diet (sometimes several trials with different brands are necessary) vs an easy to digest, bland or low-fat diet vs other.



**PATIENT**

Zoey Geroulo

**SPECIES**

Canine

**BREED**

Pit Bull

**SEX**

Spayed Female

**AGE**

4 Years 2 Months

**WEIGHT**

64

**INTERPRETED BY**

Beth Johnson, DVM  
DACVIM

**IMAGING PERFORMED BY**

Jessica Green

**HOSPITAL NAME**

Stanglein Veterinary  
Clinic

**REFERRING VET**

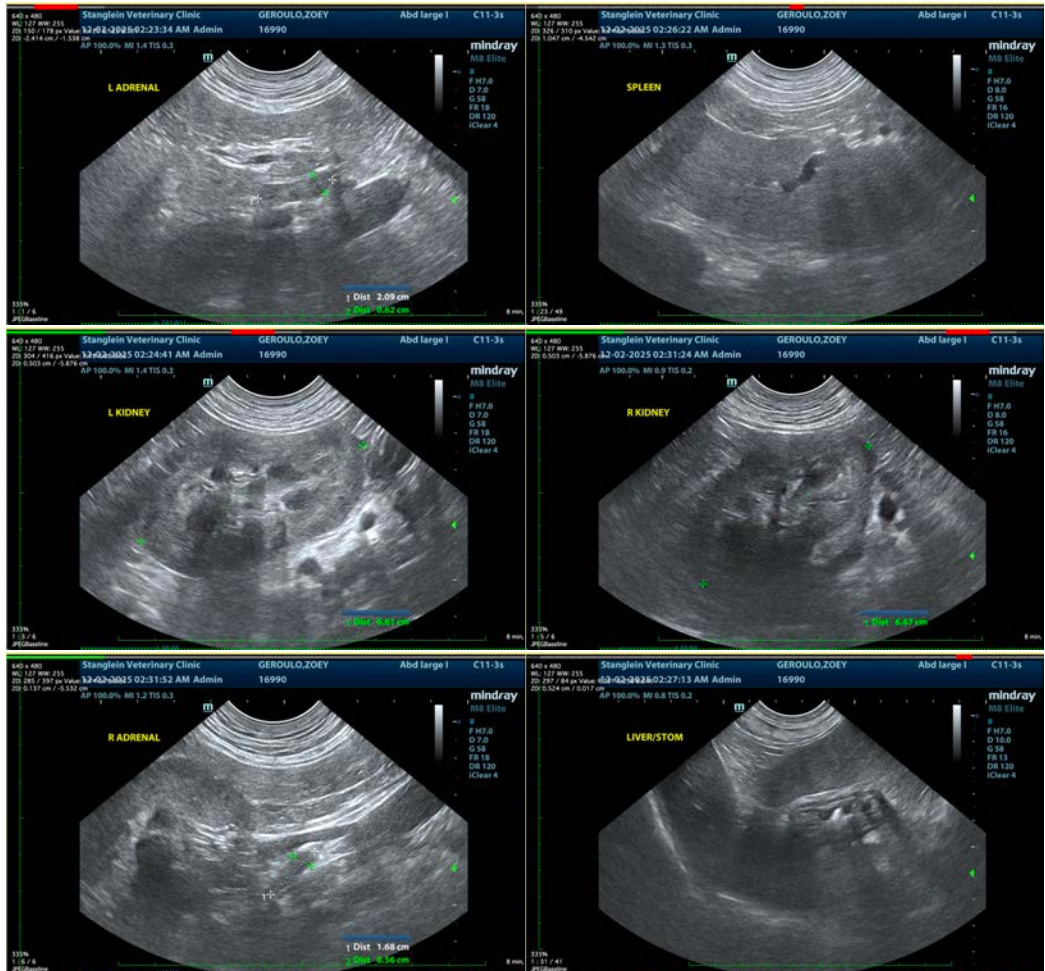
Dr. Katrina Lobst

**INVOICE**

72256

**DATE**

12/2/25



The information and recommendations provided are based on the images presented by the referring veterinarian/sonographer. No evaluation can be communicated regarding pathology that was not visible in the image/video clips provided.

Thank you for this referral. If the clinical or image interpretation does not parallel your findings or if I can be of any further assistance please contact me.

**Beth Johnson, DVM, DACVIM**  
info@sonopath.com