

**DATE PRESENTING CLINICAL SIGNS**

12/2/22

Pt presented for frequent urination and V+- o reports pt V+ 3xs on sun, first time ~1-2hrs after eating- was mostly food, then 2 more times with less food. V+ 2xs on Mon, no V+ today. O reports no diet change but says pt could have eaten something in yard. Freq urination started yesterday, pt squatted to urinated 4-5xs on walk. O reports no increased water drinking o says frequency of urination is dramatically less than when this first started, but still not quite normal. (~30 + urinations to now ~4)

PATIENT

Zelda Saxon

SPECIES

Canine

Current Medications: None listed.
 Lab Results: See attached.
 Date of Previous IntraPet Ultrasound: No previous.
 Sedation: IM sedation.
 Stat Report: Not requested.

BREED

Labrador

ULTRASONOGRAPHIC EXAMINATION OF THE ABDOMEN**SEX**

Spayed Female

Urinary System

The urinary bladder is moderately distended with anechoic contents. No masses, inflammatory changes, echogenic sediment or cystoliths are observed. The urinary bladder, trigone and visible pelvic urethra are normal in thickness with a smooth mucosal surface.

AGE

6/8/19

The right kidney is normal in size (5.87 cm), shape and echogenicity. It has smooth peripheral margination. There is a normal 1:3 cortex to medulla ratio with appropriate corticomedullary distinction. There is no evidence of pyelectasia, mineral or infarcts observed. A cortical cyst is noted in the cranial pole measuring 0.70 cm in diameter.

WEIGHT

50.5 Pounds

The left kidney is normal in size (5.63 cm), shape and echogenicity. It has smooth peripheral margination. There is a normal 1:3 cortex to medulla ratio with appropriate corticomedullary distinction. There is no evidence of pyelectasia, mineral or infarcts observed.

INTERPRETED BYBeth Johnson, DVM
DACVIM**Adrenal Glands**

The right adrenal gland is normal in size (2.1 cm long x 0.70 cm at the cranial pole and 0.72 cm at the caudal pole), shape and contour. Corticomedullary structure is unremarkable. Visible surrounding vasculature appears normal.

IMAGING PERFORMED BY

Rachel Brillhart RDMS

The left adrenal gland is normal in size (2.33 cm long x 0.65 cm at the cranial pole and 0.76 cm at the caudal pole), shape and contour. Corticomedullary structure is unremarkable. Visible surrounding vasculature appears normal.

HOSPITAL NAME

Fountain Green VC

Spleen

The spleen is subjectively normal in size with a normal smooth capsular contour. Parenchyma is appropriately finely textured and homogenous with normal echogenicity relative to surrounding tissue (hyperechoic to liver). No focal nodules or masses are observed. Splenic vasculature appears normal.

REFERRING VET

Dr. Lerner

Liver

The liver is subjectively normal in size with normal smooth curvilinear peripheral contour. Parenchyma is appropriately hypoechoic to the spleen in echogenicity and appropriately mildly coarse and homogenous in echotexture. No focal lesions are observed. Visible vasculature and biliary tree appear normal without distension or congestion.

INVOICE

43158

Gallbladder is moderately distended with anechoic bile as well as suspended and gravity dependent echogenic debris. The wall is smooth without visible thickening. There is no evidence of cystic or CBD dilation. There is no evidence of effusion or inflammation.

Gastrointestinal

The stomach wall is normal in thickness (canine < 0.5 cm and feline < 0.4 cm) and layering. The lumen of the stomach is empty with no evidence of obstruction, foreign material or infiltrative disease. Pyloric outflow tract appears patent.

The visible small intestines are normal in wall thickness and layering (canine duodenum < 0.5 cm and feline duodenum < 0.4 cm; other < 0.3 cm). Small intestinal motility appears adequate (1-3 contractions per min). The lumen of the small intestine is empty with no evidence of obstruction, foreign material or infiltrative disease.

The visible colon is normal in wall thickness (< 0.2 cm) and layering. Contents are consistent with normal formed feces and gas.

Pancreas

The pancreatic parenchyma is appropriately isoechoic to surrounding tissue. Visible capsule is smooth and normal in contour. There is no visible pancreatic duct dilation. There is no evidence of active peripancreatic inflammation.

Free Abdomen

There is no evidence of free peritoneal effusion noted in these images.

There is no apparent lymphadenopathy noted in these images.

ULTRASONOGRAPHIC FINDINGS

- **Gallbladder debris** - Cholecystic debris is of unknown clinical significance. It can be seen with biliary stasis from fasting or illness. Cholecystic debris is not necessarily related to hepatobiliary disease. Echogenic bile is most commonly an incidental finding in dogs and should be interpreted in combination with clinical signs such as nausea, inappetence, cranial abdominal discomfort and/or laboratory changes such as increased ALP and/or increased Tbili.
- Incidental right renal cortical cyst

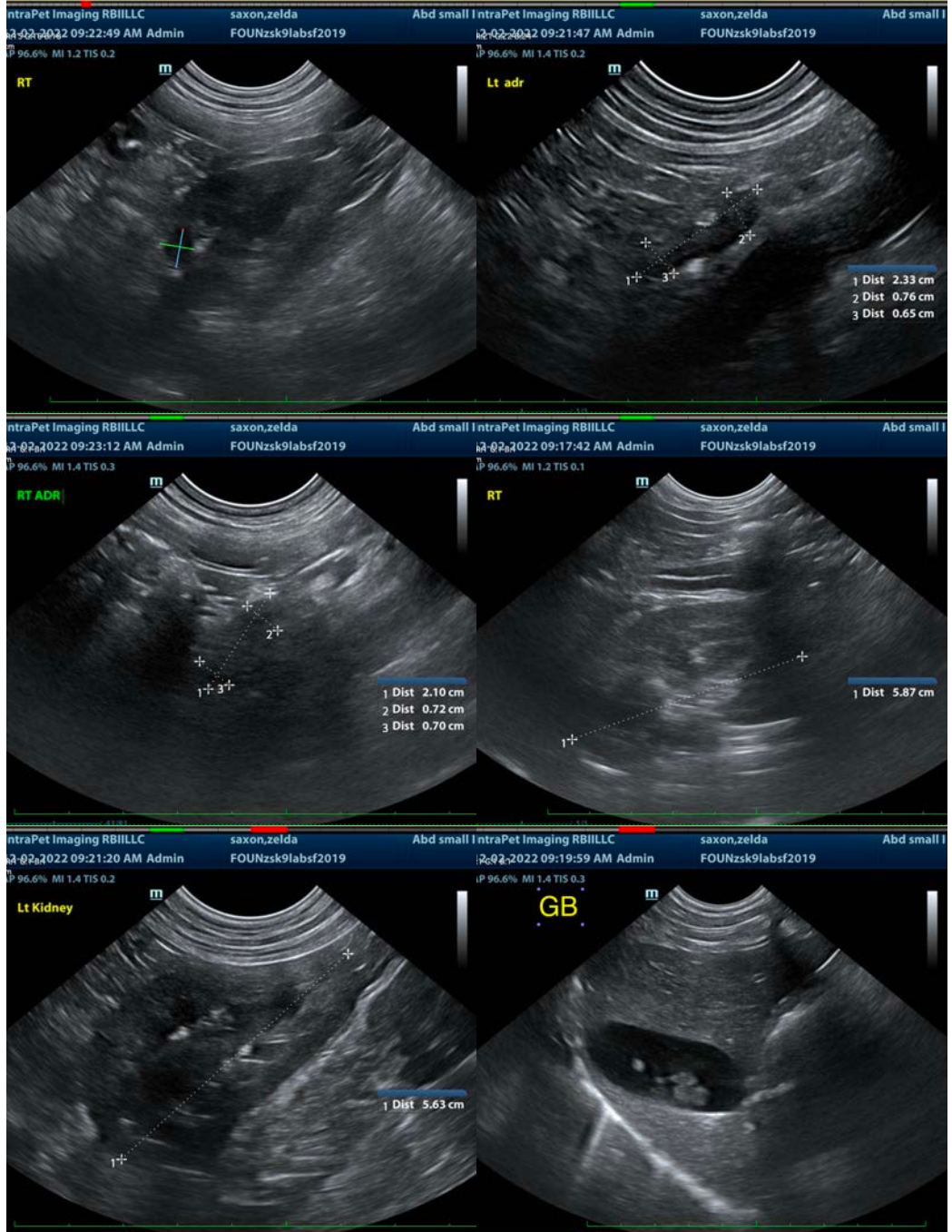
INTERPRETATION OF THE FINDINGS & FURTHER RECOMMENDATIONS

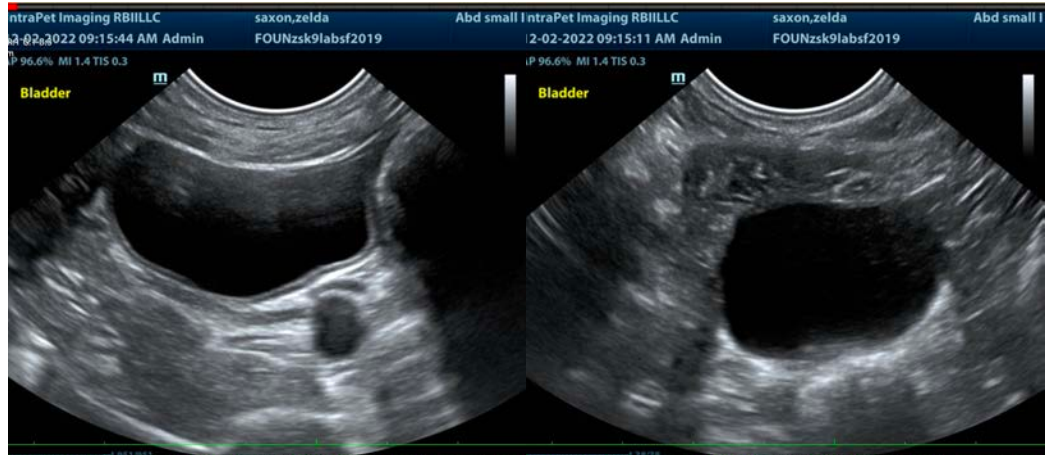
There is no ultrasonographically visible obvious cause in these images to explain the patient's recent vomiting or hematuria.

If not recently evaluated, an overall general metabolic health screen in the form of a CBC/Chem panel and electrolytes is recommended, as well as a coagulation panel to rule out coagulopathy as a cause of the patient's recent hematuria.

Parasites can affect the GI tract and the urinary tract. Therefore, empirical deworming with a 5-day course of Panacur is recommended.

Additionally, given the reported improvement/resolution of clinical signs, further follow up may not be warranted unless clinical signs persist and/or return.





The information and recommendations provided are based on the images presented by the referring veterinarian/sonographer. No evaluation can be communicated regarding pathology that was not visible in the image/video clips provided.

Thank you for this referral. If the clinical or image interpretation does not parallel your findings or if I can be of any further assistance please contact me.

Beth Johnson, DVM, DACVIM
Beth.Johnson@sonopath.com