

**DATE PRESENTING CLINICAL SIGNS**

12/19/22 Pt presents for neck pain and trembling. Bloodwork shows azotemia, hyperphosphatemia, hyperkalemia

PATIENT

Chloe Bratcher

Current Medications: Methocarbamol 250 BID, Gabapentin
 Lab Results: Creat 4.2, BUN 48, P 8.2, K 6.3, Na/K 23, ALP 144, USG 1.039, no bacteria.
 Date of Previous IntraPet Ultrasound: No previous.
 Sedation: Not required to complete full diagnostic ultrasound.
 Stat Report: Not requested.
 Imaging Performed By: Stephanie Warga RDCS, RVT.

SPECIES

Canine

BREED

Dachshund

SEX

Spayed Female

AGE

11/15/2011

WEIGHT

30.1 Pounds

ULTRASONOGRAPHIC EXAMINATION OF THE ABDOMEN**Urinary System**

Urinary bladder is adequately distended with anechoic contents. No masses, inflammatory changes, echogenic sediment or cystoliths are observed. The urinary bladder, trigone and visible pelvic urethra are normal in thickness with a smooth mucosal surface.

Kidneys are overall normal in size and shape with smooth peripheral margination. A normal 1:3 cortex to medulla ratio is maintained. The medulla and cortices are uniform in texture with some mild increased cortical echogenicity and mild loss of corticomedullary distinction, expected in this age patient. There is no evidence of pyelectasia, mineral or infarcts observed. The left kidney measures 5.79 cm. The right kidney measures 5.3 cm.

Left kidney is normal is size (5.79 cm), shape and echogenicity. It has smooth peripheral margination. There is a normal 1:3 cortex to medulla ratio with appropriate corticomedullary distinction. There is no evidence of pyelectasia, mineral or infarcts observed.

INTERPRETED BY

Beth Johnson, DVM
 DACVIM

Right kidney is normal is size (5.3 cm), shape and echogenicity. It has smooth peripheral margination. There is a normal 1:3 cortex to medulla ratio with appropriate corticomedullary distinction. There is no evidence of pyelectasia, mineral or infarcts observed.

HOSPITAL NAME

Everhart WellPet

Adrenal Glands

Left adrenal gland is normal in size (2.76 cm long x 0.85 cm at cranial pole and 0.77 cm at caudal pole), shape and overall architecture, echogenicity and echotexture. Visible surrounding vasculature appears normal.

REFERRING VET

Dr. Rubenstein

Right adrenal gland is normal in size (2.59 cm long x 0.82 cm at cranial pole and 0.67 cm at caudal pole), shape and overall architecture, echogenicity and echotexture. Visible surrounding vasculature appears normal.

INVOICE

20205

Spleen

Spleen is subjectively normal in size with a normal smooth capsular contour. Parenchyma is appropriately finely textured and homogenous with normal echogenicity relative to surrounding tissue (hyperechoic to liver). No focal nodules or masses are observed. Splenic vasculature appears normal.

Liver

Liver is subjectively normal in size with normal smooth curvilinear peripheral contour. Parenchyma is appropriately hypoechoic to the spleen in echogenicity and appropriately mildly coarse and homogenous in echotexture. No focal lesions are observed. Visible vasculature and biliary tree appear normal without distension or congestion.

Gallbladder is non-distended in size. The wall is smooth without visible thickening. Luminal contents are primarily anechoic. There is no evidence of cystic or common bile duct dilation.

Gastrointestinal

The visible stomach wall is normal in thickness and layering. The lumen of the stomach is empty with no evidence of obstruction, foreign material or infiltrative disease. Pyloric outflow tract appears patent.

The visible small intestines are normal in wall thickness and layering. Small intestinal motility appears adequate (1-3 contractions per min). The lumen of the small intestine is empty with no evidence of obstruction, foreign material or infiltrative disease.

The visible colon is normal in wall thickness and layering. Contents are consistent with normal formed feces and gas.

Pancreas

In the area of the pancreas, the tissue is markedly enhanced, characterized by hyperechoic mesenteric fat.

Free Abdomen

There is no evidence of peritoneal effusion. There is no apparent lymphadenopathy.

ULTRASONOGRAPHIC FINDINGS

Primary Findings

- Enhanced/hyperechoic mesenteric fat in the area of the pancreas, suggestive of inflammation in the area consistent with likely acute pancreatitis

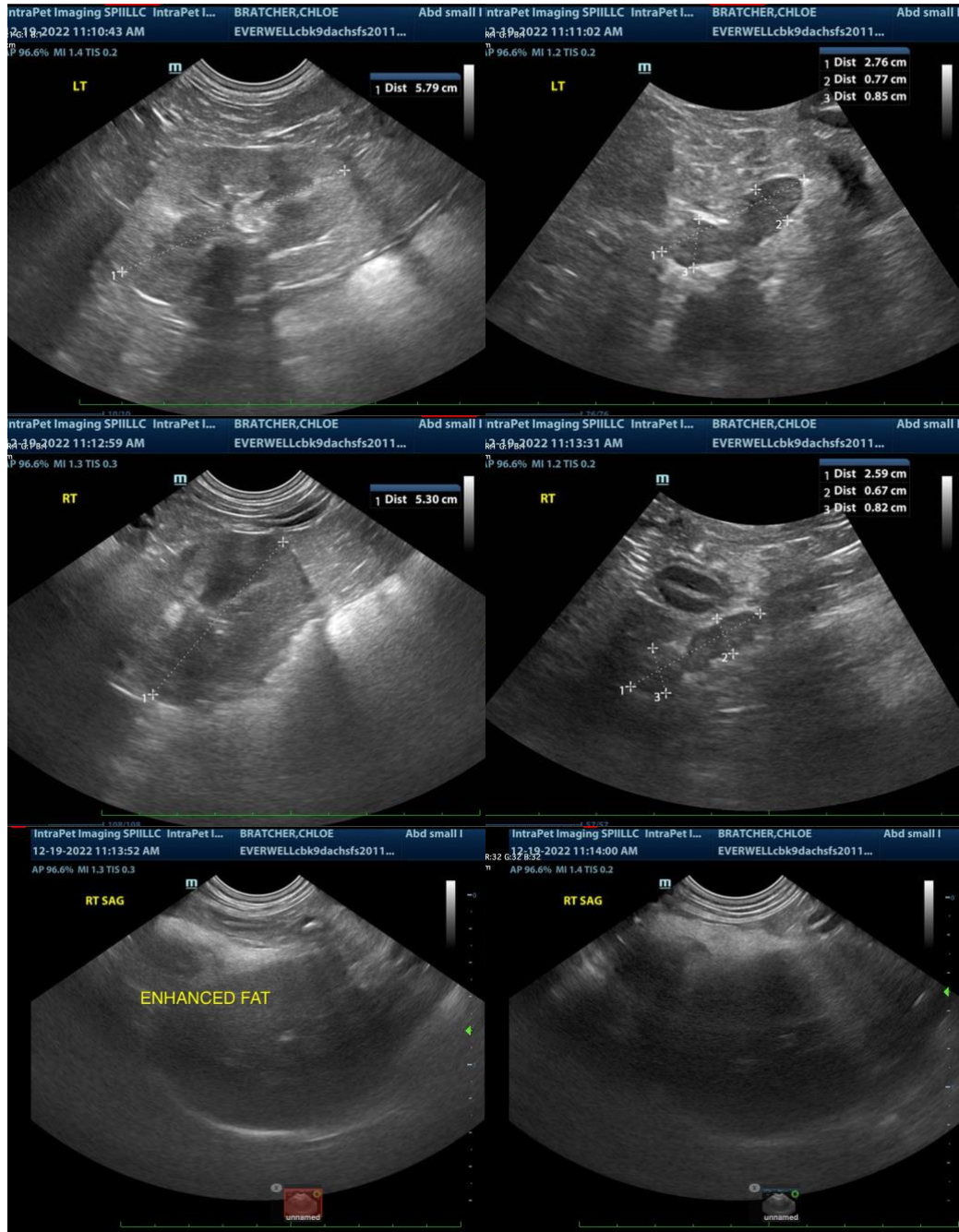
Secondary Findings

- Age-related kidney changes

INTERPRETATION OF THE FINDINGS & FURTHER RECOMMENDATIONS

Given this patient's concentrated urine, the reported azotemia could be prerenal, potentially brought on by decreased water intake secondary to pancreatitis. Recommendations include:

- A quantitative PLI for further assessment of the pancreas.
- Given the hyperkalemia, etc., a baseline cortisol is recommended. If baseline cortisol is less than 2, a full ACTH stimulation test is recommended to rule out hypoadrenocorticism.
- In the meantime, in addition to medical management of the suspected disk disease, pain, etc., fluid therapy/rehydration is recommended with recheck lab work to assess azotemia resolution versus progression, etc. If azotemia persists, and kidney disease is believed to be present, testing for leptospirosis is recommended.



The information and recommendations provided are based on the images presented by the referring veterinarian. No evaluation can be communicated regarding pathology that was not visible in the image/video clips provided.

Thank you for this referral. If the clinical or image interpretation does not parallel your findings or if I can be of any further assistance please contact me.

Beth Johnson, DVM DACVIM
Beth.Johnson@SonoPath.com