

PATIENT

Juju Joyner

SPECIES

Feline

BREED

DMH

SEX

FS

AGE

12 years

WEIGHT

11 lbs

INTERPRETED BY

Beth Johnson, DVM
DACVIM

IMAGING PERFORMED BY

Pamela Harrigan,
RDCS, Certified
Veterinary
Sonographer

HOSPITAL NAME

All Friends Animal
Hospital

REFERRING VET

Dr. Shoshana Gittens

INVOICE

10975

DATE

12/17/2025

PRESENTING CLINICAL SIGNS

Chronic intermittent vomiting. HCT 54.1, Glucose 209, potas 3.4. Hemoconcentration, hypokalemia, hyperglycemia.

ULTRASONOGRAPHIC EXAMINATION OF THE ABDOMEN

Urinary System

The urinary bladder is adequately distended with anechoic contents. No masses, inflammatory changes, echogenic sediment or cystoliths are observed. The urinary bladder, trigone and visible pelvic urethra are normal in thickness with a smooth mucosal surface.

The right kidney is normal in size (3.17 cm), shape and echogenicity. It has smooth peripheral margination. There is a normal 1:3 cortex to medulla ratio with appropriate corticomedullary distinction. There is no evidence of pyelectasia, mineral or infarcts observed.

The left kidney is normal in size (3.76 cm), shape and echogenicity. It has smooth peripheral margination. There is a normal 1:3 cortex to medulla ratio with appropriate corticomedullary distinction. There is no evidence of pyelectasia, mineral or infarcts observed.

Adrenal Glands

The right adrenal gland is normal in size (0.46 cm at cranial pole and 0.38 cm at caudal pole), shape and overall architecture, echogenicity and echotexture. Visible surrounding vasculature appears normal.

The left adrenal gland is normal in size (0.42 cm at cranial pole and 0.36 cm at caudal pole), shape and overall architecture, echogenicity and echotexture. Visible surrounding vasculature appears normal.

Spleen

The spleen is subjectively normal in size with a normal smooth capsular contour. Parenchyma is appropriately finely textured and homogenous with normal echogenicity relative to surrounding tissue (hyperechoic to liver). No focal nodules or masses are observed. Splenic vasculature appears normal.

Liver

The liver is subjectively normal in size with normal smooth curvilinear peripheral contour. Parenchyma is appropriately hypoechoic to the spleen in echogenicity and appropriately mildly coarse and homogenous in echotexture. No focal lesions are observed. Visible vasculature and biliary tree appear normal without distension or congestion. There appear to be some very subtle, likely incidental, multifocal intrahepatic biliary mineral densities.

The gallbladder is non-distended in size. The wall is smooth without visible thickening. Luminal contents are primarily anechoic. There is no evidence of cystic or common bile duct dilation.

Gastrointestinal

The visible stomach wall is normal in thickness and layering. The lumen of the stomach is empty with no evidence of obstruction, foreign material or infiltrative disease. Pyloric outflow tract appears patent.

The visible small intestine demonstrates areas of very prominently thick muscularis layer relative to mucosa (disruption of the normal 1:3 muscularis:mucosa ratio). Small intestinal submucosa is slightly



PATIENT

Juju Joyner

SPECIES

Feline

BREED

DMH

SEX

FS

AGE

12 years

WEIGHT

11 lbs

INTERPRETED BY

Beth Johnson, DVM
DACVIM

IMAGING PERFORMED BY

Pamela Harrigan,
RDCS, Certified
Veterinary
Sonographer

HOSPITAL NAME

All Friends Animal
Hospital

REFERRING VET

Dr. Shoshana Gittens

INVOICE

10975

DATE

12/17/2025

irregular, thick and hyperechoic, without evident loss of layering appreciated. The lumen of the small intestine is empty with no evidence of obstruction or foreign material.

The visible colon is normal in wall thickness (< 0.2 cm) and layering. Contents are consistent with normal formed feces and gas.

Pancreas

The area of the pancreas contains irregular hyperechoic pancreatic remodeling.

Free Abdomen

There is no visible free peritoneal effusion noted in these images.

There is no apparent pathologic lymphadenopathy noted in these images.

PRIMARY FINDINGS

- Marked/significant inflammatory bowel disease (IBD) pattern – Thick muscularis has been reported with infiltrative bowel disease including both benign inflammatory disease as well as infiltrative neoplasia such as lymphoma. No loss of layering or distinct characteristics of malignancy are present. Therefore, differentials cannot be further ranked without tissue sampling.
- Hyperechoic pancreas – This finding is suggestive of pancreatic fibrosis, possibly secondary to chronic pancreatitis. A TLI is recommended to rule out exocrine pancreatic insufficiency (EPI), especially if clinical signs (weight loss, diarrhea, etc.) are present.

SECONDARY FINDINGS

- Suspect, incidental, subtle multifocal intrahepatic biliary mineral densities.

INTERPRETATION OF THE FINDINGS & FURTHER RECOMMENDATIONS

Further investigation of patient's reported hyperglycemia may be warranted to help differentiate stress hyperglycemia versus emerging diabetes. Therefore, urinalysis and, if indicated based on urinalysis results, urine culture is recommended. If protein is present in an otherwise quiet sediment, protein quantification with a urine protein to creatinine ration is recommended.

A fructosamine level could be considered.

A T4 +/- Free T4 is recommended if not recently evaluated.

A gastrointestinal malabsorption panel (including cobalamin, folate, TLI and PLI) to Texas A&M GI Laboratory is recommended for further evaluation of GI and pancreatic function.

Ideally, biopsies of the GI tract, being sure to include ileum if possible, are recommended to definitively diagnose and therefore manage the infiltrative bowel disease.

If biopsies cannot be obtained, empirical therapies could include a probiotic (if diarrhea is present, such as visbiome or proviable), empirical deworming with a 5-day course of Panacur and, if tolerated, a transition in diet, based on trial-and-error response, beginning with a hydrolyzed protein diet. Some patients respond to one brand/version of a hydrolyzed protein diet better than another brand, so several trials may be required.



PATIENT

Juju Joyner

Additional considerations could include cobalamin supplementation (unless cobalamin level is evaluated and supplementation is not warranted) and prednisolone (if not contraindicated based on patient contraindications, co-morbidities, etc.).

SPECIES

Feline

BREED

DMH

SEX

FS

AGE

12 years

WEIGHT

11 lbs

INTERPRETED BY

Beth Johnson, DVM
DACVIM

IMAGING PERFORMED BY

Pamela Harrigan,
RDCS, Certified
Veterinary
Sonographer

HOSPITAL NAME

All Friends Animal
Hospital

REFERRING VET

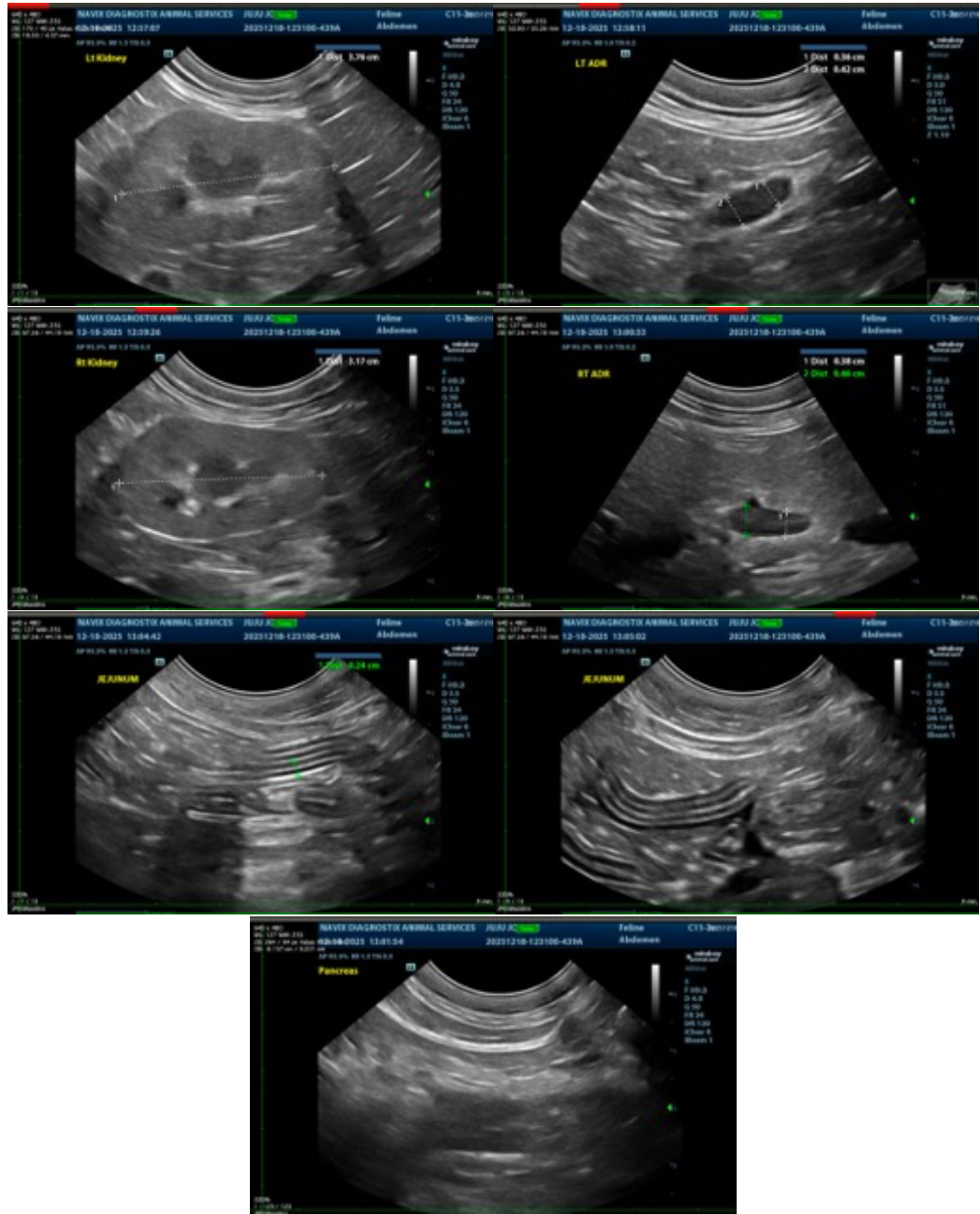
Dr. Shoshana Gittens

INVOICE

10975

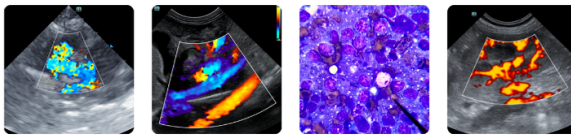
DATE

12/17/2025



The information and recommendations provided are based on the images presented by the referring veterinarian/sonographer. No evaluation can be communicated regarding pathology that was not visible in the image/video clips provided.

Thank you for this referral. If the clinical or image interpretation does not parallel your findings or if I



PATIENT

Juju Joyner

SPECIES

Feline

BREED

DMH

SEX

FS

AGE

12 years

WEIGHT

11 lbs

INTERPRETED BY

Beth Johnson, DVM
DACVIM

**IMAGING
PERFORMED BY**

Pamela Harrigan,
RDCS, Certified
Veterinary
Sonographer

HOSPITAL NAME

All Friends Animal
Hospital

REFERRING VET

Dr. Shoshana Gittens

INVOICE

10975

DATE

12/17/2025

can be of any further assistance please contact me.

Beth Johnson, DVM, DACVIM
info@sonopath.com