



PATIENT

Finn Allen

PRESENTING CLINICAL SIGNS

Recheck abnormal left liver lobe and gallbladder. Overweight, thin coat on flanks. HX of IBD- controlled. Meds: Ursodiol, Budesonide, Fluoxetine

SPECIES

Canine

Abnormal PE/Chem/CBC/UA Results: AlkP 243, Cholesterol 446.

ULTRASONOGRAPHIC EXAMINATION OF THE ABDOMEN

BREED

Beagle

Urinary System

The urinary bladder is adequately distended with anechoic contents. No masses, inflammatory changes, echogenic sediment or cystoliths are observed. The urinary bladder, trigone and visible pelvic urethra are normal in thickness with a smooth mucosal surface.

SEX

Neutered Male

Prostate is normal in size, echotexture and echogenicity for a neutered male.

AGE

6 Years 2 Months

The right kidney is normal is size (6.16 cm), shape and echogenicity. It has smooth peripheral margination. There is a normal 1:3 cortex to medulla ratio with appropriate corticomedullary distinction. There is no evidence of pyelectasia, mineral or infarcts observed.

WEIGHT

32.9 lbs

The left kidney is normal is size (6.14 cm), shape and echogenicity. It has smooth peripheral margination. There is a normal 1:3 cortex to medulla ratio with appropriate corticomedullary distinction. There is no evidence of pyelectasia, mineral or infarcts observed.

INTERPRETED BY

Beth Johnson, DVM
DACVIM

Adrenal Glands

The right adrenal gland is normal in size (0.78 cm at cranial pole and 0.30 cm at caudal pole), shape and overall architecture, echogenicity and echotexture. Visible surrounding vasculature appears normal.

The left adrenal gland is normal in size (0.26 cm at cranial pole and 0.34 cm at caudal pole), shape and overall architecture, echogenicity and echotexture. Visible surrounding vasculature appears normal.

IMAGING PERFORMED BY

Rebecca Hamilton

Spleen

The spleen is subjectively normal in size (1.9 cm thick at the hilus) with a normal smooth capsular contour. Parenchyma is appropriately finely textured and homogenous with normal echogenicity relative to surrounding tissue (hyperechoic to liver). No focal nodules or masses are observed. Splenic vasculature appears normal.

HOSPITAL NAME

Black River Veterinary
Hospital

Liver

Liver is subjectively enlarged with mildly irregular margins. Parenchyma is mildly heterogenous characterized by multiple poorly defined hypoechoic nodules within otherwise hyperechoic liver parenchyma. Additionally, in the mid liver just caudal to the gallbladder is an approximately 1.1 cm x 0.80 cm discrete, homogeneous, hyperechoic nodule. Visible vasculature and biliary tree appear normal without distension or congestion

REFERRING VET

Dr. Hewitt

INVOICE

72650

DATE

12/17/25

Gallbladder is moderately distended with anechoic bile as well as suspended and gravity dependent echogenic debris. The wall is smooth without visible thickening. There is no evidence of cystic or CBD dilation. There is no evidence of effusion or inflammation.



PATIENT

Finn Allen

SPECIES

Canine

BREED

Beagle

SEX

Neutered Male

AGE

6 Years 2 Months

WEIGHT

32.9 lbs

INTERPRETED BY

Beth Johnson, DVM
DACVIM

IMAGING PERFORMED BY

Rebecca Hamilton

HOSPITAL NAME

Black River Veterinary
Hospital

REFERRING VET

Dr. Hewitt

INVOICE

72650

DATE

12/17/25

Gastrointestinal

The visible stomach wall is normal in thickness and layering. The lumen of the stomach is empty with no evidence of obstruction, foreign material or infiltrative disease. Pyloric outflow tract appears patent.

The visible small intestines are normal in wall thickness and layering. Small intestinal motility appears adequate (1-3 contractions per min). The lumen of the small intestine is empty with no evidence of obstruction, foreign material or infiltrative disease.

The visible colon is normal in wall thickness (< 0.2 cm) and layering. Contents are consistent with normal formed feces and gas.

Pancreas

The area of the pancreas contains irregular hyperechoic pancreatic remodeling.

Free Abdomen

There is no visible free peritoneal effusion noted in these images.

There is no apparent pathologic lymphadenopathy noted in these images.

ULTRASONOGRAPHIC FINDINGS

- Diffusely mildly heterogenous liver – These changes are most consistent with benign processes such as nodular hyperplasia, steroid (vacuolar) hepatopathy, extramedullary hematopoiesis or possibly chronic inflammatory disease and less commonly infiltrative round cell or metastatic neoplasia.
- Focal hyperechoic liver nodule – Differentials for a discrete hyperechoic liver nodule include primarily benign changes such as nodular hyperplasia, fibrosis of an old hematoma, granuloma, myelolipomas, etc.; however, while considered less likely, primary hepatic neoplasia, infiltrative round cell neoplasia and metastatic disease can mimic benign lesions and cannot be definitively ruled out.
- Moderate gallbladder debris - Cholecystic debris is of unknown clinical significance. It can be seen with biliary stasis from fasting or illness. Cholecystic debris is not necessarily related to hepatobiliary disease. Echogenic bile is most commonly an incidental finding in dogs and should be interpreted in combination with clinical signs such as nausea, inappetence, cranial abdominal discomfort and/or laboratory changes such as increased ALP and/or increased Tbili.
- Hyperechoic pancreas – This finding is suggestive of pancreatic fibrosis, possibly secondary to chronic pancreatitis. A TLI is recommended to rule out exocrine pancreatic insufficiency (EPI), especially if clinical signs (weight loss, diarrhea, etc.) are present.

INTERPRETATION OF THE FINDINGS & FURTHER RECOMMENDATIONS

Subjectively, the appearance of the liver trends toward benign and is relatively static to the previous exam. Subjectively, the appearance of the gallbladder disease is static to slightly improved. Pancreatic changes should be interpreted in combination with any clinical history, but further diagnostic considerations could include:



PATIENT

Finn Allen

SPECIES

Canine

BREED

Beagle

SEX

Neutered Male

AGE

6 Years 2 Months

WEIGHT

32.9 lbs

INTERPRETED BY

Beth Johnson, DVM
 DACVIM

IMAGING PERFORMED BY

Rebecca Hamilton

HOSPITAL NAME

Black River Veterinary
 Hospital

REFERRING VET

Dr. Hewitt

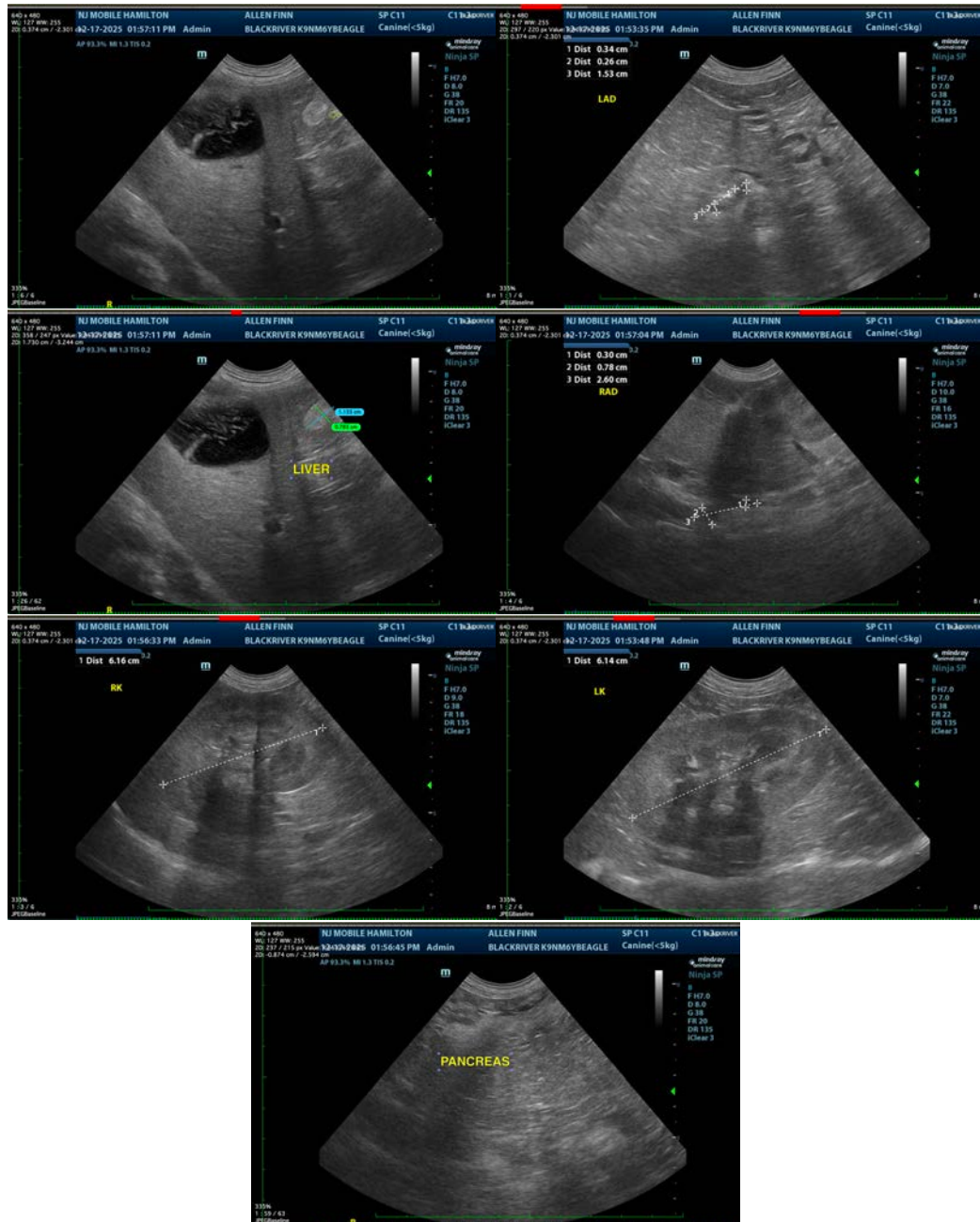
INVOICE

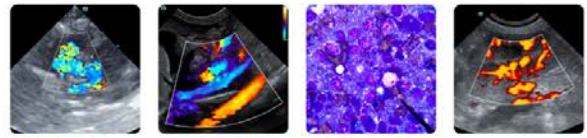
72650

DATE

12/17/25

A gastrointestinal malabsorption panel (including cobalamin, folate, TLI and PLI) to Texas A&M GI Laboratory is recommended for further evaluation of GI and pancreatic function.





PATIENT

Finn Allen

The information and recommendations provided are based on the images presented by the referring veterinarian/sonographer. No evaluation can be communicated regarding pathology that was not visible in the image/video clips provided.

SPECIES

Canine

Thank you for this referral. If the clinical or image interpretation does not parallel your findings or if I can be of any further assistance please contact me.

BREED

Beagle

Beth Johnson, DVM, DACVIM
info@sonopath.com

SEX

Neutered Male

AGE

6 Years 2 Months

WEIGHT

32.9 lbs

INTERPRETED BY

Beth Johnson, DVM
DACVIM

IMAGING PERFORMED BY

Rebecca Hamilton

HOSPITAL NAME

Black River Veterinary
Hospital

REFERRING VET

Dr. Hewitt

INVOICE

72650

DATE

12/17/25