



PATIENT

Maggie Ruth

SPECIES

Feline

BREED

DSH

SEX

Spayed Female

AGE

10.11 years

WEIGHT

7.5 lbs

INTERPRETED BY

Beth Johnson, DVM
DACVIM

IMAGING PERFORMED BY

Dr. Kristen Carpenter

HOSPITAL NAME

Pennridge Animal
Hospital

REFERRING VET

Dr. Diana Strenk

INVOICE

10941

DATE

12/16/2025

PRESENTING CLINICAL SIGNS

Patient was sedated with butorphanol. Clinical History & Reason for Referral: Chronic soft stool and inappropriate defecation for approx 3 yrs. Patient has had trial of I/D, metronidazole, prednisolone, tyran powder, Z/D, b12 inj w/ minimal improvement. Mild weight loss 8.3lbs on 4/3/24 and 7.5lbs 12/16/25. BCS 4/9. Current Medications: None. Current Diet: Recent transition to GI biome 12/11/2025. Previous Diagnostics or Scans: 12/11/25 -cbc/chem WNL -t4- 2.7 - fecal negative.

ULTRASONOGRAPHIC EXAMINATION OF THE ABDOMEN

Urinary System

Urinary bladder is adequately distended. It has a normal uniform wall thickness. Contents include primarily anechoic fluid with a large amount of echogenic non-shadowing debris, most consistent with exfoliated cells, crystals, mucous and/or small blood clots likely combined with incidental suspended lipid. Both sterile inflammation as well as urinary tract infection can present with echogenic debris. No masses or definitive cystoliths are observed. The trigone and visible pelvic urethra are normal in thickness with a smooth mucosal surface.

Kidneys are overall normal in size and shape with smooth peripheral margination. A normal 1:3 cortex to medulla ratio is maintained. The medulla and cortices are uniform in texture with some mild increased cortical echogenicity and mild loss of corticomedullary distinction, expected in this age patient. There is no evidence of pyelectasia or infarcts observed. Punctate non-obstructive nephroliths are noted bilaterally. Left kidney measures 3.14 cm, and the right kidney measures 3.5 cm.

Adrenal Glands

The right adrenal gland is normal in size (0.31 cm), shape and overall architecture, echogenicity and echotexture. Visible surrounding vasculature appears normal.

The left adrenal gland is normal in size (0.36 cm), shape and overall architecture, echogenicity and echotexture. Visible surrounding vasculature appears normal.

Spleen

The spleen is subjectively normal in size with a normal smooth capsular contour. Parenchyma is appropriately finely textured and homogenous with normal echogenicity relative to surrounding tissue (hyperechoic to liver). No focal nodules or masses are observed. Splenic vasculature appears normal.

Liver

The liver is subjectively normal in size with normal smooth curvilinear peripheral contour. Parenchyma is appropriately hypoechoic to the spleen in echogenicity and appropriately mildly coarse and homogenous in echotexture. No focal lesions are observed. Visible vasculature and biliary tree appear normal without distension or congestion.

The gallbladder is non-distended in size. The wall is smooth without visible thickening. Luminal contents are primarily anechoic. There is no evidence of cystic or common bile duct dilation.

Gastrointestinal



PATIENT

Maggie Ruth

The visible stomach wall is normal in thickness and layering. The lumen of the stomach is empty with no evidence of obstruction, foreign material or infiltrative disease. Pyloric outflow tract appears patent.

SPECIES

Feline

The visible small intestine demonstrates areas of moderately thick muscularis layer relative to mucosa (disruption of the normal 1:3 muscularis:mucosa ratio). Small intestinal submucosa is slightly irregular, thick and hyperechoic, without evident loss of layering appreciated. The lumen of the small intestine is empty with no evidence of obstruction or foreign material.

BREED

DSH

The visible colon is diffusely thick, measuring 0.31 cm thick with normal intact layering. The lumen is empty, and in some places mildly distended with soft stool.

SEX

Spayed Female

Pancreas

Pancreas is prominent (enlarged) in size, hypoechoic to surrounding tissue and has a mildly irregular undulating contour. Parenchyma is coarse with mixed echogenic remodeling noted. No pancreatic duct dilation is noted.

AGE

10.11 years

Free Abdomen

There is no visible free peritoneal effusion noted in these images.

WEIGHT

7.5 lbs

Colic lymph nodes are prominent in size with swollen capsular contour. Normal elongated shape (length to width ratio) is maintained. There is no loss of parenchymal detail.

INTERPRETED BY

Beth Johnson, DVM
DACVIM

PRIMARY FINDINGS

- The diffusely thick colon could demonstrate a benign inflammatory process i.e. parasitic, infectious, dietary related, other benign inflammatory or infiltrative neoplasia can't be ruled out without tissue sampling.
- Moderately reactive colic lymph nodes – infiltrative neoplastic disease cannot be ruled out but is considered less likely.
- Concurrent inflammatory bowel disease (IBD) pattern – Thick muscularis has been reported with infiltrative bowel disease including both benign inflammatory disease as well as infiltrative neoplasia such as lymphoma. No loss of layering or distinct characteristics of malignancy are present. Therefore, differentials cannot be further ranked without tissue sampling.
- Chronic low grade smoldering pancreatitis can't be ruled out and should be suspected in the face of appropriate clinical signs.

IMAGING PERFORMED BY

Dr. Kristen Carpenter

HOSPITAL NAME

Pennridge Animal
Hospital

REFERRING VET

Dr. Diana Strenk

INVOICE

10941

SECONDARY FINDINGS

- Age related kidney changes with punctate non-obstructive nephroliths bilaterally.

DATE

12/16/2025

INTERPRETATION OF THE FINDINGS & FURTHER RECOMMENDATIONS

A routine fecal/giardia exam is recommended if not recently evaluated.

A gastrointestinal malabsorption panel (including cobalamin, folate, TLI and PLI) to Texas A&M GI Laboratory is recommended for further evaluation of GI and pancreatic function.



PATIENT

Maggie Ruth

SPECIES

Feline

BREED

DSH

SEX

Spayed Female

AGE

10.11 years

WEIGHT

7.5 lbs

INTERPRETED BY

Beth Johnson, DVM
DACVIM

IMAGING PERFORMED BY

Dr. Kristen Carpenter

HOSPITAL NAME

Pennridge Animal
Hospital

REFERRING VET

Dr. Diana Strenk

INVOICE

10941

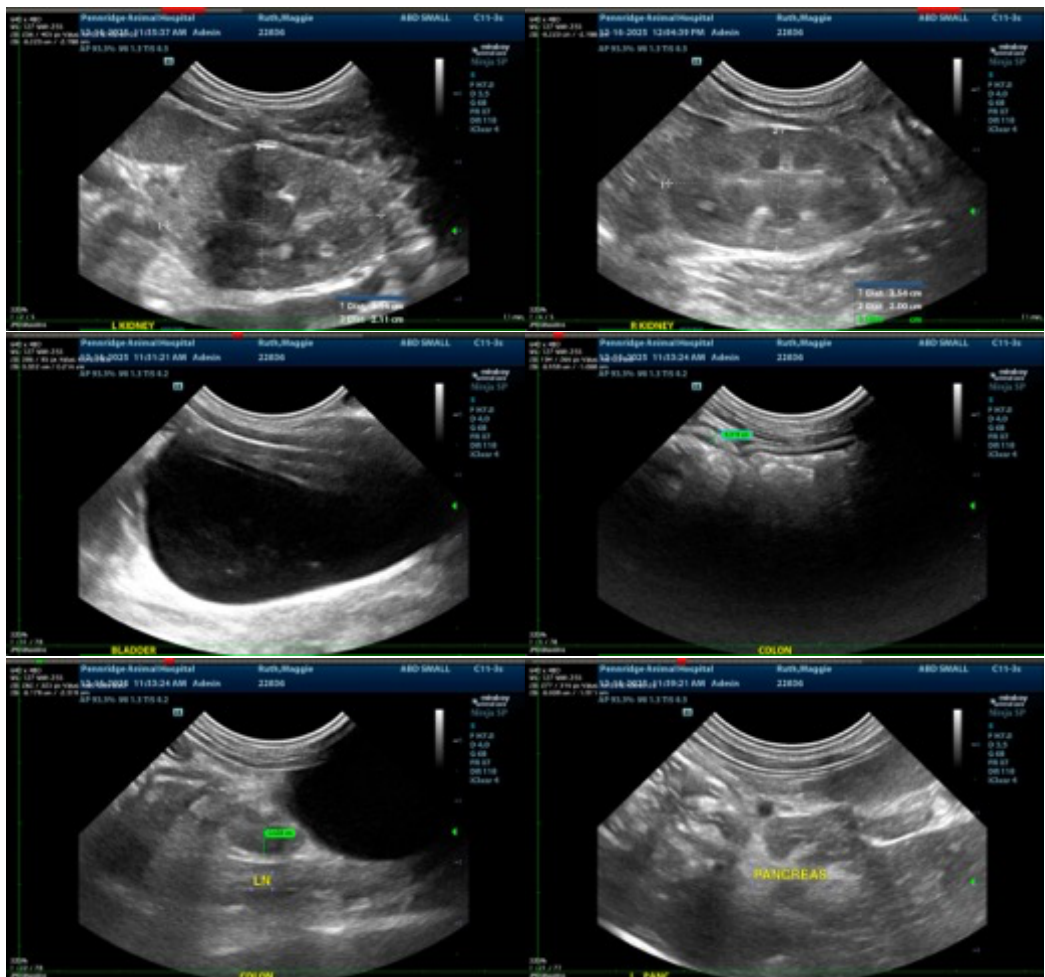
DATE

12/16/2025

A fecal enteropathogen PCR panel to Texas A&M GI Laboratory could be considered for further evaluation of possible infectious disease. Contact lab for recommendations on how long to discontinue antibiotics (if indicated) prior to obtaining a stool sample for submission.

If a diagnosis of parasitic or infectious disease is not made, however, ultimately, tissue sampling is recommended. Both upper and lower GI endoscopy/colonoscopy may be indicated for further evaluation and biopsies of the GI tract being sure to include ileum, if possible. If only partial evaluation and biopsies is elected, in my opinion, a high yield sampling location would be the colon versus small bowel.

In the meantime, supportive/symptomatic medical management of clinical signs is recommended, including a probiotic (such as visbiome or proviable), empirical deworming with a 5-day course of Panacur and, if tolerated, a transition in diet, based on trial-and-error response, beginning possibly with a gastrointestinal biome diet vs a hydrolyzed protein diet vs other. Some patients respond to one brand/version of a hydrolyzed protein diet better than another brand, so several brand attempts may be required. Additionally, given patient's chronic history, fecal microbe transplant therapy may be helpful.





PATIENT

Maggie Ruth

SPECIES

Feline

BREED

DSH

SEX

Spayed Female

AGE

10.11 years

WEIGHT

7.5 lbs

INTERPRETED BY

Beth Johnson, DVM
DACVIM

IMAGING PERFORMED BY

Dr. Kristen Carpenter

HOSPITAL NAME

Pennridge Animal
Hospital

REFERRING VET

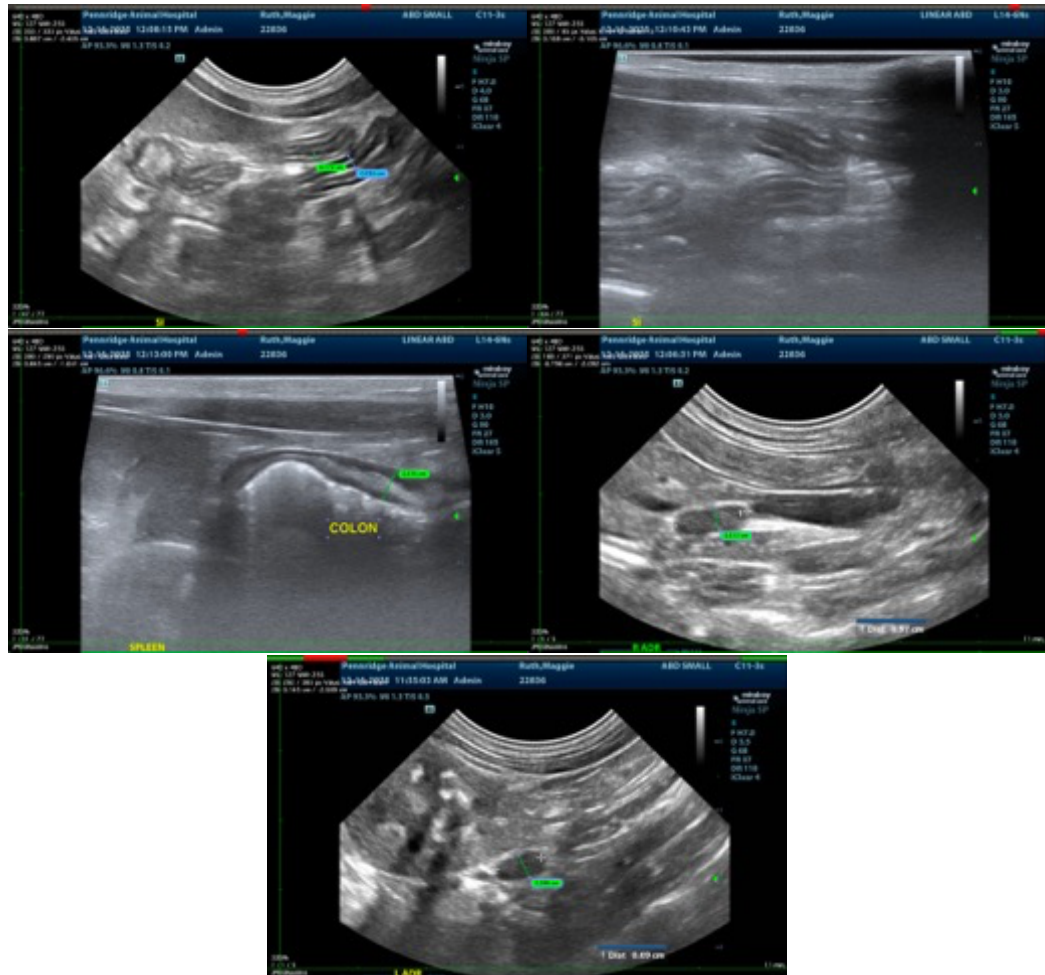
Dr. Diana Strenk

INVOICE

10941

DATE

12/16/2025



The information and recommendations provided are based on the images presented by the referring veterinarian/sonographer. No evaluation can be communicated regarding pathology that was not visible in the image/video clips provided.

Thank you for this referral. If the clinical or image interpretation does not parallel your findings or if I can be of any further assistance please contact me.

Beth Johnson, DVM, DACVIM
info@sonopath.com